

# Fondaparinux in Percutaneous Coronary Intervention for the Treatment of Acute Coronary Syndrome

Pedro Beraldo de Andrade<sup>1</sup>, Marden André Tebet<sup>2</sup>, Ederlon Ferreira Nogueira<sup>3</sup>,  
Mônica Vieira Athanazio de Andrade<sup>4</sup>, Robson Alves Barbosa<sup>5</sup>, André Labrunie<sup>6</sup>, Luiz Alberto Mattos<sup>7</sup>

## ABSTRACT

**Background:** Fondaparinux is an agent that has a well-established safety and efficacy profile in the treatment of non-ST segment elevation acute coronary syndromes. When used alone, however, it is associated with a higher incidence of thrombotic complications during invasive coronary procedures, requiring the supplementation of an anti-IIa agent. This study aimed to evaluate the efficacy and safety of percutaneous coronary intervention (PCI) in patients with non-ST segment elevation acute coronary syndromes that were previously treated with fondaparinux. **Methods:** This was a prospective, controlled registry, enrolling 127 consecutive patients submitted to an early invasive stratification during treatment with fondaparinux with the supplementation of intravenous unfractionated heparin at a dose of 85 U/kg at the time of PCI. **Results:** The composite primary endpoint rate, including death, acute myocardial infarction, stroke, stent thrombosis, or emergency myocardial revascularisation was 3.2%. The cumulative incidence of major bleeding and vascular complications was 3.2%. There were no cases of guide catheter thrombosis or abrupt vessel closure. **Conclusions:** PCI in patients with acute coronary syndromes receiving fondaparinux was associated with a low rate of major adverse cardiovascular ischaemic events and severe haemorrhagic complications. Supplementation with unfractionated heparin during the invasive procedures eliminated the risk of catheter-related thrombosis.

**DESCRIPTORS:** Acute coronary syndrome. Angioplasty. Stents. Anticoagulants. Fondaparinux.

## RESUMO

### Fondaparinux em Intervenção Coronária Percutânea no Tratamento da Síndrome Coronária Aguda

**Introdução:** Considerado um fármaco com adequado perfil de eficácia e segurança no tratamento da síndrome coronária aguda sem supradesnivelamento do segmento ST, o fonda parinux, utilizado de forma isolada, associase a maior ocorrência de complicações trombóticas durante a realização de procedimentos coronários invasivos, requerendo a adição de agente com atividade anti-IIa. Este estudo teve como objetivo avaliar a eficácia e a segurança da intervenção coronária percutânea (ICP) em pacientes admitidos com diagnóstico de síndrome coronária aguda sem supradesnivelamento do segmento ST, previamente tratados com fondaparinux. **Métodos:** Registro prospectivo, controlado, envolvendo 127 pacientes consecutivos submetidos a estratificação invasiva precoce na vigência de fondaparinux, com suplementação de heparina não fracionada intravenosa na dose de 85 U/kg no momento da ICP. **Resultados:** A taxa do desfecho primário, composto por morte, infarto agudo do miocárdio, acidente vascular encefálico, trombose de stent ou revascularização miocárdica de urgência, foi de 3,2%. A incidência acumulada de sangramento grave e complicações vasculares foi de 3,2%. Não houve casos de trombose do cateterguia ou oclusão abrupta do vaso. **Conclusões:** A ICP em pacientes com síndrome coronária aguda em uso de fondaparinux associase a baixas taxas de eventos cardiovasculares adversos isquêmicos e de complicações hemorrágicas graves. A suplementação com heparina não fracionada durante o procedimento invasivo elimina o risco de trombose do cateter.

**DESCRIPTORES:** Síndrome coronariana aguda. Angioplastia. Stents. Anticoagulantes. Fondaparinux.

<sup>1</sup> PhD student in Sciences at Universidade de São Paulo. Physician; Interventionist cardiologist at Santa Casa de Marília. Marília, SP, Brazil.

<sup>2</sup> Physician; Interventionist cardiologist at Santa Casa de Marília and Hospital do Coração de Londrina. Londrina, PR, Brazil.

<sup>3</sup> Physician; Interventionist cardiologist at Santa Casa de Marília and Hospital do Coração de Londrina. Londrina, PR, Brazil.

<sup>4</sup> Nurse; specialist in Cardiovascular Nursing. Nurse at Santa Casa de Marília. Marília, SP, Brazil.

<sup>5</sup> Nurse at Santa Casa de Marília. Marília, SP, Brazil.

<sup>6</sup> PhD in Sciences at Universidade Estadual Paulista. Physician; Interventionist cardiologist at Santa Casa de Marília and Hospital do Coração de Londrina. Londrina, PR, Brazil.

<sup>7</sup> PhD in Sciences at Universidade de São Paulo. Physician; Interventionist cardiologist at Santa Casa de Marília and Instituto Dante Pazzanese de Cardiologia. São Paulo, SP, Brazil.

**Correspondence to:** Pedro Beraldo de Andrade. Avenida Vicente Ferreira, 828 – Marília, SP, Brazil – CEP 17515900  
E-mail: pedroberaldo@gmail.com

Received on: 3/7/2012 • Accepted on: 5/14/2012

Antithrombotic drug therapy, which consists of antiplatelet agents and anticoagulants, together with early invasive risk stratification, constitutes an important mainstay in the care of high-risk patients with non-ST-segment elevation acute coronary syndrome (NSTEMACS).<sup>1</sup> Increased life expectancy and the prevalence of comorbidities, together with the large number of new drugs with different anti-ischemic action mechanisms, have made it essential for therapeutic decisions to strive for a delicate balance of the efficacy/safety binomial, which is accomplished through careful clinical judgment.

Fondaparinux (Arixtra®, GlaxoSmithKline, Brentford, UK) is a synthetic pentasaccharide that indirectly inhibits factor Xa through plasma antithrombin. The administration of a single daily dose of 2.5 mg subcutaneously shows a peak plasma concentration within 2 hours and a renal clearance half-life of 17 hours. Compared with enoxaparin in the randomised trial Fifth Organization to Assess Strategies in Acute Ischemic Syndromes (OASIS-5) that involved 20,078 patients with NSTEMACS, fondaparinux promoted a significant reduction of severe bleeding at day nine (2.2% vs. 4.1%;  $P < 0.001$ ); the impact on decreased mortality at day 30 (2.9% vs. 3.5%;  $P = 0.02$ ) and after six months (5.8% vs. 6.5%;  $P = 0.05$ ) is attributed to this finding, favourable to fondaparinux.<sup>2</sup>

However, among the 6,238 patients in the OASIS-5 study submitted to percutaneous coronary intervention (PCI), a higher incidence of thrombus formation was observed in the guide catheter of the fondaparinux group (0.9% vs. 0.4%); this complication, although rare, is associated with higher rates of acute myocardial infarction (AMI) and stroke at 30 days. Intravenous supplementation with unfractionated heparin (UFH) at the time of PCI was an adequate strategy to prevent this phenomenon, a finding that was subsequently validated in a large randomised study designed for this purpose.<sup>3</sup>

The present study aimed to evaluate the efficacy and safety of PCI in patients with a diagnosis of NSTEMACS previously treated with fondaparinux in a 'real-world' clinical setting.

## METHODS

This was a prospective controlled study involving consecutive patients who were hospitalised for unstable angina or myocardial infarction without ST-segment elevation and underwent early invasive stratification with PCI indication. The antithrombotic treatment of all patients at hospital admission consisted of 2.5 mg fondaparinux administered subcutaneously once per day, a single oral dose of aspirin of 200 to 300 mg, followed by 100 mg/daily, a single 300 to 600 mg dose of clopidogrel, followed by 75 mg/daily, or a single 180 mg dose of ticagrelor, followed by 90 mg twice daily.

After obtaining the arterial access pathway, up to 5,000 U of UFH were administered through the introducer sheath when the radial or ulnar techniques were used and 2,500 U of UFH when the femoral technique was used. When the coronary angiography was finished and PCI was indicated, the patients received supplemental intravenous UFH prior to the insertion of the intracoronary guidewire, with a total dose of 85 U/kg or 60 U/kg when the use of glycoprotein IIb/IIIa inhibitors was planned, aiming to achieve an activated coagulation time between 250 and 350 seconds. The procedure was performed following the recommendations of current guidelines.<sup>4</sup> The arterial sheath was removed immediately after the procedure when the ulnar or radial pathways were used; or after two hours, or when the activated coagulation time was  $< 180$  seconds when the femoral pathway was used.

The primary efficacy endpoint included the occurrence of cardiovascular death, AMI, stroke, stent thrombosis or emergency coronary artery bypass graft (CABG) surgery during the hospitalisation period. The primary safety endpoint consisted of severe bleeding, vascular complications at the arterial puncture site, abrupt occlusion of the target vessel, or catheter thrombosis.

In accordance with the classification of the Bleeding Academic Research Consortium,<sup>5</sup> severe bleeding was defined as type 3 (3a, bleeding with a decrease in haemoglobin  $\geq 3$  and  $< 5$  g/dL or transfusion of packed red blood cells; 3b, bleeding with a decrease in haemoglobin  $\geq 5$  g/dL or cardiac tamponade or bleeding requiring surgical intervention or intravenous vasoactive drugs; and 3c, intracranial haemorrhage or subcategories confirmed by autopsy, imaging exams or lumbar puncture or intraocular bleeding with vision impairment) or type 5 (5a, probable fatal bleeding; and 5b, definite fatal bleeding). Vascular complications at the site of the arterial puncture included retroperitoneal bleeding, compartment syndrome, hematoma  $\geq 5$  cm, pseudoaneurysm, arteriovenous fistula, infection, limb ischemia, asymptomatic arterial occlusion, adjacent nerve injury or the need for reconstructive vascular surgery. Abrupt occlusion of the target vessel was defined as thrombolysis in myocardial infarction (TIMI) flow grade 0–1 during PCI in a coronary artery with previously normal antegrade flow (TIMI 3). Catheter thrombosis was defined as the presence of newly visible and/or angiographic thrombus in the guide-catheter or any instruments used during the procedure.

Continuous variables were expressed as the mean and standard deviation, and categorical variables were expressed as absolute numbers and their percentages.

## RESULTS

From November, 2010 to November, 2011, 800 patients diagnosed with NSTEMACS underwent early invasive stratification. Of these, 317 (39.6%) underwent

PCI, of whom 127 (40.1%) used fondaparinux and dual antiplatelet therapy. These patients comprised the final sample (Figure 1).

The mean age was  $62.5 \pm 12.4$  years. Females comprised 24.4% of the study sample; 31.5% of the patients had diabetes mellitus (Table 1). Positive myocardial necrosis markers and ECG alterations suggestive of ischaemia (ST-segment depression or T-wave inversion  $> 3$  mm) were present in 68% and 89% of the sample, respectively, suggesting a high-risk population. The procedural characteristics are shown in Table 2. PCI immediately after coronary angiography (*ad hoc*) was performed in 78.7% of the cases. The radial access was the predominant pathway (95.3%). The left anterior descending artery was considered the target vessel in 51.9% of the procedures, and stents were implanted in 97.6% of the arteries. The mean hospital stay was  $3.8 \pm 0.6$  days, and the duration of fondaparinux use was  $2.3 \pm 0.3$  days.

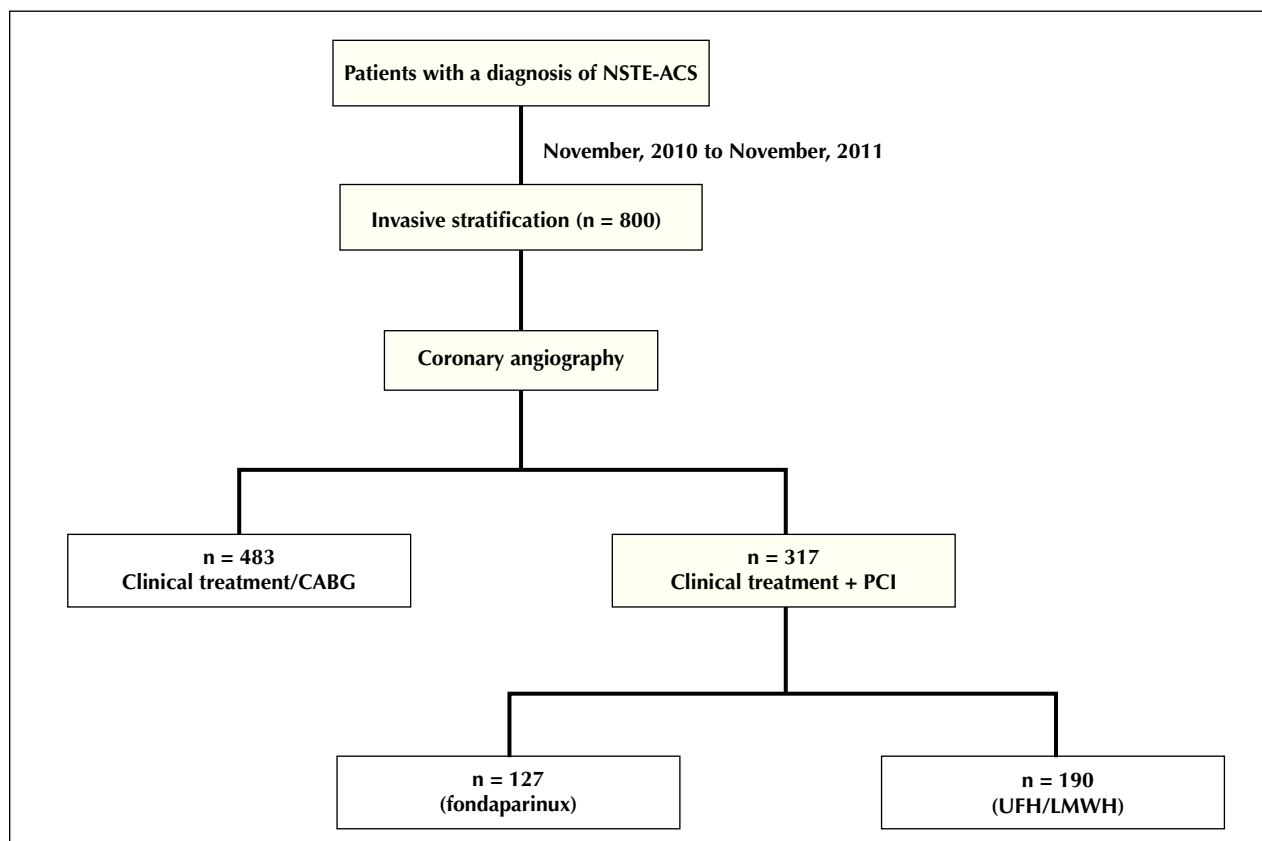
The overall incidence of adverse ischaemic cardiovascular events, which was the efficacy endpoint, was 3.2%. These events were due to one cardiovascular death (0.8%) secondary to refractory ventricular fibrillation, two periprocedural AMI (1.6%) confirmed by

elevated creatine kinase MB fraction (CK-MB)  $>$  three times the maximum reference value and one (0.8%) ischemic stroke (Figure 2). There were no cases of stent thrombosis or the need for emergency CABG.

Regarding the safety endpoint, the cumulative incidence of events during hospitalisation was 3.2%, with one episode of severe bleeding type 3b (0.8%) and a decrease in haemoglobin of 5.3 g/dL secondary to hematoma in the right upper limb and three haematomas (2.4%)  $>$  5 cm of subcutaneous location without clinical symptoms as vascular complications in the arterial puncture site (Figure 3). There were no cases of abrupt vessel occlusion or catheter thrombosis with the systematic supplementation of UFH prior to PCI.

## DISCUSSION

In patients diagnosed with NSTEMI/ACS who underwent PCI, a strong, consistent, and temporal association between the occurrence of severe bleeding and ischaemic events, including death, AMI, and stroke, can be observed.<sup>6</sup> The prognostic impact of a severe bleeding episode is comparable to that of recurrent AMI on the subsequent mortality rate.<sup>7</sup> Thus, strategies aimed at reducing or minimising the complication of maintaining



**Figure 1** – Flowchart of patients included in the registry. LMWH = low molecular-weight heparin, UFH = unfractionated heparin, PCI = percutaneous coronary intervention, n = number of patients, CABG = coronary artery bypass graft, NSTEMI/ACS = non-ST segment elevation acute coronary syndrome.

**TABLE 1**  
**Basal Demographic and Clinical Characteristics**

Variables	n = 127
Female gender, n (%)	31 (24.4)
Mean age, years	62.5 ± 12.4
Age ≥ 75 years, n (%)	22 (17.3)
Body mass index, kg/m <sup>2</sup>	27.6 ± 4.8
Diabetes mellitus, n (%)	40 (31.5)
Diabetes mellitus with insulin use, n (%)	8 (6.3)
Systemic arterial hypertension, n (%)	83 (65.4)
Dyslipidemia, n (%)	89 (70.1)
Smoking, n (%)	45 (35.4)
Family history of coronary failure, n (%)	29 (22.8)
Chronic renal failure, n (%)	4 (3.1)
Previous acute myocardial infarction, n (%)	16 (12.6)
Previous percutaneous coronary intervention, n (%)	17 (13.4)
Previous CABG, n (%)	6 (4.7)
Previous cerebrovascular accident, n (%)	4 (3.1)
Antithrombotic therapy, n (%)	
Fondaparinux	127 (100)
Aspirin	127 (100)
Clopidogrel	107 (84.3)
Ticagrelor	20 (15.7)

n = number of patients.

the anti-ischaemic efficacy are important steps in therapeutic decision-making.<sup>8</sup> Among these strategies, new commercially available antithrombotic agents, such as fondaparinux, have shown promise in clinical practice while also promoting this efficacy and safety profile.<sup>2,9,10</sup>

In the pre-specified subanalysis of the OASIS-5 study involving patients undergoing PCI, the use of fondaparinux reduced the risk of severe bleeding at nine days in 54% (2.4% vs. 5.1%;  $P < 0.00001$ ) of cases, with a similar incidence of ischaemic events compared with enoxaparin, resulting in a higher net clinical benefit (death, AMI, stroke, severe bleeding: 8.2% vs. 10.4%;  $P = 0.004$ ).<sup>11</sup> However, finding an increased risk of thrombus formation in the guide catheter, a condition unfavourable to fondaparinux, led to a conservative attitude regarding its acceptance in this group of patients.

**TABLE 2**  
**Characteristics of the Procedures**

Variables	n = 127
Percutaneous coronary intervention <i>ad hoc</i> , n (%)	100 (78.7)
Elective percutaneous coronary intervention, n (%)	27 (21.3)
Radial access, n (%)	121 (95.3)
Ulnar access, n (%)	4 (3.1)
Femoral access, n (%)	2 (1.6)
Crossover rate, n (%)	1 (0.8)
5 F guide-catheter, n (%)	4 (3.1)
6 F guide-catheter, n (%)	123 (96.9)
Number of catheters	1.2 ± 0.4
Duration of procedure, minutes	28.9 ± 13.4
Duration of fluoroscopy, minutes	7.3 ± 4.4
Target-vessel, n (%)	
Left main coronary artery	4 (3.1)
Anterior descending artery	66 (51.9)
Right coronary artery	33 (25.9)
Circumflex artery	32 (25.2)
Stent implant, n (%)	124 (97.6)
Number of stents per patient	1.2 ± 0.6
Drug-eluting stent, n (%)	21 (16.5)
Bare-metal stent, n (%)	106 (83.5)
Pre-dilation, n (%)	49 (38.6)
Post-dilation, n (%)	68 (53.5)
Glycoprotein IIb/IIIa inhibitor, n (%)	31 (24.4)
Sedation, n (%)	58 (45.7)
Angiographic success, n (%)	125 (98.4)

n = number of patients.

The observation that UFH supplementation prior to PCI reduced the risk of this complication led to the randomised Fondaparinux Trial with Unfractionated Heparin During Revascularization in Acute Coronary Syndromes (FUTURA/OASIS-8), which aimed to determine the optimal dose of UFH to be administered during the procedure and to determine whether its addition would attenuate the benefits achieved with fondaparinux in reducing bleeding.<sup>3</sup> That study, which involved 2,026 patients, concluded that a dose of intravenous UFH of 85 U/kg guided by the activated coagulation time did not increase bleeding and vascular complications

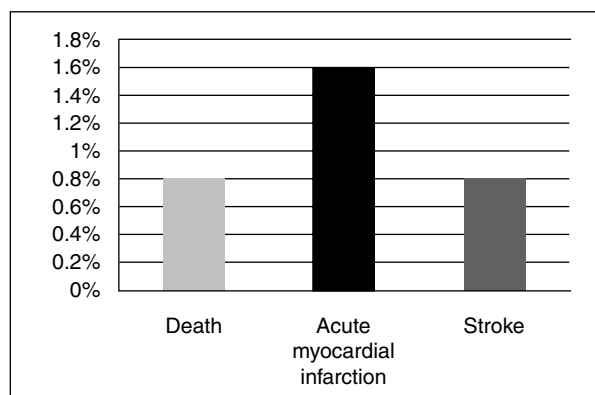


Figure 2 – Primary efficacy endpoint.

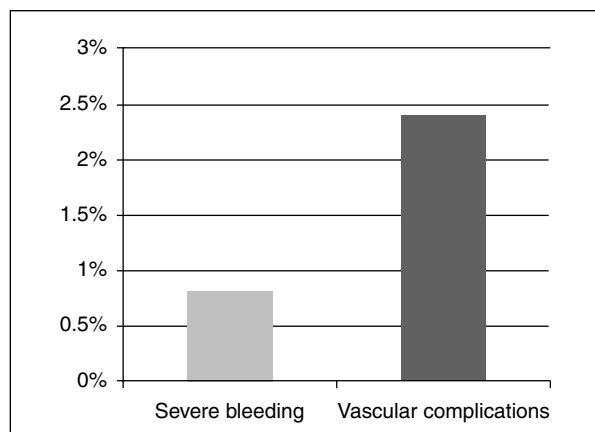


Figure 3 – Primary safety endpoint.

compared to a fixed dose of 50 U/kg, with an almost null rate (0.1%) of guide catheter thrombosis and a tendency towards the reduction of ischaemic events.

Based on the results of these studies, treatment of NSTEMACS with fondaparinux plus UFH when PCI is necessary has been considered the anticoagulant strategy with better efficacy and a better safety profile, garnering a class I recommendation and a level of evidence A, according to a recent European guideline.<sup>1</sup> However, the use of stringent and often restrictive inclusion and exclusion criteria in randomised trials gives this selected population a status of non-representativeness in daily clinical practice. In this context, consecutive and controlled registries still provide an accurate picture of contemporary practice, and are sources of information that allow critical analysis when applying a therapeutic tool.

The present sample had a mean age > 60 years, of which 17% were aged > 75 years. Subjects had a high prevalence of positive myocardial necrosis markers and ischaemic electrocardiographic alterations. The antithrombotic drug therapy consisted of systematically administered fondaparinux and dual antiplatelet therapy. This therapy added to early invasive stratification and

promoted a decrease of in-hospital incidence of ischaemic adverse cardiovascular events and episodes of severe bleeding. A low rate of bleeding complications was observed, which was dissimilar from the findings of major international records, which showed a rate of near 9% in a sample with similar risk.<sup>12,13</sup> This finding is attributed to the fact that, in addition to the routine use of fondaparinux, the radial or ulnar accesses were the preferred pathways when performing invasive coronary procedures, which composed 98.4% of the cases. Consistent evidence indicates that the choice of radial access rather than femoral access, especially when the surgeon has experience with the technique, promotes the reduction of vascular complications, death, AMI, stroke, and major bleeding unrelated to CABG surgery.<sup>14–16</sup> Besides, by instituting supplemental UFH therapy immediately after the arterial sheath is placed, in addition to complementing the dose because of the need for PCI, no thrombotic complications related to the procedure or instruments were observed, and a higher risk of bleeding was thus avoided.

### Study limitations

The limitations of the present study included its observational nature, the absence of a control group, using alternative anticoagulant treatment, the limited number of patients (as it represents the authors' initial report on their experience with a new drug), and the lack of follow-up with patients after hospital discharge once the high cumulative mortality at one year in this clinical setting was known.<sup>17</sup>

### CONCLUSIONS

In patients with NSTEMACS, i.e., those representative of the 'real world' who were previously treated with fondaparinux, the adjuvant infusion of UFH before PCI eliminated the risk of thrombus formation in the catheter due to its low rate of adverse ischaemic cardiovascular events and severe haemorrhagic complications.

### CONFLICTS OF INTEREST

The authors declare no conflicts of interest.

### REFERENCES

1. Hamm CW, Bassand JP, Agewall S, Bax J, Boersma E, Bueno H, et al. ESC Guidelines for the management of acute coronary syndromes in patients presenting without persistent ST-segment elevation. *Eur Heart J*. 2011;32(23):2999-3054.
2. Yusuf S, Mehta SR, Bassand JP, Budaj A, Chrolavicius S, Fox KAA, et al. Comparison of fondaparinux and enoxaparin in acute coronary syndromes. *N Engl J Med*. 2006;354(14):1464-76.
3. Steg PG, Jolly SS, Mehta SR, Afzal R, Xavier D, Rupprecht HJ, et al. Low-dose vs standard-dose unfractionated heparin for percutaneous coronary intervention in acute coronary syndromes treated with fondaparinux: the FUTURA/OASIS8 randomized trial. *JAMA*. 2010;304(12):1339-49.

4. Mattos LA, Lemos Neto PA, Rassi A Jr, Marin Neto JA, Sousa AGMR, Devito FS, et al. Diretrizes da Sociedade Brasileira de Cardiologia: intervenção coronária percutânea e métodos adjuntos diagnósticos em cardiologia intervencionista (II edição – 2008). *Arq Bras Cardiol.* 2008;91(6 Supl 1):158.
5. Mehran R, Rao SV, Bhatt DL, Gibson CM, Caixeta A, Eikelboom J, et al. Standardized bleeding definitions for cardiovascular clinical trials: a consensus report from the Bleeding Academic Research Consortium. *Circulation.* 2011;123(23):273647.
6. Eikelboom JW, Mehta SR, Anand SS, Xie C, Fox KA, Yusuf S. Adverse impact of bleeding on prognosis in patients with acute coronary syndromes. *Circulation.* 2006;114(8):77482.
7. Pocock SJ, Mehran R, Clayton TC, Nikolsky E, Parise H, Fahy M, et al. Prognostic modeling of individual patient risk and mortality impact of ischemic and hemorrhagic complications: assessment from the Acute Catheterization and Urgent Intervention Triage Strategy Trial. *Circulation.* 2010;121(1): 4351.
8. Steg PG, Huber K, Andreotti F, Arnesen H, Atar D, Badimon L, et al. Bleeding in acute coronary syndromes and percutaneous coronary interventions: position paper by the Working Group on Thrombosis of the European Society of Cardiology. *Eur Heart J.* 2011;32(15):185464.
9. Stone GW, McLaurin BT, Cox DA, Bertrand ME, Lincoff AM, Moses JW, et al.; ACUITY Investigators. Bivalirudin for patients with acute coronary syndromes. *N Engl J Med.* 2006;355(21): 220316.
10. Wallentin L, Becker RC, Budaj A, Cannon CP, Emanuelsson H, Held C, et al. Ticagrelor versus clopidogrel in patients with acute coronary syndromes. *N Engl J Med.* 2009;361(11): 104557.
11. Mehta SR, Granger CB, Eikelboom JW, Bassand JP, Wallentin L, Faxon DP, et al. Efficacy and safety of fondaparinux versus enoxaparin in patients with acute coronary syndromes undergoing percutaneous coronary intervention: results from the OASIS5 trial. *J Am Coll Cardiol.* 2007;50(18):174251.
12. Kadakia MB, Desai NR, Alexander KP, Chen AY, Foody JM, Cannon CP, et al. Use of anticoagulant agents and risk of bleeding among patients admitted with myocardial infarction: a Report from the NCDR ACTION RegistryGWTG (National Cardiovascular Data Registry Acute Coronary Treatment and Intervention Outcomes Network Registry Get With the Guide lines). *JACC Cardiovasc Interv.* 2010;3(11):116677.
13. Subherwal S, Bach RG, Chen AY, Gage BF, Rao SV, Newby LK, et al. Baseline risk of major bleeding in nonSTsegment elevation myocardial infarction: the CRUSADE (Can Rapid risk stratification of Unstable angina patients Suppress ADverse outcomes with Early implementation of the ACC/AHA guide lines) Bleeding Score. *Circulation.* 2009;119(14):187382.
14. Jolly SS, Amlani S, Hamon M, Yusuf S, Mehta SR. Radial versus femoral access for coronary angiography or intervention and the impact on major bleeding and ischemic events: a systematic review and metaanalysis of randomized trials. *Am Heart J.* 2009;157(1):13240.
15. Chase AJ, Fretz EB, Warburton WP, Klinke WP, Carere RG, Pi D, et al. Association of the arterial access site at angioplasty with transfusion and mortality: the M.O.R.T.A.L study (Mortality benefit Of Reduced Transfusion after percutaneous coronary intervention via the Arm or Leg). *Heart.* 2008;94(8): 101925.
16. Jolly SS, Yusuf S, Cairns J, Niemela K, Xavier D, Widimsky P, et al. Radial versus femoral access for coronary angiography and intervention in patients with acute coronary syndromes (RIVAL): a randomised, parallel group, multicentre trial. *Lancet.* 2011;377(9775):140920.
17. Tang EW, Wong CK, Herbison P. Global Registry of Acute Coronary Events (GRACE) hospital discharge risk score accurately predicts longterm mortality post acute coronary syndrome. *Am Heart J.* 2007;153(1):2935.