



CASE FOR DIAGNOSIS

European Diploma in Radiology (EDiR) clinical cases

Casos prácticos del Diploma Europeo en Radiología (EDiR)

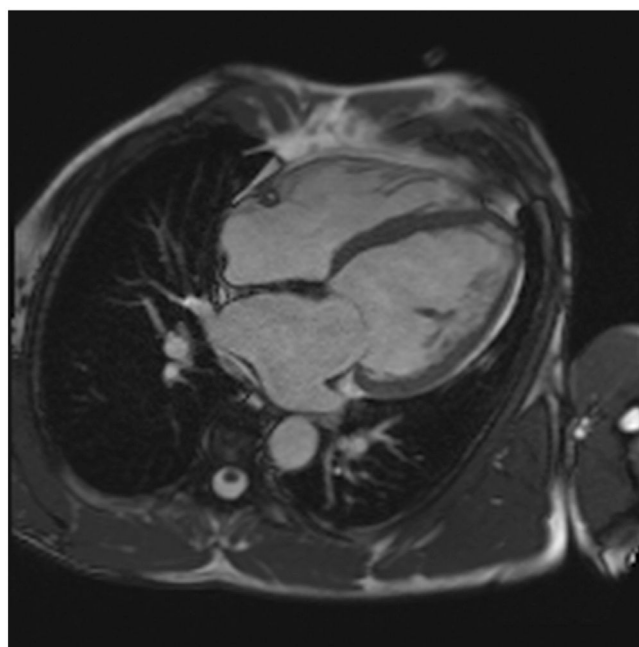
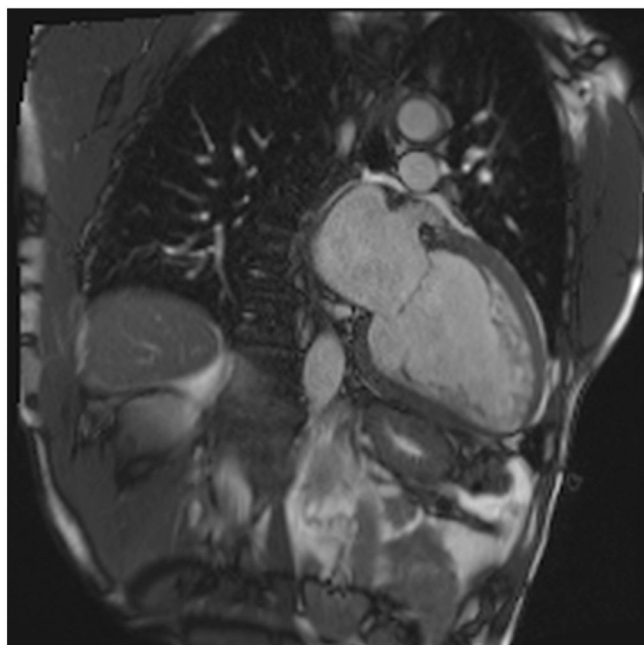
Editorial Board of Radiology

Available online 12 June 2024

Clinical guidance case

56-year-old male:

- Ex-smoker
- History of stroke 4 years before, studied for a ECG anomaly
- No family history of heart disease



Question 1. (Free-text question – No answer options provided)

What are the most relevant features and its location in the images shown?

Question 2. According to the MR findings, which is the most probable diagnosis?

(Only one option is correct)

- Apical hypertrophic cardiomyopathy
- Dilated cardiomyopathy
- Left ventricular thrombus
- Left ventricular noncompaction

Question 3. (Free-text question – No answer options provided)

Do you think myocardial fibrosis is present or not? Why?

Appendix A. Supplementary data

Supplementary material related to this article can be found, in the online version, at doi:<https://doi.org/10.1016/j.rx.2024.03.004>.