

CASE FOR DIAGNOSIS

Clinically Oriented Reasoning Evaluation (CORE)

Casos prácticos del Diploma Europeo en Radiología (EDiR)

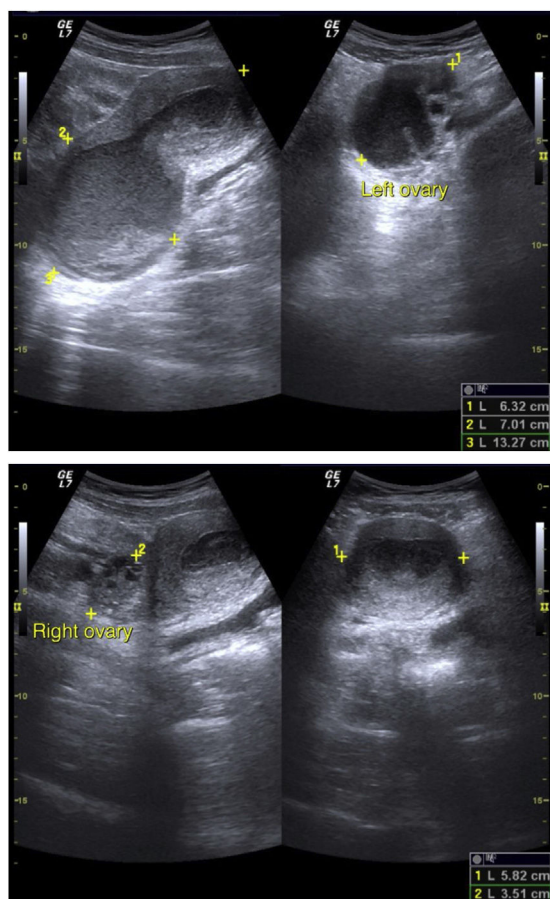


Editorial Board of Radiology

Available online 30 October 2023

Clinical data

2-year-old girl with four episodes of abdominal pain in the last 4 months:



Question 1

Describe the findings.

(Free-text question – No answer option provided)

Question 2

MRI is performed. The videos are included in additional material.

Describe the findings in the different sequences.

(Free-text question – No answer options provided)

Question 3

Regarding this congenital malformation, what would be your differential diagnosis?

(Free-text question – No answer options provided)

Appendix A. Supplementary data

The responses and additional material to this case in its electronic version available at doi:<https://doi.org/10.1016/j.rxeng.2023.10.001>.