Open Respiratory Archives 8 (2026) 100508

Sociedad Española de Neumología y Cirugía Torácica SEPAR

Open Respiratory Archives

www.elsevier.es/ora

Clinical Image

Giant Bronchoesophageal Fistula in Advanced Lung Cancer: A Case Report

Fístula broncoesofágica gigante en cáncer de pulmón avanzado: reporte de caso

Jorge Mora Pinilla[a,*], Fernando García Prieto[a,b], Diego Durán Barata[a,b], María Teresa Río Ramírez[a,b]

[a] *Servicio de Neumología, Hospital Universitario de Getafe, Madrid, Spain*
[b] *Universidad Europea de Madrid, Faculty of Biomedical and Health Sciences, Spain*

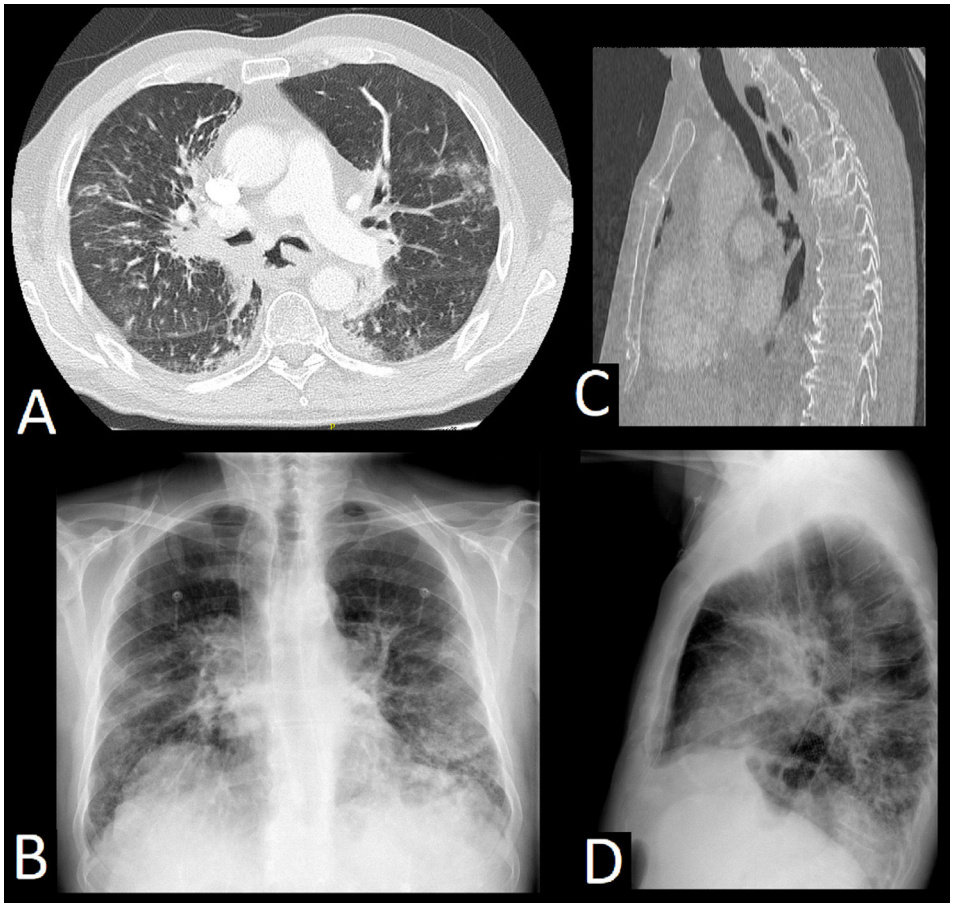

Fig. 1. (A and C) Thoracic computed tomography showing a bronchoesophageal fistula involving the left main bronchus. (B and D). Chest radiography after endoscopic intervention shows an esophageal stent.

* Corresponding author.
E-mail address: correojorgemora@gmail.com (J. Mora Pinilla).

https://doi.org/10.1016/j.opresp.2025.100508
2659-6636/© 2025 Sociedad Española de Neumología y Cirugía Torácica (SEPAR). Published by Elsevier España, S.L.U. This is an open access article under the CC BY-NC-ND license (http://creativecommons.org/licenses/by-nc-nd/4.0/).

We report the case of a 69-year-old man with stage T4N3M0 squamous cell lung carcinoma, initially treated with carboplatin, vinorelbine, and sequential radiotherapy. Following disease progression, second-line treatment with carboplatin and pembrolizumab began for a total of 3 cycles. Five months later, the patient was admitted with aspiration pneumonia. Chest computed tomography revealed a giant bronchoesophageal fistula (Fig. 1), confirmed by bronchoscopy, manifesting as a direct communication between the left main bronchus and the esophagus (Video 1) with an orifice exceeding 1.5 cm in diameter. Because of the size of the fistula and the clinical context, a multidisciplinary team decided on palliative placement of an esophageal stent (Fig. 1). This led to clinical and radiological improvement. The patient was discharged home with palliative care and, unfortunately, died 1 month after the procedure. Bronchoesophageal fistula is an exceptional complication of lung cancer. The estimated incidence is <0.3%,[1] but it can be as high as 2% in patients receiving chemoradiotherapy or immunotherapy.[2] According to Grass et al.,[3] treatment should aim for bilateral fistula closure whenever feasible within a multidisciplinary management framework. In selected patients, palliative endoscopic interventions can significantly improve quality of life and survival. This case emphasizes the exceptional diagnostic challenge posed by a giant bronchoesophageal fistula and the decisive role of multidisciplinary management in achieving an effective palliative outcome.

Declaration of generative AI and AI-assisted technologies in the writing process

For the preparation of this article in English, the Chat GPT platform was used occasionally. After using this tool, the authors reviewed and edited the content as needed and take full responsibility for the content of the publication.

Informed consent

We obtained the patient's informed consent to publish his case.

Funding

This research did not receive any specific grant from funding agencies in the public, commercial, or not-for-profit sectors.

Authors' contributions

All authors have contributed to the preparation, writing and review of the article.

Conflicts of interest

The authors declare that they do not have any conflicts of interest that might influence the content of the manuscript directly or indirectly.

Appendix A. Supplementary data

Supplementary data associated with this article can be found in the online version available at https://doi.org/10.1016/j.opresp.2025.100508.

References

1. Smith C, Bannon M, Ashraf A, Kaushik P, Marak C. Bronchoesophageal fistula: an unusual manifestation of lung cancer. Respir Med Case Rep. 2022;37, http://dx.doi.org/10.1016/j.rmcr.2022.101634, 101634.
2. Pao TH, Chen YY, Chang WL, Chang JSM, Chiang NJ, Lin CY, et al. Esophageal fistula after definitive concurrent chemotherapy and intensity modulated radiotherapy for esophageal squamous cell carcinoma. PLoS One. 2021;16, http://dx.doi.org/10.1371/journal.pone.0250803, e0250803.
3. Grass JK, Küsters N, von Döhren FL, Melling N, Ghadban T, Rösch T, et al. Management of esophageal cancer-associated respiratory–digestive tract fistulas. Cancers (Basel). 2022;14:5120, http://dx.doi.org/10.3390/cancers14051220.