

Scientific letter

Endobronchial Valves in the Management of Recurrent Hemoptysis: A Case Report



Válvulas endobronquiales en el manejo de la hemoptisis recurrente, a propósito de un caso

Dear Editor,

Recurrent hemoptysis in patients with structural lung disease is a common complication that can be life-threatening and difficult to manage.^{1–3}

Endobronchial valves (EBVs) were initially designed for lung volume reduction in severe emphysema, and other indications include the treatment of bronchopleural fistulas and persistent postoperative air leaks.^{1,3}

We report the use of EBVs in the management of a patient with recurrent threatening hemoptysis despite arterial embolization.

A 29-year-old man with a history of pulmonary tuberculosis in childhood presented with apical cavities in the left upper lobe (LUL) and sequelae including structural damage and loss of volume of the left lung (Fig. 1). In the last 6 months, he was frequently hospitalized for life-threatening hemoptysis, requiring admission to the respiratory semi-critical care unit and bronchial artery embolization (BAE) on up to six occasions. After the last embolization, he had persistent hemoptysis, complicated by acute pulmonary embolism (PE) in the right lower lobe that required placement of an inferior vena cava filter. PE was probably secondary to embolization with Glubran 2® (GEM SRL, Viareggio, Italy). The indication for urgent surgery (left pneumonectomy) was rejected due to the high surgical risk, and after assessment with interventional pulmonology unit, EBVs were placed.

Under sedation and relaxation by anesthesiology, the therapeutic flexible bronchoscope (BF-1TH190, Olympus-Europe, Hamburg, Germany) was introduced via a number 8.5 mm orotracheal tube. The presence of fresh clots and remaining bleeding were observed in the left main bronchus coming from both bronchi of the culmen and the lingula. EBVs (Spiration IBV Valve System®, Olympus, Tokyo, Japan) of 6 mm and 9 mm respectively were placed, with good bronchial occlusion (Fig. 1). The patient's clinical progress was optimal, with no recurrence of hemoptysis, and he was discharged from hospital. For 6 months, he had no episodes of hemoptysis and finally underwent left pneumonectomy after a new episode of hemoptysis, when he was in better condition.

Hospital management of life-threatening hemoptysis includes general measures and protection of the main airway. In the latter case, embolization of the bronchial arteries and/or bronchoscopy

procedures may facilitate the therapeutic option.^{1,6} This, currently, in cases of persistent hemoptysis with a specific bleeding site, is surgical resection, that may be indicated after considering the greater risk of postoperative complications and mortality.^{1,3,6}

The objective of endoscopic treatment in the management of hemoptysis is to achieve local tamponade and hemostasis in endoluminal lesions, especially lung cancer, and various treatments such as balloon occlusion, electrocautery, argon plasma coagulation, among others, have been described^{1,6}; however, these methods are of little use in the treatment of hemoptysis caused by tuberculosis or distal structural pulmonary disease.^{4,5}

In our case, the patient presented recurrent threatening hemoptysis after several embolizations, and the use of EBV was agreed upon prior to the elective surgical option.

Case reports have been reported on the use of EBV in the management of recurrent life-threatening hemoptysis in both benign and malignant pathology.

In the case of benign pathology, Frey et al. placed 2 Spiration EBVs in the LUL of a patient with septic pulmonary embolisms due to *Staphylococcus* bacteremia and recurrent hemoptysis, in whom BAE could not be performed.¹ Koegelenberg et al. placed 2 Spiration EBVs in the right upper lobe (RUL) and LUL in a patient with hemoptysis and tuberculosis sequelae with aspergilloma.³ Lalla et al. reported another case of a Zephyr type EBV placed in the LUL of a man with HIV and active tuberculosis and recurrent hemoptysis, in whom the valve was removed after 6 months with no recurrence of hemoptysis.⁴ All cases were successful.

In malignant pathology, Patel et al. report two cases of Spiration EBV placement, the first in squamous cell carcinoma of RUL, and the second in an esophageal neoplasia with mediastinal invasion that caused hemoptysis from the RUL. Both cases were successful, and there was no recurrence of hemoptysis.²

It has been suggested that the effectiveness of EBV in the management of hemoptysis is due to atelectasis, which in turn promotes local tamponade, favoring clot formation and reducing blood flow to the bleeding area through hypoxic vasoconstriction.^{1,2} If the etiology of hemoptysis is benign and/or reversible, the EBV can be removed after treatment.^{2,4}

There are two types of EBV: Zephyr valves that are used in the management of hemoptysis of infectious etiology^{1,4}; and Spiration valves that are used in the management of hemoptysis of both infectious and malignant etiology.^{1–3} In our case, we opted for Spiration valves due to the greater experience of our team.

This procedure could be an alternative in the management of recurrent hemoptysis in patients who are not candidates for surgery or as a preliminary step toward elective surgery.

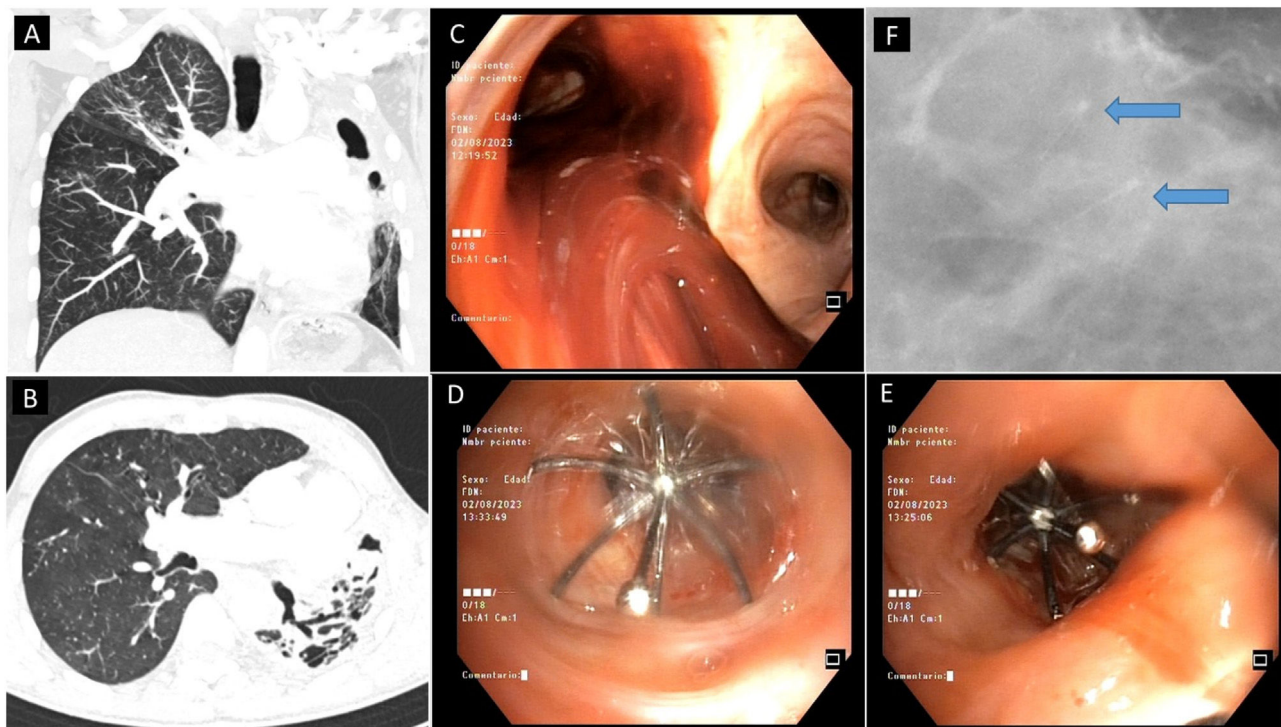


Fig. 1. (A and B) CT scan of the coronal and transverse slices, caverns in LUL with loss of volume and structural damage of the left lung. (C) Revision bronchoscopy, clots in left main bronchus from LUL. (D) Spiration EBV number 9 in lingula. (E) Spiration EBV number 6 at the top. (F) Chest X-ray, zoom of the LUL apical region showing the 2 EBVs.

Informed consent

Informed consent was obtained from the patient for the publication of his clinical data and the use of diagnostic images.

Funding

The authors declare that no funding was received for this article.

Authors' contributions

All the listed authors have made substantial contributions to all areas as outlined therein.

Conflicts of interest

None of the authors has any conflict of interest of any type.

References

1. Frey JW, Postigo M, Pitts LR. Endobronchial valve placement as salvage therapy in the management of hemoptysis. *J Bronchology Interv Pulmonol.* 2023;30:301–3, <http://dx.doi.org/10.1097/LBR.0000000000000898> [PMID: 36083199].
2. Patel B, Abi-Fadel D, Rosenheck J, Bartter T, Boujaoude Z, Abouzgheib W. Endobronchial valves for treatment of hemoptysis. *J Bronchology Interv Pulmonol.* 2019;26:e22–4, <http://dx.doi.org/10.1097/LBR.0000000000000570> [PMID: 30908397].
3. Koegelenberg CF, Bruwer JW, Bolliger CT. Endobronchial valves in the management of recurrent haemoptysis. *Respiration.* 2014;87:84–8, <http://dx.doi.org/10.1159/000355198> [Epub 04.12.13; PMID: 24334859].
4. Lalla U, Allwood BW, Sinha Roy S, Irusen EM, Koegelenberg CFN. Endobronchial valve used as salvage therapy in a mechanically ventilated patient with intractable life-threatening haemoptysis. *Respiration.* 2017;93:436–40, <http://dx.doi.org/10.1159/000465526> [Epub 30.03.17; PMID: 28355597].
5. Sakr L, Dutau H. Massive hemoptysis: an update on the role of bronchoscopy in diagnosis and management. *Respiration.* 2010;80:38–58, <http://dx.doi.org/10.1159/000274492> [Epub 08.01.10; PMID: 20090288].
6. Cordovilla R, Bollo de Miguel E, Nuñez Ares A, Cosano Povedano FJ, Herráez Ortega I, Jiménez Merchán R. Diagnosis and treatment of hemoptysis. *Arch Bronconeumol.* 2016;52:368–77, <http://dx.doi.org/10.1016/j.arbres.2015.12.002> [in English, Spanish; Epub 09.02.16; PMID: 26873518].

Alan Jhuniol Solis Solis*, Carmen Angela Centeno Clemente, Antoni Rosell Gratacos

Interventional Pulmonology Department, Hospital University Germans Trias i Pujol, Badalona, Barcelona, Spain

* Corresponding author.

E-mail address: alanjhuniorsolis@gmail.com (A.J. Solis Solis).