




NEUROLOGY PERSPECTIVES

www.journals.elsevier.com/neurology-perspectives



ORIGINAL ARTICLE

Approach to non-compressive myeloneuropathy through a rendezvous of 11 cases from an Indian backdrop

R. Ghosh^a, D. Roy^{b,c,d}, A. Mandal^a, M. León-Ruiz^e, S. Das^f, S. Dubey^f, A. Jana^g, S. Purkait^a, T. Ghosh^h, J. Benito-León^{i,j,k,*}

^a Department of General Medicine, Burdwan Medical College and Hospital, Burdwan, West Bengal, India

^b Department of Biochemistry, All India Institute of Medical Sciences (AIIMS), Patna, Bihar, India

^c Indian Institute of Technology (IIT), Madras, Tamil Nadu, India

^d School of Humanities, Indira Gandhi National Open University, New Delhi, India

^e Section of Clinical Neurophysiology, Department of Neurology, University Hospital "La Paz", Madrid, Spain

^f Department of Neuromedicine, Bangur Institute of Neurosciences (BIN), Kolkata, West Bengal, India

^g Department of Radio-diagnosis, Burdwan Medical College and Hospital, Burdwan, West Bengal, India

^h Department of Anatomy, Burdwan Medical College and Hospital, Burdwan, West Bengal, India

ⁱ Department of Neurology, University Hospital "12 de Octubre", Madrid, Spain

^j Centro de Investigación Biomédica en Red Sobre Enfermedades Neurodegenerativas (CIBERNED), Madrid, Spain

^k Department of Medicine, Complutense University, Madrid, Spain

Received 17 January 2023; accepted 17 July 2023

Available online 17 November 2023

KEYWORDS

Myeloneuropathy;
Case series;
Diagnostic Approaches

Abstract

Introduction: Myeloneuropathy is a diagnosis ascribed to disorders that concomitantly affect the spinal cord and peripheral nerves. Recognizing this syndrome may sometimes be arduous, even for the most consummate clinicians, because symptomatology can mimic either spinal cord or peripheral nerve disease. Besides, examination findings suggest a predominantly myelopathic or neuropathic picture. This article reports a rendezvous of rare cases of clinically diagnosed myeloneuropathy with different etiological backgrounds and therapeutic responses.

Methods: Eleven cases of non-compressive myeloneuropathy were admitted to the Department of General Medicine of Burdwan Medical College and Hospital, Burdwan, West Bengal, India, between May 2018 and May 2022.

Results: We report the cases of 11 patients (6 men and 5 women) who presented with myeloneuropathy of different etiologies (vitamin B12, copper, and vitamin E deficiencies, organophosphate poisoning, chronic alcohol abuse, illicit substances abuse, anti-thyroid peroxidase/anti-thyroglobulin antibody-related neurologic disorder responsive to steroids, Sjögren syndrome, chikungunya infection, paraneoplastic, and hereditary).

Conclusion: Meticulous historical analysis, careful clinical examination, and apposite utilization and interpretation of biochemical, electrophysiological, and neuroimaging findings are sine-qua-

* Corresponding author.

E-mail address: jbenitol67@gmail.com (J. Benito-León).

non for an accurate and consistent approach to evaluating a suspected case of myeloneuropathy, facilitating early treatment and recovery. Differential identification of these disorders needs an in-depth perception of the mode of onset of symptoms, the course of progression of the disease, the pattern of myelopathic/neuropathic findings, and recognition of other neurological or systemic manifestations. For untroubled understanding, etiologies of myeloneuropathies should be subdivided into a few broad categories, e.g., metabolic (nutritional), toxic (toxin-induced), infectious, inflammatory (immune-mediated), paraneoplastic, and hereditary disorders.

© 2023 Sociedad Española de Neurología. Published by Elsevier España, S.L.U. This is an open access article under the CC BY-NC-ND license (<http://creativecommons.org/licenses/by-nc-nd/4.0/>).

PALABRAS CLAVE

Mieloneuropatía;
Serie de casos,
Aproximación
diagnóstica

Aproximación a la Mieloneuropatía no Compresiva a través de una Serie de 11 Casos en un Contexto Indio

Resumen

Introducción: La mieloneuropatía es un síndrome que afecta concomitantemente la médula espinal y los nervios periféricos. Reconocerlo a veces puede ser arduo, incluso para los médicos más experimentados, porque la sintomatología puede simular una enfermedad de la médula espinal o de los nervios periféricos. Además, los hallazgos del examen sugieren un cuadro predominantemente mielopático o neuropático. Este artículo describe una serie de casos raros de mieloneuropatía de distintas causas y con respuestas terapéuticas distintas.

Métodos: Once casos de mieloneuropatía no compresiva fueron ingresados en el Departamento de Medicina General del Burdwan Medical College, and Hospital, Burdwan, Bengala Occidental, India, entre mayo de 2018 y mayo de 2022.

Resultados: Presentamos 11 pacientes (seis hombres y cinco mujeres) con mieloneuropatía de diferentes etiologías (deficiencias de vitamina B12, cobre y vitamina E, intoxicación por organofosforados, abuso crónico de alcohol, abuso de sustancias ilícitas, trastorno neurológico relacionado con anticuerpos anti-tiroglobulina / antiperoxidasa tiroidea que responde a esteroides, síndrome de Sjögren, infección por chikungunya, paraneoplásico y hereditario).

Conclusión: El análisis meticuloso de la historia y del examen clínico, así como la utilización e interpretación adecuadas de los hallazgos bioquímicos, electrofisiológicos y de neuroimagen son condiciones sine qua non para un enfoque preciso y consistente para evaluar un caso sospechoso de mieloneuropatía, lo que facilita el tratamiento temprano y su recuperación. El diagnóstico diferencial de esta patología requiere un conocimiento del modo de inicio de los síntomas, su progresión, el patrón de hallazgos mielopáticos/neuropáticos y el reconocimiento de otras manifestaciones neurológicas o sistémicas. Las etiologías de las mieloneuropatías deben subdividirse en trastornos metabólicos (nutricionales), tóxicos (inducidos por toxinas), infecciosos, inflamatorios (mediados por mecanismos inmunitarios), paraneoplásicos y hereditarios.

© 2023 Sociedad Española de Neurología. Publicado por Elsevier España, S.L.U. Este es un artículo Open Access bajo la licencia CC BY-NC-ND (<http://creativecommons.org/licenses/by-nc-nd/4.0/>).

Introduction

Disorders that concurrently affect the spinal cord and peripheral nerves can be characterized as myeloneuropathies.¹ An assiduous retrieval of history and conscientious neurological examination is sine-qua-non for syndromic and etiological diagnosis of myeloneuropathy.² Unsteadiness of gait, subtle/obvious weakness involving limbs, bladder and bowel impairments, and various sensory symptoms can be attributed to myelopathy. Nevertheless, many of these symptoms do coexist in patients having peripheral neuropathy.³ Therefore, a careful neurologic examination and a thoughtful diagnostic evaluation are

necessary to diagnose myeloneuropathy.² Classically, bowel/bladder involvement is less common in peripheral neuropathy; however, it can be present if peripheral autonomic fibers get affected. It must be noted that even if someone reckons bladder impairment associated with peripheral neuropathy, a characteristic high-capacity bladder with incomplete bladder evacuation (high post-void residual urine) is to be expected.⁴

Attributing sensory symptoms to cord involvement or peripheral neuropathy sometimes becomes difficult. A bilaterally symmetrical "stocking-glove" pattern has been distinguishably noted for sensory symptoms in peripheral neuropathy, which usually appears in the feet first.⁵

Co-presence of sensory symptoms involving the upper and lower extremities and other myelopathic symptoms will forewarn the clinician regarding concomitant myeloneuropathy.⁶ Like the sensory symptoms, weakness ascribable to peripheral neuropathy also commences from the distal extremities and accompanies atrophy. Whereas other common sensory symptoms like “plaster-cast” sensation, dysesthesias (allodynia, hyperalgesia, or profound loss of sensations), “Lhermitte sign”, girdle-like sensation, and root-pain, when present, are suggestive of myelopathy.⁷ Whereas weakness, atrophy, sensory loss, and hyporeflexia or areflexia are typical manifestations of peripheral neuropathy, signs of myelopathy include sensory loss, weakness, spasticity, hyperreflexia, and extensor plantar responses.⁸

Long-standing peripheral neuropathy may engender permanent morphological changes in the foot, such as pes cavus or hammer-toes, frequently observed in hereditary peripheral neuropathies.⁹ It becomes arduous to appreciate subdued signs of peripheral neuropathy when upper motor neuron signs prevail in presentation. In a patient with preponderating myelopathic findings, strikingly depressed ankle deep-tendon reflexes and atrophy of the distal lower limb may be the only critical clinical clues suggesting coexisting peripheral neuropathy. Electromyography (EMG) testing often becomes crucial to recognize peripheral neuropathy.¹⁰ Also, myelopathic signs may be camouflaged in the presence of overshadowing lower motor neuron manifestations. For example, in severe peripheral neuropathy, deep tendon reflexes may be reduced/absent, and concomitantly, toe extensor paresis may be falsely mute during the elicitation of Babinski's reflex. Under such circumstances, preserved/exaggerated knee-deep tendon reflexes may be the only evidence of myelopathy alongside upper motor neuron type of bladder impairment. Generally, with peripheral neuropathy of sufficient severity to result in lower limb proprioceptive impairment, lower limb areflexia (knee and ankle) is expected.^{1,2}

This article presents a rendezvous of 11 rare cases of myeloneuropathy with different etiological backgrounds and therapeutic responses.

Methods

Eleven cases of non-compressive myeloneuropathy were admitted to the Department of General Medicine of Burdwan Medical College and Hospital, Burdwan, West Bengal, India, between May 2018 and May 2022.

Written informed consent was obtained from the patients participating in the study (consent for research). The data supporting the findings of this study are available within the article.

Results

Case 1: A case of myeloneuropathy with anemia, vitiligo, and cognitive impairment

A 60-year-old previously healthy male farmer presented to the outpatient department with repeated falls and gait unsteadiness for the last 4 months. He had insidious onset,

gradually progressive asymmetric stiffening involving both lower limbs for the last 6 months. For the last 10–12 months, the patient started having symmetrical onset tingling paresthesia in both lower limbs, distal to begin with, gradually ascending upwards, and later involving the distal upper limbs also, in a typical “gloves-stockings” pattern associated with diminished sensation in the corresponding areas over last 3 months. He also complained that he had remarkably diminished sensations below the nipple level for the last 2 months. He complained of increased urinary frequency, urgency, and urge incontinence for the last 4 weeks. There was no associated back pain, girdle-like sensation, plaster-cast sensation, zone of hyperesthesia, or root pain. He and his caregivers refuted a history of any episodes of seizure, altered sensorium, cranial nerve symptoms, headache, visual blurring, vomiting, chronic diarrhea, weight loss, fever, joint pain, or skin rashes.

The general examination was remarkable for oral ulcers, atrophic glossitis, smooth and magenta-colored tongue, non-segmental vitiligo, pallor, and hyperpigmentation on the palms (Fig. 1A and 1B). The cognitive evaluation revealed errors in the A-vigil test and trail-making test; the forward digit span was 4, and the backward digit span was 3, suggesting predominant deficits in attention and working memory. Assessments for conceptualization, abstract thinking, similarities and dissimilarities, and behavioral domain were unremarkable. There was mild asymmetric atrophy predominantly in the lower limbs, both proximally and distally; upper limbs also had evidence of early atrophy distally. There was generalized hypertonia (lower limbs more than upper limbs) with brisk deep tendon reflexes, including extensor planter responses, except a bilateral loss of ankle jerks. Motor power in both upper and lower limbs was preserved proximally. However, distally it was 4/5 in the lower limbs. There was associated truncal and neck flexor weakness. Sensory examination revealed decreased sensation of all modalities below the nipple level. Besides, fine touch was decreased in upper limbs up to elbow joints. Joint position sense was impaired up to the knee, and graded loss of vibration sense was observed in the lower limbs, the entire spine, and the wrist in the upper limb. Cerebellar functions were normal; Romberg's sign was positive.

A complete blood cell count revealed decreased hemoglobin levels of 10.0 g/dL with a mean corpuscular volume of 125 fL (normal: 80–100) with hyper-segmented neutrophils. Liver function tests revealed mild unconjugated hyperbilirubinemia with normal liver enzyme levels. Serum lactate dehydrogenase levels were raised. Renal and thyroid function tests, blood glucose indices, and serum electrolytes were within normal limits. However, magnetic resonance imaging (MRI) of the brain revealed non-specific white-matter changes; a spinal MRI was normal. Serologies for HIV (1, 2), hepatitis B, C, and syphilis were negative. A nerve conduction study suggested an acquired sensorimotor (sensory more than motor) axonal polyradiculoneuropathy. Serum vitamin B12 levels were severely low (40 pg/mL; normal 197–771 pg/mL). Subsequent testing revealed the presence of hypergastrinemia and anti-parietal cell and anti-intrinsic factor autoantibodies, confirming the diagnosis of pernicious anemia. The patient refused to undergo upper gastrointestinal endoscopy and biopsy for histopathological confirmation of atrophic gastritis.




Fig. 1 The figure shows hyperpigmentation on the palms of the hands (especially palmar creases) (A) and non-segmental vitiligo and magenta-colored depigmented tongue (B). (For interpretation of the references to color in this figure legend, the reader is referred to the web version of this article.)

Serum homocysteine ($90 \mu\text{mol/L}$; normal $5.46\text{--}16.2$) and methylmalonic acid levels (2056 nmol/L ; normal $50\text{--}440$) were high. Serum folic acid, vitamin E, and copper levels were normal, as well as the visual evoked potentials and the cerebrospinal fluid (CSF) analysis. Autoimmune (antinuclear antibody [ANA-hep 2 method], anti-nuclear antibody profile including anti-Ro and anti-La autoantibodies), and paraneoplastic profile were negative. Serum calcium and angiotensin-converting enzyme levels were normal. 2-[fluorine 18] fluoro-2-deoxy-D-glucose positron emission tomography/computed tomography scan of the whole body was unremarkable. Considering the diagnosis of pernicious anemia with B12-deficiency-related MRI-negative myeloneuropathy, he was prescribed methylcobalamin (1500 mcg intramuscularly once daily for 5 consecutive days; then once per week for 5 consecutive weeks; and then once per month to continue). There was a marked improvement in the motor and sensory symptoms. At the end of 6 months, motor power of both proximal and distal groups of muscles of both upper and lower limbs reached 5/5, along with definite improvement in sensory examination in the areas of previously diminished sensation. The bladder dysfunction though initially persisted, improved subsequently after 6 months. There was also a marked normalization of the hematological parameters.

Case 2: Unsupervised intake of over-the-counter zinc-containing medications for undiagnosed irritable bowel syndrome presenting with copper deficiency myeloneuropathy

A 31-year-old previously healthy adult male presented to the outpatient department with a history of subacute onset, progressive, symmetrical tingling and numbness starting from both feet ascending to knee level and progressive stiffness of both lower limbs, and frequent tripping and falling while walking for the last 6 months. There was no history of cognitive impairment, cranial nerve, cerebellar, or bowel/bladder dysfunctions. Historically, none of his family members suffered from any similar neurological

illness. He did not undergo any surgical procedure for any reason in the past and had no substance addiction. The general examination, neurocognitive functions, and speech were normal. Motor examination revealed that he had symmetrical clumsiness, hypertonia, hypertonia/spasticity, and mild weakness (MRC grade 4) in all groups of muscles of the lower limbs; the strength of both upper limbs was normal. All the deep tendon reflexes were brisk and plantar response was bilaterally extensor with prominent ankle clonus. Gait examination revealed a high stepping, spastic, and ataxic gait. Romberg's sign was positive and sensory examination revealed significant impairment in vibration and joint position sense. He was provisionally diagnosed with a case of myeloneuropathy with possible localization over the cervical spine.

A complete blood cell count revealed hypochromic microcytic anemia. Liver, kidney, and thyroid function tests, serum electrolytes, and blood glucose parameters were within normal limits. Contrast-enhanced MRI of the spinal cord revealed longitudinally extensive signal changes predominantly involving the posterior column over the cervical cord (Fig. 2A and B). Nerve conduction studies were otherwise suggestive of predominantly large-fiber axonal sensory neuropathy. Serum vitamin B12 and vitamin E levels, serum homocysteine, urine methylmalonic acid, and folic acid levels were normal. Anti-aquaporin-4 (AQP-4) antibody, anti-myelin-oligodendrocyte glycoprotein (MOG)-antibody, CSF IgG index, oligoclonal bands, and visual evoked potentials were normal. Plasma and CSF VDRL and FTA-abs were negative. Vasculitis screen and autoimmune profile, HIV (1, 2), hepatitis B, C, and HTLV serologies were also negative. Serum angiotensin-converting enzyme level was normal. Interestingly, serum copper level was extremely low (25 mcg/dL ; normal $70\text{--}140 \text{ mcg/dL}$) with low ceruloplasmin (15 mcg/dL ; normal $20\text{--}40 \text{ mcg/dL}$) and low 24-h urinary copper (15 mcg/dL ; normal $20\text{--}50 \text{ mcg/dL}$). However, the etiology of copper deficiency in this case initially remained unclear as medical/surgical history, celiac disease profile (anti-TTG, anti-gliadin, anti-EMA, and HLA typing for celiac disease) were all negative, and small-intestinal biopsy ruled out any other malabsorption syndromes. Serum zinc

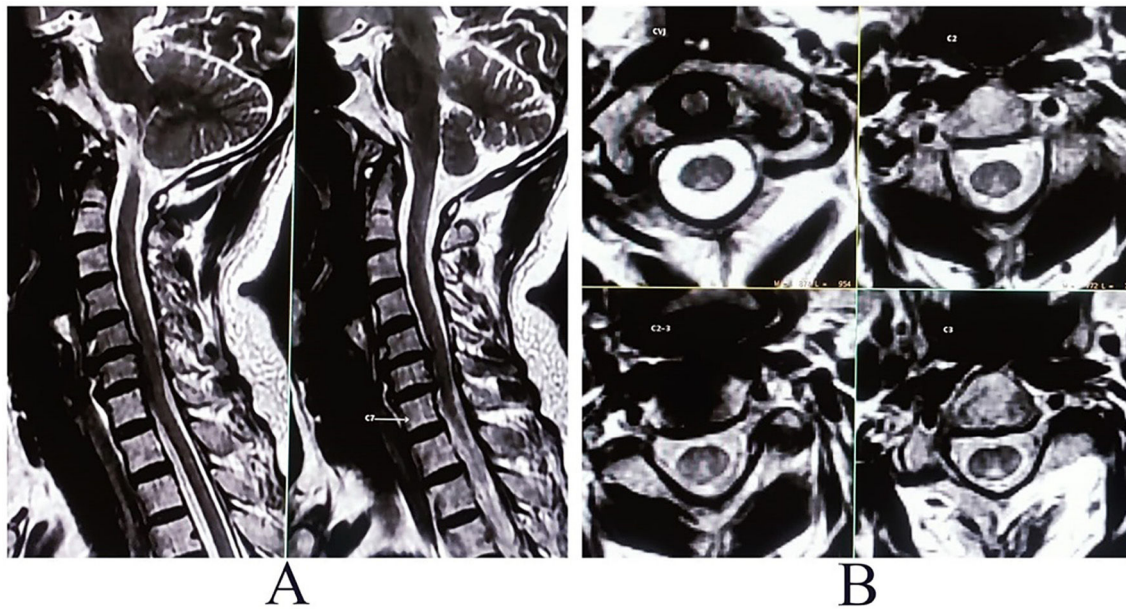


Fig. 2 MRI of the cervical spine reveals longitudinally extensive signal changes, hyper on T2-weighted image (A, sagittal and B, axial) extending from the craniocervical junction up to C4 level, distinctly involving the posterior column of the high-cervical cord.

levels were subsequently requested and found to be elevated (220 mcg/dL; normal 70–150 mcg/dL). Zinc overload has been implicated in copper deficiency. On retrospective review, our patient had been excessively using an over-the-counter oral zinc-containing drug for chronic diarrhea-predominant irritable bowel syndrome for the last 4 years.

Case 3: Vitamin E deficiency myeloneuropathy in a patient with Crohn's disease

A 38-year-old male presented to the outpatient department with insidious onset progressive tingling sensations in a “gloves-stockings” pattern for the last 2 years. It was followed by progressive gait unsteadiness (walking in the dark was particularly impossible at the presentation) for the last year. For the last 4–6 months, he also complained of fatigue, painful cramps, and stiffness in his lower limbs. Three years back, he was diagnosed with malabsorption syndrome due to widespread active Crohn's disease, for which he was on maintenance therapy with oral mesalazine pellets (2 g/day) and parenteral vitamin D, folic acid, and iron infusion as required. During the COVID-19 pandemic, he could not follow-up at his inflammatory bowel disease clinic for almost 2 years; at the current admission, he suffered from persistent diarrheal episodes and involuntary weight loss. There was no history of any addiction. No one among family members had similar sufferings. General examination was unremarkable except few signs of malnutrition and vitamin deficits (e.g., bilateral Bitot spots). Neurological examination revealed normal speech and cognitive functions, no cranial nerve deficits, bilateral lower limb spasticity (except around ankle joints), and exaggerated deep tendon reflexes (except absent bilateral ankle deep tendon reflexes) with extensor plantar responses. Strength

in all muscle groups was preserved. Vibration sense was remarkably reduced below the iliac crests and decreased below the wrists; joint position sense was diminished in the fingers and toes. Superficial sensations were normal. Gait examination revealed broad-based, high-steppage, spastic ataxic gait, impaired tandem walking, and a markedly positive Romberg's sign.

A complete blood cell count, renal, hepatic, and thyroid function tests, serum electrolytes, and creatine phosphokinase levels were normal. The fecal calprotectin level was high. MRI of the brain revealed some non-specific white matter changes and mild cerebellar atrophy. MRI of the spinal cord revealed no intramedullary intensity changes but atrophy of the cervical cord. CSF studies ruled out infective, demyelinating, and inflammatory conditions. Suspecting an underlying fat malabsorption and nutrient deficiency syndrome, vitamin A, D, and E levels were tested, and vitamin A and E levels were extremely low. Repletion with parenteral vitamins A and E was started. Progression of the neurological deficits was arrested, but the patient continued to show mild lower limb spasticity and sensory ataxia.

Case 4: Organophosphate poisoning-induced delayed myeloneuropathy

After 10 weeks, a 36-year-old male farmer presented to the outpatient department as a follow-up case of deliberate self-harm by organophosphate ingestion. He attempted suicide by drinking 150 mL of a mixture containing chlorpyrifos 50% (O, O-diethyl O-3,5,6-trichloropyridin-2-yl phosphorothioate) and cypermethrin 5% (a synthetic pyrethroid) following an episode of familial disharmony. He developed classical features of organophosphate poisoning and was treated with gastric lavage, atropine, pralidoxime infusion, and other supportive measures. He did not require

mechanical ventilation, and over the following 7 days, he made an uneventful recovery and was discharged without any neurological deficits.

This time around, he was brought to us by his caregivers with complaints of insidious onset, gradually progressive stiffness of bilateral lower limbs with walking difficulty, and frequent tripping and falls. Neurological examination revealed significant spasticity in the lower limbs with brisk deep tendon reflexes, including extensor plantar responses. There was no sensory loss of any of the modalities. He had weakness of foot dorsiflexion bilaterally, which was 3+/5 on MRC grading. The small muscles of the feet were wasted with hammer toes and pes cavus bilaterally. The combination of foot drop, scissoring, and ankle clonus gave his gait a peculiar bobbing character. The upper limbs were essentially normal on neurological examination. He also complained of bladder symptoms in the form of urgency and occasional urge incontinence.

MRI showed mildly roomy CSF space around the dorsal cord without any signal changes in the cord suggestive of focal dorsal cord atrophy (Fig. 3A, B, C) with no abnormal findings in the brain. CSF evaluation was non-contributory. A complete blood cell count, renal, hepatic, and thyroid function tests, serum electrolytes, and blood glucose profile were within normal limits. Serum B12, folate, copper, and vitamin E levels were normal. Autoimmune and paraneoplastic panels were negative, including a whole-body 2-[fluorine 18] fluoro-2-deoxy-D-glucose positron emission tomography/computed tomography scan. Finally, a diagnosis of delayed toxic myeloneuropathy following organophosphate poisoning was made. He was put on intravenous bolus methylprednisolone (1 g/day for 5 days) followed by oral steroids in gradually tapering dosage over the next month along with vitamin D, calcium, and potassium supplements. His neurological condition remained static.

Case 5: Alcohol-induced myeloneuropathy

A 35-year-old previously healthy male farmer presented to the outpatient department with insidious onset, gradually progressive burning sensation over both palms and soles for the last 6 months. It was followed by excessive and unusual sensitivity to non-painful sensory stimuli (i.e., touches that were not usually painful triggered severe painful sensations) for the last month and gradually progressive weakness of both lower limbs for the last 10 days. He had to undergo urinary catheterization 1 month ago, as he developed an

episode of acute urinary retention. Since then, he developed increased urinary urgency and frequency and urge incontinence episodes. He had a history of chronic alcohol abuse. No other relevant medical/surgical and familial history could be obtained.

A general examination revealed many stigmata of chronic alcoholic non-decompensated liver disease. Neurological examination revealed normal speech, cognitive, cranial nerves, and cerebellar functions. Motor examination revealed flaccid areflexic paraparesis (3–/5 in proximal muscles and 2–/5 in distal muscles in lower limbs) and bilateral Babinski sign. The motor power of the upper limbs was normal, and the deep tendon reflexes over the upper limbs were exaggerated. Dysautonomic features were evident on bedside autonomic function tests. MRI of the brain and spinal cord revealed no abnormality except features of early cerebellar atrophy. Nerve conduction studies revealed an acquired axonal sensorimotor polyneuropathy (lower limbs more than upper limbs).

A complete blood count revealed macrocytic hypochromic anemia. Liver function tests revealed an altered albumin/globulin ratio with 3-fold increased liver enzymes. Serum gamma-glutamyl transferase was raised. Serum B1 (thiamine), B6, B12, folic acid, copper, vitamin E, homocysteine, urinary methylmalonic acid, blood glycemic indices, and lipid profile were all normal. Relevant viral serologies were negative. Autoimmune connective tissue disease, paraneoplastic, and vasculitis profiles were negative. A whole body 2-[fluorine 18] fluoro-2-deoxy-D-glucose positron emission tomography/computed tomography scan was negative too.

He was given parenteral B1, B6, B12, and folic acid injections. After 6 weeks of therapy, there were some symptomatic improvements, but bladder urgency persisted.

Case 6: Myeloneuropathy associated with illicit substances abuse

An 18-year-old homeless male teenager was admitted to the emergency department as he complained of a sudden inability to move his lower limbs and urine retention for the last 4–6 h. He also complained of tingling and paresthesias in a stocking pattern involving both his feet that started before developing weakness 46 h after the sniffing event. He was a known illicit substance abuser who had been brought to the emergency room multiple times previously for acute substance intoxication or withdrawal syndrome. This time, a group of railway officials brought him to us as he was found

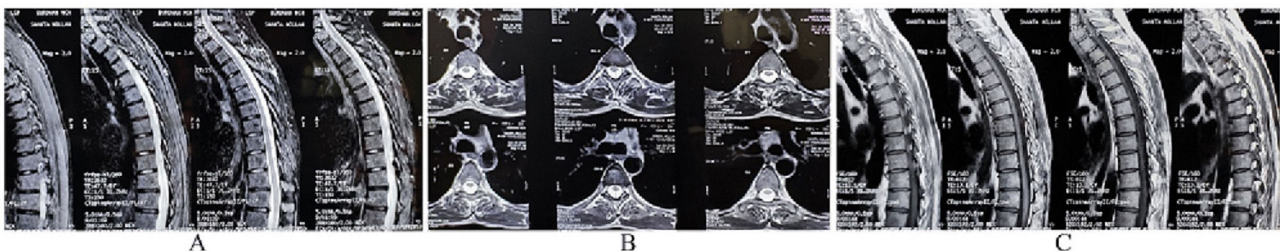


Fig. 3 MRI of the dorsal spine reveals a focal cord thinning (A: sagittal T2-weighted image, B: axial T2-weighted image, C: sagittal T1-weighted image) at D3–D10 suggestive of focal dorsal cord atrophy.

paralyzed on a farm near the railway quarters. Those officials complained that the boy inhaled heroin vapors on and off, along with other substance abuse. The patient told us that he had abstained from heroin use for more than 2 years before this incident. He denied any history of febrile illness, trauma, intravenous drug abuse, alcoholism, needle-sharing, or similar illness in any crew members (with whom he resided and shared addictive substances). The general survey was unremarkable. Neurological examination was remarkable for acute flaccid paraplegia with symmetrical length-dependent predominantly distal sensory disturbances (reduced sensations to all modalities, including vibration and joint position senses). All deep tendon reflexes in the lower limbs were absent, and extensor plantar responses were mute.

A complete metabolic panel was within normal limits. MRI of the spinal cord revealed a longitudinally extensive spinal cord lesion over the dorsal cord extending from D4 to D10 (Fig. 4A, B, C). Nerve conduction studies study after 1 week revealed an acquired axonal sensorimotor polyneuropathy. Metabolic, nutritional, inflammatory, infective, and immune-mediated etiologies were ruled out precisely with relevant investigations. Amid toxic myeloneuropathies, other causes were ruled out precisely from historical correlates, and a diagnosis of heroin-induced myeloneuropathy was performed. His recovery was incomplete despite pulse intravenous methylprednisolone therapy followed by intravenous immunoglobulin infusion.

Case 7: Anti-Thyroid Peroxidase/Anti-Thyroglobulin Antibody-Related Neurologic Disorder Responsive to Steroids (ATANDS) presenting with myeloneuropathy

A 29-year-old previously healthy female presented with sudden-onset static symmetrical weakness of all 4 limbs and acute retention of urine (catheterized) 1 week back. She also complained of a band-like sensation around her nipple line. Two months ago, when she was feeling tingling and dysesthesias involving both upper and lower limbs in a gloves-stockings pattern, she consulted a physician and was

diagnosed with primary hypothyroidism and put on oral levothyroxine 75 mcg/day alongside calcium/vitamin D3 supplementation, which did not help to relieve her symptoms. For the last month, she felt unsteady while walking through narrow passages. General examination was unremarkable. Neurological examination revealed symmetrical spastic quadriparesis (MRC grade 4/5 in upper limbs and 3+/5 in lower limbs) with bilaterally extensor plantar responses and absent knee and ankle jerks with loss of pain/temperature and crude touch sensations below T4 level and loss of joint position and vibration senses.

A complete blood cell count, renal and liver function tests, serum electrolytes, blood glucose parameters, creatine phosphokinase levels, vitamins B1, B6, B12, D, E, and copper levels were within normal limits. However, an MRI of the spinal cord revealed a contrast-enhanced T2-hyperintense lesion at C5 to D1 level (Fig. 5A, B, C). Nerve conduction studies showed an acquired sensorimotor axonal polyneuropathy (lower limbs more than upper limbs). Anti-thyroid antibodies (anti-TPO, TRAB, anti-TG) were raised in high titers. Other autoimmune, metabolic, toxic, vasculitic, paraneoplastic, and neuroinfectious etiologies were ruled out with relevant tests. She was put on pulse intravenous methylprednisolone therapy (1 g/day for 5 consecutive days), followed by oral prednisolone in tapering doses for the next 3 months with close monitoring. After a week of intravenous methylprednisolone therapy, motor power normalized, but sensory dysesthesias persisted for another 2 months before abatement. At the sixth month of follow-up, she still required 10 mg/day of prednisolone but was utterly free of any neurological deficit.

Case 8: Myeloneuropathy as presenting manifestation of Sjögren syndrome

A 36-year-old female complained of insidious onset, rapidly progressive (now static), intolerable pins-and-needles and burning sensations over her hands and feet, and plaster-cast sensations over bilateral lower limbs for the last 3 months. She had multiple consultations from different specialties and was diagnosed and treated with somatoform/fibromyalgia-

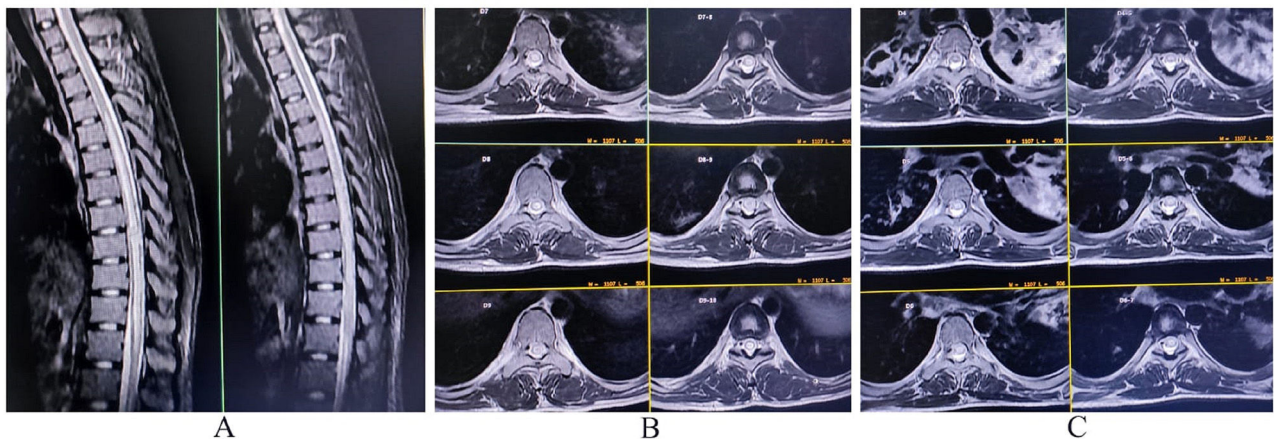


Fig. 4 MRI of the dorsal spine reveals a longitudinally extensive hyperintense lesion on T2-weighted image (A, sagittal, and B and C, axial) extending from D4 to D10 suggestive of long segment myelopathy.

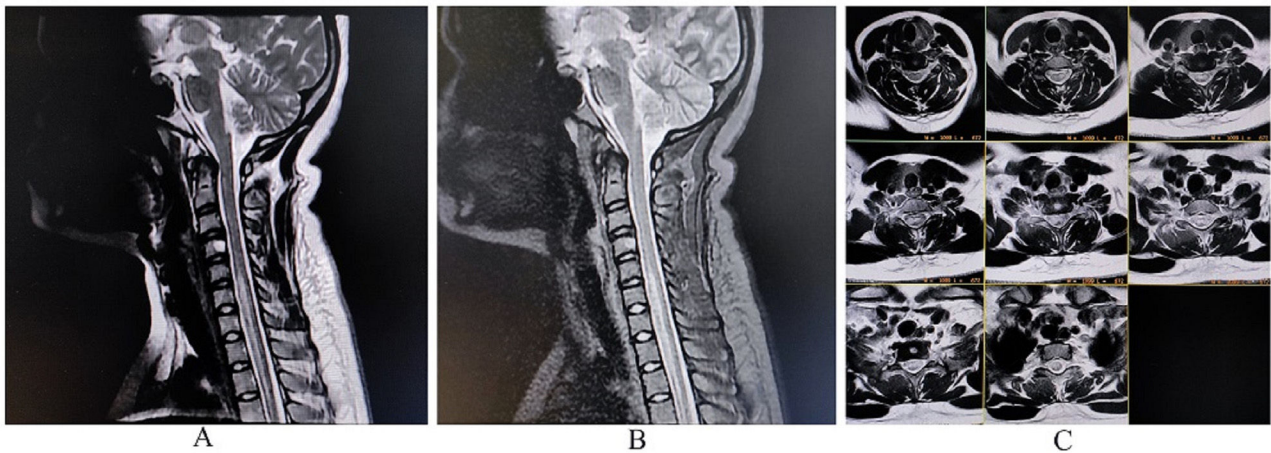


Fig. 5 MRI of the cervical spine reveals a extensive hyperintense lesion on the T2-weighted image and T2-STIR (A and B, sagittal and C, axial) extending from C5 to D1 level with minimal focal cord swelling suggestive of long segment myelopathy.

like syndrome without any symptomatic improvement. She also complained of stiffness in her lower limbs for the last month, occasional involuntary painful spasmodic contractions involving her lower limbs at night, and a sense of unsteadiness while walking. There was a history of urinary urgency and urge incontinence for the last 1–2 months. On further probing, she disclosed that she had been feeling a gritty sensation in her eyes and dry mouth for the last 6–12 months, for which she was having difficulties eating dry foods and had to take sips of water while eating repeatedly.

The general examination was unremarkable except for dryness of mouth and eyes. Neurological examination was normal, but the deep tendon reflexes in the upper limbs were diminished and absent bilaterally in the knees and ankles, with bilateral extensor planter responses. Vibration senses were lost to the spinous process of C7, and joint position senses to the knee in the lower limbs and the elbow in the upper limbs.

A complete blood cell count, hepatic, renal, thyroid, and glucose profiles, electrolytes, serum protein electrophoresis, vitamin B12, folic acid, copper, and vitamin E levels were within normal limits. CSF studies revealed mild lymphocytic pleocytosis (cell count 12, all lymphocytes) with raised protein levels (86 mg/dL). Relevant neuroinfectious agents were ruled out by appropriate testing. Antinuclear antibodies were raised in the titer of 1:100. Anti-Ro and anti-La autoantibodies were strongly positive, but anti-ds DNA and anti-Sm were negative. Rheumatoid factor and anti-cyclic citrullinated peptide were negative. Schirmer's test was positive in both eyes (2 mm/5 min in the right eye and 3 mm/5 min in the left eye). MRI of the spinal cord and brain revealed no significant abnormal signal intensity. However, nerve conduction studies revealed a sensorimotor (sensory more than motor) axonal polyneuropathy with absent F-waves and H-reflexes.

The patient did not give consent for salivary gland biopsy and nerve biopsy. She was treated with IV methylprednisolone 1 g/d for 5 days, followed by oral prednisolone 40 mg/day. She showed improvement in the symptoms after 2 weeks of therapy. Sensory symptoms were reduced

remarkably, and sensory ataxia resolved, but spasticity persisted at the sixth month of follow-up. Symptomatic treatment for sicca symptoms was also started.

Case 9: Chikungunya infection associated with myeloneuropathy

A 25-year-old previously healthy female was admitted to the emergency room with acute onset flaccid quadriparesis associated with acute urinary retention (relieved by Foley's catheterization) and diminished sensation to all modalities below the neck level for the last 4 days. She had a history of hospital admission for high-grade fever, large joint polyarthralgia, and myalgia with rash 5 weeks back, diagnosed as acute chikungunya infection. Family history and personal history were uninformative. The general examination was unremarkable. Neurological examination revealed she had flaccid areflexic symmetric quadriparesis (MRC grade 2 in all muscle groups) with a definite sensory level at T1 with loss of sensations to all modalities below this level. Cognitive functions and cranial nerve examinations were normal.

A complete blood cell count, hepatic, renal, and thyroid function tests, blood glucose indices, serum electrolytes, and lipid profile were normal. MRI of the spinal cord revealed a non-enhancing longitudinally extensive confluent T2-hyperintense lesion involving the cord from the cervical-medullary junction to the D10–D11 region (Fig. 6A, B, C; complete study of dorsal cord has not been included due to poor resolution issues). Brain imaging was normal. Nerve conduction studies revealed an acquired sensorimotor axonal polyneuropathy (lower limbs more than upper limbs). ANA-Hep2, ANA profile, anti-AQP4, and anti-MOG antibodies were negative, as were the vasculitis and paraneoplastic profiles. CSF study revealed lymphocytic pleocytosis with raised protein levels and increased CSF IgG index. Relevant serological testing for neuroviruses panel, SARS-CoV-2, HIV (1, 2), HBV, HCV, and syphilis were negative. She was put on high-dose intravenous bolus methyl-prednisolone therapy (1 g/day for 5 days) followed by oral prednisolone for the next 12 weeks in tapering doses

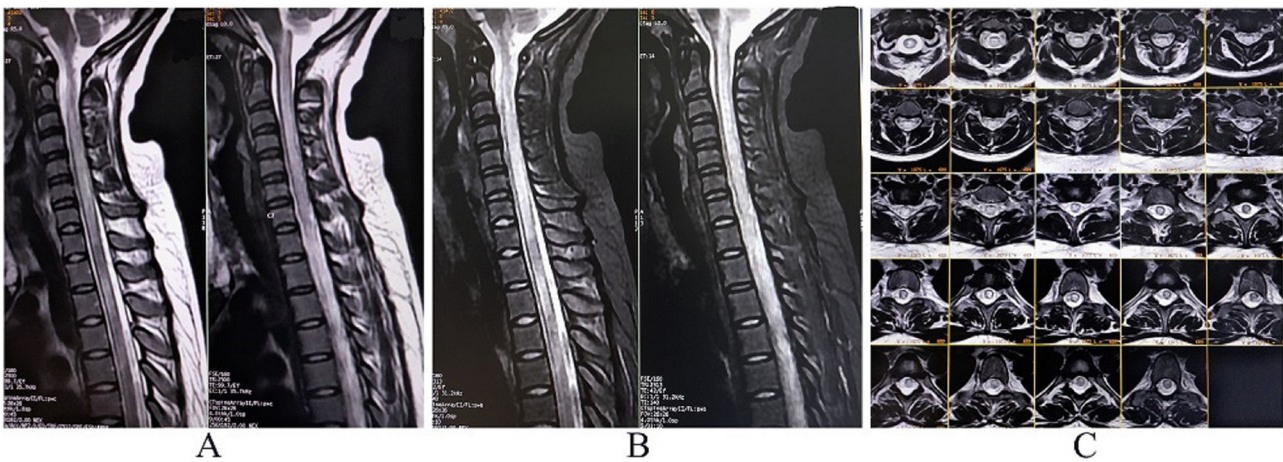


Fig. 6 MRI of the cervical spine reveals a longitudinally extensive hyperintense lesion on the T2-weighted image and T2-STIR (A and B, sagittal, and C, axial) extending from the lower medulla to D5 level suggestive of cervical–dorsal myelopathy.

with monitoring for adverse effects. After 5 days of intravenous methylprednisolone therapy, his motor strength improved to 3+/5 and remained so till the subsequent follow-up at 6 weeks. At the 12th week of follow-up, she was self-ambulatory, but bladder symptoms were persistent (though reduced in intensity).

Case 10: Paraneoplastic myeloneuropathy

A 48-year-old female was admitted to the clinic with subacute-onset gradually progressive asymmetric non-length dependent tingling and paresthesias, stiffness, and intermittent cramps/spasms involving both lower limbs for 3 months. In the last 2 months, she also complained of lightheadedness, postural symptoms, and 3–4 episodes of postural syncope upon standing from a sitting position. She also complained of severe postprandial fullness, nausea, and constipation over the last 3 months. Since last month, she noticed a sense of imbalance, increased stiffness, and occasional tripping while walking, aggravated in the dark

and going downstairs. She also noticed increased urinary urgency, frequency, and intermittent incontinence for the last 4–6 weeks. Her caregivers gave a history of involuntary weight loss for the last 2 months. General examination was remarkable for cachexia, pallor, and left-sided incomplete Horner's syndrome. Neurological examination revealed asymmetric spastic paraparesis (MRC grade 4/5 in the right and 4+/5 in the left lower limb) and bilateral Babinski sign, but lower limb hyporeflexia, with patchy, non-length-dependent sensory loss, and impaired joint position and vibration senses besides autonomic dysfunctions. Cognitive functions, cranial nerves, and cerebellar functions were within normal limits.

A complete blood cell count and metabolic profile were only remarkable for chronic disease anemia and raised erythrocyte sedimentation rate. Biopsy revealed non-small cell lung carcinoma. A chest X-ray revealed a left upper lobe lung mass. MRI of the brain and spinal cord revealed extensive transverse myelitis extending from C4 to D1 level (Fig. 7A, B, C). A nerve conduction study revealed an

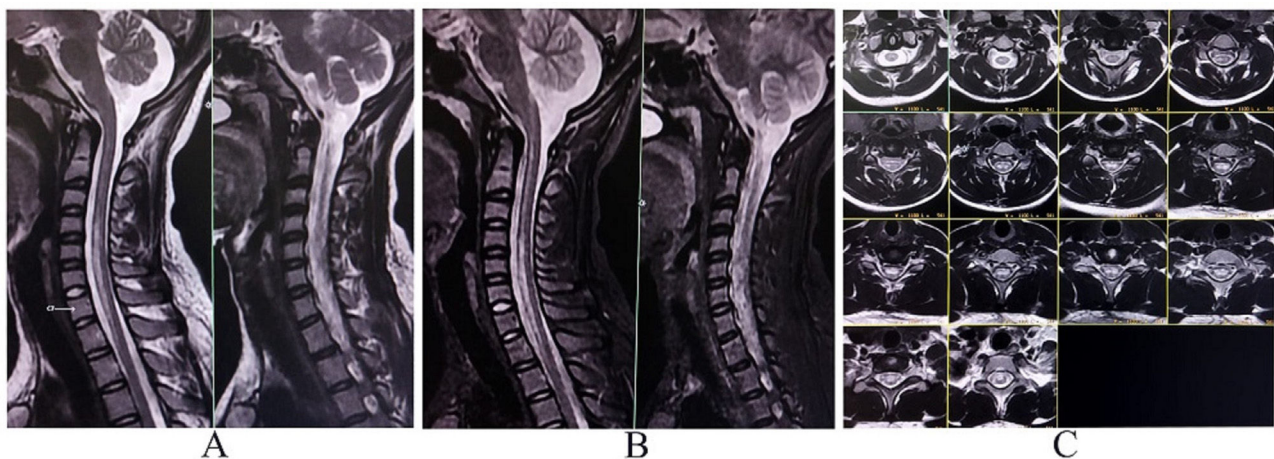


Fig. 7 MRI of the cervical spine reveals a longitudinally extensive hyperintense lesion on T2-weighted and T2-STIR (A and B, sagittal, and C, axial) images extending from C4 to D1 level suggestive of non-compressive myelopathy.

asymmetric sensorimotor axonal neuropathy with sensory ganglionopathy. A contrast-enhanced CT scan of the thorax and abdomen revealed no metastatic lesion. The paraneoplastic profile (serum and CSF) revealed high titers for anti-Ma2 antibody in serum, confirming it to be paraneoplastic myeloneuropathy. The patient and her caregivers refused any further treatment and took the patient home against medical advice (it is not a rare occurrence in Indian rural setups).

Case 11: Hereditary myeloneuropathy

A 36-year-old previously healthy female presented with insidious onset slowly progressive gait unsteadiness for the last 10–12 years. She also noticed slowly progressive bilateral upper limb tremulousness and clumsiness for the last 2 years. She also complained of slowly increasing stiffness, tingling, and paresthesias over both lower limbs. Family history was strongly positive for ataxic disorders. The general examination revealed nothing remarkable except bilateral pes cavus, mild scoliosis, and truncal titubation. Neurological examination revealed normal cognitive abilities, speech, and cranial nerves except saccadic intrusions into smooth pursuit. Motor strength examinations were normal both in the upper and lower limbs. However, the tone was increased in the lower limbs. She also had severely impaired joint position and vibration and decreased pin-prick sensations in the distal lower limbs. All the deep tendon reflexes were brisk except for absent ankle jerks; Babinski's sign was present bilaterally. Nerve conduction studies revealed an acquired sensorimotor axonal polyneuropathy. MRI of the brain was normal, but an MRI of the spinal cord revealed atrophy of the spinal cord. Genetic analysis revealed expansions in both FXN alleles, and she was diagnosed with Friedreich ataxia.

Discussion

Myeloneuropathy heralds overlapping clinical conundrums of both upper and lower motor neuron symptoms and signs most often render the diagnosis difficult. As upper and lower motor neuron symptoms and signs overlap, it is challenging to simultaneously delineate 2 entities in a single patient. Detailed history-taking and careful clinical examination can only pick up the clinical entity, which helps narrow the etiological differentials further to clinch the diagnosis. Historical correlates of peripheral neuropathy (for sensory neuropathy: tingling, burning sensation, and numbness; for motor neuropathy: usually distal predominant segmental weakness and wasting) often subdue the upper motor neuron type of weakness of cord involvement (i.e., myelopathy) unless the history of spasticity is specifically asked and searched. Subtle bladder symptoms are often missed by the clinician if not appraised meticulously.^{1,2}

Furthermore, sensory symptoms due to cord involvement are often difficult to dissect in the presence of neuropathy. Alarming, most often, the symptoms and signs of a single neuro-axis involvement (either upper or lower motor neuron type) are marked, which mainly suppresses the existence of clinically silent second neuraxial involvement. Targeted clinical examinations such as hyporeflexic or areflexic

ankle jerk (a clinical correlate of neuropathy) should be analyzed pragmatically in brisk knee jerk and extensor plantar responses (i.e., upper motor neuron signs). Tract-specific sensory symptoms (i.e., upper motor neuron signs) should not be overlooked as features of neuropathy (i.e., lower motor neuron signs). Subtle bladder symptoms, possibly the only cord symptom, should also be judged carefully. Joint position sense and vibration sense assessment are also essential in the clinical backdrop of suspected myeloneuropathy.^{1,2}

Case 1: The initial presentation of cobalamin deficiency is often myeloneuropathy. Pathological examination reveals macrocytosis, neutrophilic hypersegmentation, and megaloblastic anemia, as in this case. The impairment in the posterior column and lateral spinothalamic tract combined with pyramidal signs and sensory loss are evident in B12 deficiency. Cognitive impairment, orthostatic hypotension, and optic neuropathy are other common features.^{1,2}

Vitamin B12 is mainly stored in the liver. Deficiency of this vitamin affects 1.5%–15% of the population. The associated conditions include malnutrition, atrophic gastritis, deficiency of intrinsic factors, and malabsorption. Of interest is that many patients with B12 deficiency have normal or borderline low cobalamin levels. In these cases, serum methylmalonic acid and homocysteine levels should be checked.^{1,2} In our case, B12 levels were severely low, and methylmalonic acid and homocysteine levels raised.

In many cases, an MRI of the spinal cord reveals T2-weighted signal changes in posterior and lateral columns, which may show enhancement with gadolinium.¹² In our patient, no spinal cord changes were observed in MRI. EMG showed axonal peripheral neuropathy. Vitamin B12 is the treatment of choice for obtaining short-term hematological and neurological responses. Complete hematologic recovery occurs within the first 2 months, whereas neurologic improvement occurs 6–12 months after treatment initiation. Full recovery is not always obtained.^{1,2,11}

Case 2: Copper deficiency is a treatable cause of myeloneuropathy. The neurological manifestations of copper deficiency have previously been described in veterinary literature (swayback in ruminants). The clinical picture may resemble the subacute combined degeneration in vitamin B12 deficiency. Ataxic gait and spasticity due to posterior and lateral column dysfunction are observed. Hypertonia and extensor plantar responses may be present. Hematologic manifestations include megaloblastic anemia and pancytopenia.¹³

Copper deficiency may be caused due to malabsorption, due to bariatric surgery,¹⁴ celiac disease, inflammatory bowel disease, or excess zinc supplementation. The mechanism for the latter is the upregulation of metallothionein expression in intestinal enterocytes. Due to the higher affinity of copper to metallothionein, excess copper is excreted with the feces, causing a copper deficiency.

The diagnosis depends on decreased serum levels of copper and ceruloplasmin, elevated serum zinc levels (commonly due to increased intake), and low urinary copper levels. Limiting zinc intake may be necessary. The treatment involves copper replacement by oral supplementation.^{15,16}

Case 3: Vitamin E, an antioxidant, helps prevent the peroxidation of membrane fatty acids. A deficiency in vitamin E is often associated with various intestinal disorders

such as cholestasis and celiac disease.^{17,18} Vitamin E deficiency may be due to genetic defects. In our case, the patient had Crohn's disease. The neurological manifestations of vitamin E deficiency may include gait abnormalities, impaired vibration sense, decreased tendon reflexes, myopathy, and movement disorders. It is diagnosed by low serum vitamin E levels and treated by oral supplements 800–1200 IU/day. However, correction of vitamin E levels does not constantly improve the clinical symptoms entirely.¹³

Case 4: Organophosphates, common components of pesticides, are known to cause myelopathy and myeloneuropathy, characterized by varied neurological presentations. Chlorpyrifos causes organophosphorus-induced delayed neuropathy (OPIDN). Exposure to high doses and therapeutic intervention to treat acute cholinergic toxicity usually precedes the condition. As much as 22% of organophosphate-poisoning patients are affected by OPIDN, although an earlier study showed that more than half of the affected patients presented with pyramidal illness.^{19,20}

The pathogenesis involves axonal Wallerian degeneration and myelin degeneration of long and large-diameter tracts.²¹ The neurological presentations may be classified into 3 types: (1) cholinergic crisis—due to muscarinic receptor stimulation through the inhibition of acetylcholinesterase; (2) intermediate syndrome—featuring muscular weakness predominantly affecting the proximal muscles and neck flexors²²; and (3) organophosphate-induced delayed neuropathy—pure or predominantly motor axonal neuropathy with wrist drop or foot drop with no sensory loss.²³

Neuropathy target esterase is an enzyme implicated in the pathophysiology of organophosphorus-induced myeloneuropathy; phosphorylation inhibits this enzyme and causes axonal degeneration. Chlorpyrifos hastens this mechanism. The prognosis depends on the degree of axonal damage.²⁴

Case 5: Chronic alcohol abuse can cause a range of neurological symptoms. Alcohol-induced peripheral neuropathy slowly progresses over months to years, and the patient usually presents with paresthesia, numbness, and impaired vibration senses. Painful neuropathies like our case are also reported, albeit rarely (a prevalence of 42%).²⁵ Lower limbs are more affected than upper limbs, and sensory and motor nerves are involved. Other than alcohol intake, the risk factors are sex (male preponderance),²⁵ genetics and family history,^{26,27} types of alcohol consumed (wine drinkers having worse dysfunction than beer), malnutrition, and hepatic dysfunction.²⁸ A few studies have also implicated the roles of inflammatory cytokines and oxidative stress.^{29,30} The treatment involves abstinence from alcohol and consuming a normal diet,³¹ and vitamin supplementation.³²

Case 6: Heroin use selectively involves the spinal cord's ventral pons and posterior and lateral columns. Myelopathy is known to be associated with it. An acute episode of myelopathy can result from a single use of heroin preceded by a period of abstinence—similar to our case—pointing toward the role of an immune-mediated mechanism at play. Other contributing mechanisms possibly include vasculitis, hypotension, and direct toxicity.¹⁸ The patients often experience paraplegia with lower extremity sensory loss

and urinary retention. The cervical segments may also be involved.³³

MRI is often normal, although in our case, a longitudinally extensive spinal cord lesion was detected in the spinal cord MRI. T2-weighted and FLAIR imaging often shows hyperintense lesions in the pontomedullary regions, ventral pons, and posterior and lateral columns. Pleocytosis with elevated protein levels may be observed in CSF examination.³⁴ Treatment is supportive, with a poor prognosis. Patients usually do not recover completely, as in our case. Residual spastic paraparesis and sensory deficits are common. IV corticosteroids or plasma exchange therapy are not effective.³⁵

Case 7: Myeloneuropathy in ATANDS is rare. Anti-thyroid antibodies characterize it, probably taking part in the disease pathogenesis through vasculitis.³⁶ There are only a few cases of thyroiditis and myeloneuropathy. In these cases, spinal MRI showed intramedullary high-intensity signals on T2-weighted imaging with gadolinium enhancement. Our patient had ATANDS, markedly increased anti-thyroid antibodies, and a clinical picture suggested myelopathy with peripheral neuropathy. The latter was probably related to hypothyroidism. The diagnosis of myeloneuropathy in ATANDS requires a high degree of suspicion and is often made after excluding other causes. Toxic and hereditary neuropathy were ruled out from exposure and family history. The high titers of anti-TPO and anti-TG antibodies and prompt response to steroid therapy sealed the diagnosis. Possible other autoimmune etiology should be suspected, and periodic autoimmune parameters should be checked with autoimmune thyroid disease.^{2,37–39}

Case 8: Sjögren syndrome is an autoimmune disease characterized by xerophthalmia, xerostomia, and a range of neurologic and systemic disorders, including peripheral neuropathy. Different types of neuropathy observed in Sjögren syndrome include ataxic neuropathy, painful sensory neuropathy, autonomic neuropathy, and radiculoneuropathy, among others. In our patient, sensorimotor axonal polyneuropathy was observed. Neuropathy in Sjögren syndrome is associated with chronic vasculitis of epineural arterioles and small vessel perivascular lymphocytic infiltration, as observed in biopsy and necropsy studies. These pathogenic mechanisms may also be shared in Sjögren syndrome myelopathy.⁴⁰

The diagnosis is challenging, especially when the patient presents with neurologic symptoms. According to The San Diego and European classification criteria, objective evidence of exocrine impairment, positive autoantibodies, and characteristic biopsy findings of the salivary gland are required. The Schirmer test and rose bengal staining can demonstrate xerophthalmia. Salivary scintiscanning can establish xerostomia. Biopsy from the salivary gland typically shows lymphocytic infiltrates with acinar tissue atrophy. We could not, however, do a salivary gland biopsy due to non-consent from the patient. Anti-Ro and anti-La antibodies are typically elevated in these patients. Therapeutics include immunomodulators, corticosteroids, intravenous immunoglobulins, and plasma exchange. Corticosteroids are effective in multiple mononeuropathies, while sensory neuropathy and radiculoneuropathy respond better to intravenous immunoglobulin. Myelopathy is known

to respond well to a combination of corticosteroids and cyclophosphamide.^{41,42}

Case 9: The neurologic symptom most commonly associated with Chikungunya viral infection is encephalopathy, although peripheral nervous system involvement has also been reported.^{43,44} Our patient had myeloneuropathy 5 weeks after a diagnosis of chikungunya. Several cases have been described in the literature where a temporal pattern is observed for the appearance of myeloneuropathy, ranging between 0 and 6 weeks post-infection.^{1,45,46} The pathogenesis of myeloneuropathy in chikungunya, although unclear, is implied to be immune-mediated. Immune complex deposition, molecular mimicry, and polyclonal B/T-cell activation are some of the mechanisms thought to be underlying the condition.⁴⁷

Imaging findings are non-specific and varied. Autoimmune and paraneoplastic etiologies, as well as neuromyelitis optica and MOG-associated myelitis, important differential diagnoses, in this case, were ruled out. We treated the patient with intravenous methylprednisolone and oral therapy for 12 weeks. The incomplete recovery may be due to the extensive involvement of the spinal cord.

Case 10: Paraneoplastic syndrome occurs in patients having an underlying malignancy, triggering an immune response. The signs and symptoms may appear after the cancer is well-established, the patient is in remission, or even before the cancer is diagnosed. It rarely manifests into paraneoplastic myeloneuropathy, where the symptoms subacutely develop over weeks to months. The patient may have a history of smoking or a family history of malignancy. Any neurologic manifestations, such as ataxia, chorea, limbic encephalitis, peripheral neuropathy, and autonomic neuropathy, may implicate a paraneoplastic etiology. Often, an elevated paraneoplastic antibody, e.g., antineuronal nuclear antibody 1 (anti-Hu) (most common), amphiphysin, glutamate decarboxylase 65, and Purkinje cell antibody type 2, supports the etiology.⁴⁸ In our case, an elevated anti-Ma2 onconeural antibody was found, pointing toward the involvement of the limbic system and brainstem.⁴⁹

Paraneoplastic myeloneuropathy may be sensorimotor or sensory and sometimes demyelinating. The next step is identifying an occult malignancy after establishing a paraneoplastic origin. Intravenous immunoglobulin and methylprednisolone are the treatments in patients without an identifiable neoplasm.²

Case 11: Various hereditary myeloneuropathies have been reported, including adrenomyeloneuropathy,⁵⁰ cerebrotendinous xanthomatosis, and hereditary spastic paraplegia.² Family history is crucial in these cases. Adrenomyeloneuropathy, the commonly observed variant of hereditary myeloneuropathy, affects the descending corticospinal tracts and posterior columns. The patient presents with slowly progressive spastic paraparesis and mild polyneuropathy without sensory involvement. Previously, symmetrical, sensorimotor peripheral neuropathy has been described in Friedrich's ataxia. The patient had severe truncal ataxia, stiffness, dysarthria, and distal muscle wasting. MRI revealed cerebral and cerebellar (mild) atrophy, pontine and medullary volume loss, and a normal spinal cord. However, no cognitive decline was observed in our patient, unlike in the previous case. Gene analysis

revealed GAA repeats in both alleles of the frataxin gene, as was observed in our case.⁵¹

Conclusion

Diseases concomitantly involving the spinal cord and peripheral nerves can be defined as myeloneuropathies. This article outlines a rendezvous of 11 rare cases of myeloneuropathy with different etiological backgrounds and therapeutic approaches. Because these disorders may present with prominent myelopathic or peripheral neuropathic signs and symptoms, a meticulous historical analysis, careful clinical examination, and apposite utilization and interpretation of biochemical, electrophysiological, and neuroimaging findings are warranted an accurate and consistent approach to evaluating a suspected case of myeloneuropathy, facilitating early treatment and recovery. Differential identification of these disorders needs an in-depth perception of the mode of onset of symptoms, the course of progression of the disease, the pattern of myelopathic/neuropathic findings, and recognition of other neurological or systemic manifestations. For untroubled understanding, etiologies of myeloneuropathies should be subdivided into a few broad subcategories, e.g., metabolic (nutritional), toxic (toxin-induced), infectious, inflammatory (immune-mediated), paraneoplastic, and hereditary disorders.

Study funding

Nil.

Patients consent

Written informed consent was obtained from the patients to publish these case reports and any accompanying images.

Author contributions

All authors contributed significantly to the creation of this manuscript; each fulfilled criterion as established by the ICMJE.

Declaration of Competing Interest

Dr. Ritwik Ghosh (ritwikmed2014@gmail.com) reports no conflict of interest.

Dr. Dipayan Roy (dipayan.1993@yahoo.in) reports no conflict of interest.

Dr. Arpan Mandal (arpan0602@gmail.com) reports no conflict of interest.

Dr. Moisés León-Ruiz (pistolpete271285@hotmail.com) reports no conflict of interest.

Dr. Shambaditya Das (drshambadityadas@gmail.com) reports no conflict of interest.

Dr. Souvik Dubey (drsouvik79@gmail.com) reports no relevant disclosures.

Dr. Arijeet Jana (arijeet.jana.009@gmail.com) reports no relevant disclosures.

Dr. Siktha Purkait (sikthapurkait@gmail.com) reports no relevant disclosures.

Dr. Tapas Ghosh (dr.ghoshtapas@gmail.com) reports no relevant disclosures.

Dr. Julián Benito-León (jbenitol67@gmail.com) reports no relevant disclosures.

Acknowledgments

J. Benito-León is supported by the National Institutes of Health, Bethesda, MD, USA (NINDS #R01 NS39422), the European Commission (grant ICT-2011-287739, NeuroTREMOR), the Ministry of Economy and Competitiveness (grant RTC-2015-3967-1, NetMD—platform for the tracking of movement disorder), and the Spanish Health Research Agency (grant FIS PI12/01602 and grant FIS PI16/00451).

References

- Garg RK, Malhotra HS, Kumar N. Approach to a case of myeloneuropathy. *Ann Indian Acad Neurol*. 2016;19:183–7. <https://doi.org/10.4103/0972-2327.182303>.
- Goodman BP. Diagnostic approach to myeloneuropathy. *Continuum (Minneapolis, Minn.)*. 2011;17:744–60. <https://doi.org/10.1212/01.CON.0000403793.13291.f3>.
- Herrera Herrera I, Garrido Morro I, Guzmán de Villoria Lebedziejewski J, Ordoñez González C, Rovira A. Clinical-radiological approach to nontraumatic myelopathy. *Radiologia (Engl Ed)*. 2020;62:464–80. <https://doi.org/10.1016/j.rx.2020.07.004>.
- Burakgazi AZ, Alsowaity B, Burakgazi ZA, Unal D, Kelly JJ. Bladder dysfunction in peripheral neuropathies. *Muscle Nerve*. 2012;45:2–8. <https://doi.org/10.1002/mus.22178>.
- Watson JC, Dyck PJ. Peripheral neuropathy: a practical approach to diagnosis and symptom management. *Mayo Clin Proc*. 2015;90:940–51. <https://doi.org/10.1016/j.mayocp.2015.05.004>.
- Ghosh R, Das S, De K, Dubey S, Benito-León J. Magnetic resonance imaging-negative myeloneuropathy and bilateral facial paresis unfurling systemic lupus erythematosus. *Qatar Med J*. 2022;2022:42. <https://doi.org/10.5339/qmj.2022.42>.
- Bhai S, Bhattacharyya S. Myelopathy: a clinical approach. *Semin Neurol*. 2021;41:221–6. <https://doi.org/10.1055/s-0041-1725145>.
- Cho TA, Bhattacharyya S. Approach to myelopathy. *Continuum (Minneapolis, Minn.)*. 2018;24(2, Spinal Cord Disorders):386–406. <https://doi.org/10.1212/CON.0000000000000583>.
- Fink JK. Hereditary myelopathies. *Continuum (N Y)*. 2008;14:58. <https://doi.org/10.1212/01.con.0000324124.55065.09>.
- Goodman BP, Bosch EP, Ross MA, Hoffman-Snyder C, Dodick DD, Smith BE. Clinical and electrodiagnostic findings in copper deficiency myeloneuropathy. *J Neurol Neurosurg Psychiatry*. 2009;80:524–7. <https://doi.org/10.1136/jnnp.2008.144683>.
- Butler CC, Vidal-Alaball J, Cannings-John R, McCaddon A, Hood K, Papaioannou A, et al. Oral vitamin B12 versus intramuscular vitamin B12 for vitamin B12 deficiency: a systematic review of randomized controlled trials. *Fam Pract*. 2006;23:279–85. <https://doi.org/10.1093/fampra/cml008>.
- Ravina B, Loevner LA, Bank W. MR findings in subacute combined degeneration of the spinal cord: a case of reversible cervical myelopathy. *AJR Am J Roentgenol*. 2000;174:863–5. <https://doi.org/10.2214/ajr.174.3.1740863>.
- Schwendimann RN. Metabolic, nutritional, and toxic myelopathies. *Neurol Clin*. 2013;31:207–18. <https://doi.org/10.1016/j.ncl.2012.09.002>.
- Jolobe OM. Copper deficiency and myelopathy after bariatric surgery. *J R Coll Physicians Edinb*. 2018;48:92. <https://doi.org/10.4997/JRCPE.2018.120>.
- Rowin J, Lewis SL. Copper deficiency myeloneuropathy and pancytopenia secondary to overuse of zinc supplementation. *J Neurol Neurosurg Psychiatry*. 2005;76:750–1. <https://doi.org/10.1136/jnnp.2004.046987>.
- Spinazzi M, De Lazzari F, Tavolato B, Angelini C, Manara R, Armani M. Myelo-optico-neuropathy in copper deficiency occurring after partial gastrectomy. Do small bowel bacterial overgrowth syndrome and occult zinc ingestion tip the balance? *J Neurol*. 2007;254:1012–7. <https://doi.org/10.1007/s00415-006-0479-2>.
- Hedera P. Hereditary and metabolic myelopathies. *Handb Clin Neurol*. 2016;136:769–85. <https://doi.org/10.1016/B978-0-444-53486-6.00038-7>.
- Riva N, Riva N, Morana P, Cerri F, Gerevini S, Amadio S, et al. Acute myelopathy selectively involving lumbar anterior horns following intranasal insufflation of ecstasy and heroin. *BMJ Case Rep*. 2009;2009. <https://doi.org/10.1136/bcr.08.2008.0669>.
- Aygun D, Doganay Z, Altintop L, Guven H, Onar M, Deniz T, et al. Serum acetylcholinesterase and prognosis of acute organophosphate poisoning. *J Toxicol Clin Toxicol*. 2002;40:903–10. <https://doi.org/10.1081/clt-120016962>.
- Senanayake N. Tri-cresyl phosphate neuropathy in Sri Lanka: a clinical and neurophysiological study with a three year follow up. *J Neurol Neurosurg Psychiatry*. 1981;44:775–80. <https://doi.org/10.1136/jnnp.44.9.775>.
- Nayak P, Mallick AK, Mishra S, Panigrahy D. Organophosphorus-induced toxic myeloneuropathy: series of three adolescent patients with short review. *J Pediatr Neurosci*. 2019;14:42–5. https://doi.org/10.4103/jpn.JPN_45_18.
- Samuel J, Thomas K, Jeyaseelan L, Peter JV, Cherian AM. Incidence of intermediate syndrome in organophosphorus poisoning. *J Assoc Physicians India*. 1995;43:321–3.
- Chatterjee M, Sarma PS. Unusual neurological complications in a case of organophosphate poisoning. *Neurol India*. 2003;51:290–1.
- Julian T, Glasgow N, Syeed R, Zis P. Alcohol-related peripheral neuropathy: a systematic review and meta-analysis. *J Neurol*. 2019;266:2907–19. <https://doi.org/10.1007/s00415-018-9123-1>.
- Agelink MW, Malessa R, Weisser U, Lemmer W, Zeit T, Majewski T, et al. Alcoholism, peripheral neuropathy (PNP) and cardiovascular autonomic neuropathy (CAN). *J Neurol Sci*. 1998;161:135–42. [https://doi.org/10.1016/S0022-510X\(98\)00266-4](https://doi.org/10.1016/S0022-510X(98)00266-4).
- Ammendola A, Tata MR, Aurilio C, Ciccone G, Gemini D, Ammendola E, et al. Peripheral neuropathy in chronic alcoholism: a retrospective cross-sectional study in 76 subjects. *Alcohol Alcohol*. 2001;36:271–5. <https://doi.org/10.1093/alcalc/36.3.271>.
- Masaki T, Mochizuki H, Matsushita S, Yokoyama A, Kamakura K, et al. Association of aldehyde dehydrogenase-2 polymorphism with alcoholic polyneuropathy in humans. *Neurosci Lett*. 2004;363:288–90. <https://doi.org/10.1016/j.neulet.2004.04.009>.
- Vittadini G, Buonocore M, Colli G, Terzi M, Fonte R, Biscaldi G. Alcoholic polyneuropathy: a clinical and epidemiological study. *Alcohol Alcohol*. 2001;36:393–400. <https://doi.org/10.1093/alcalc/36.5.393>.
- Michałowska-Wender G, Adamcewicz G, Wender M. Impact of cytokines on the pathomechanism of diabetic and alcoholic neuropathies. *Folia Neuropathol*. 2007;45:78–81.
- Haslbeck KM, Schleicher ED, Friess U, Kirchner A, Neundörfer B, Heuss D. N(epsilon)-carboxymethyllysine in diabetic and non-diabetic polyneuropathies. *Acta Neuropathol*. 2002;104:45–52. <https://doi.org/10.1007/s00401-002-0518-8>.
- Hawley RJ, Kurtzke JF, Armbrustmacher VW, Saini N, Manz H. The course of alcoholic-nutritional peripheral neuropathy. *Acta*

- Neurol Scand. 1982;66:582–9. <https://doi.org/10.1111/j.1600-0404.1982.tb03146.x>.
32. Peters TJ, Kotowicz J, Nyka W, Kozubski W, Kuznetsov V, Vanderbist F, de Niet S, Marcereuil D, Coffiner M. Treatment of alcoholic polyneuropathy with vitamin B complex: a randomised controlled trial. *Alcohol*. 2006;41:636–42. <https://doi.org/10.1093/alcalc/agl058>.
33. McCreary M, Emerman C, Hanna J, Simon J. Acute myelopathy following intranasal insufflation of heroin: a case report. *Neurology*. 2000;55:316–7. <https://doi.org/10.1212/wnl.55.2.316-a>.
34. Ramalho J, Nunes RH, da Rocha AJ, Castillo M. Toxic and metabolic myelopathies. *Semin Ultrasound CT MR*. 2016;37:448–65. <https://doi.org/10.1053/j.sult.2016.05.010>.
35. van Dijkman SC, de Jager NCB, Rauwé WM, Danhof M, Della Pasqua O. Effect of age-related factors on the pharmacokinetics of lamotrigine and potential implications for maintenance dose optimisation in future clinical trials. *Clin Pharmacokinet*. 2018 (57):1039–53. <https://doi.org/10.1007/s40262-017-0614-5> Erratum in: *Clin Pharmacokinet* 2018 Apr 25.
36. Nolte KW, Unbehau A, Sieker H, Kloss TM, Paulus W. Hashimoto encephalopathy: a brainstem vasculitis? *Neurology*. 2000;54:769–70. <https://doi.org/10.1212/wnl.54.3.769>.
37. Kayal AK, Basumatary LJ, Dutta S, Mahanta N, Islam S, Mahanta A. Myeloneuropathy in a case of Hashimoto's disease. *Neurol India*. 2013;61:426–8. <https://doi.org/10.4103/0028-3886.117591>.
38. Azuma T, Uemichi T, Funauchi M, Doi S, Matsubara T. Myelopathy associated with Hashimoto's disease. *J Neurol Neurosurg Psychiatry*. 2000;68:681–2. <https://doi.org/10.1136/jnnp.68.5.681>.
39. Ishizawa K, Tomioka R, Nakazato Y, Araki N. Isolated myelopathy probably associated with Hashimoto's disease. *Neurol India*. 2012;60:235–6. <https://doi.org/10.4103/0028-3886.96418>.
40. Mori K, Iijima M, Koike H, Hattori N, Tanaka F, Watanabe H, et al. The wide spectrum of clinical manifestations in Sjögren's syndrome-associated neuropathy. *Brain*. 2005;128(Pt 11):2518–34. <https://doi.org/10.1093/brain/awh605>.
41. de Seze J, Delalande S, Fauchais AL, Hachulla E, Stojkovic T, Ferriby D, et al. Myelopathies secondary to Sjögren's syndrome: treatment with monthly intravenous cyclophosphamide associated with corticosteroids. *J Rheumatol*. 2006;33:709–11.
42. Williams CS, Butler E, Román GC. Treatment of myelopathy in Sjögren syndrome with a combination of prednisone and cyclophosphamide. *Arch Neurol*. 2001;58:815–9. <https://doi.org/10.1001/archneur.58.5.815>.
43. Bank AM, Batra A, Colorado RA, Lyons JL. Myeloradiculopathy associated with chikungunya virus infection. *J Neurovirol*. 2016;22:125–8. <https://doi.org/10.1007/s13365-015-0372-9>.
44. Mehta R, Gerardin P, de Brito CAA, Soares CN, Ferreira MLB, Solomon T. The neurological complications of chikungunya virus: a systematic review. *Rev Med Virol*. 2018;28, e1978. <https://doi.org/10.1002/rmv.1978>.
45. Patwardhan A, Nalini A, Baishya PP, Kulanthaivelu K, Krishnareddy H, Dutta D, et al. Case report: post-Chikungunya-associated myeloneuropathy. *Am J Trop Med Hyg*. 2021;105:942–5. <https://doi.org/10.4269/ajtmh.20-1277>.
46. Chandak NH, Kashyap RS, Kabra D, Karandikar P, Saha SS, Morey SH, et al. Neurological complications of Chikungunya virus infection. *Neurol India*. 2009;57:177–80. <https://doi.org/10.4103/0028-3886.51289>.
47. Bank AM, Batra A, Colorado RA, Lyons JL. Myeloradiculopathy associated with chikungunya virus infection. *J Neurovirol*. 2016;22:125–8. <https://doi.org/10.1007/s13365-015-0372-9>.
48. Graber JJ, Nolan CP. Myelopathies in patients with cancer. *Arch Neurol*. 2010;67:298–304. <https://doi.org/10.1001/archneurol.2010.20>.
49. Ortega Suero G, Sola-Valls N, Escudero D, Saiz A, Graus F. Anti-Ma and anti-Ma2-associated paraneoplastic neurological syndromes. *Neurologia (Engl Ed)*. 2018;33:18–27. <https://doi.org/10.1016/j.nrl.2016.05.010>.
50. Chafale VA, Lahoti SA, Biswas A, Roy A, Senapati AK. Adrenomyeloneuropathy with bulbar palsy: a rare association. *Ann Indian Acad Neurol*. 2014;17:361–3. <https://doi.org/10.4103/0972-2327.138530>.
51. Vidhale TA, Gupta HR, Pj R, Gandhi C. Very late-onset Friedreich's ataxia with rapid course mimicking as possible multiple system atrophy cerebellar type. *BMJ Case Rep*. 2021;14, e242073. <https://doi.org/10.1136/bcr-2021-242073>.