

IMAGE OF THE MONTH

Paraneoplastic cerebellar degeneration and anti-Yo antibodies

Degeneración cerebelosa paraneoplásica y anticuerpos anti-Yo

L. Bataller, ^{a,b,*} E. Fages, ^{c,e} C. Alberola ^d

^aServicio de Neurología, Hospital Universitario La Fe, Valencia, Spain

^bLaboratorio de Neurología Experimental, Centro de Investigación, Hospital Universitario La Fe; Valencia, Spain and Centro de Investigación Biomédica en Red sobre Enfermedades Neurodegenerativas (CIBERNED)

^cServicio de Neurología, Hospital Santa Maria del Rosell, Cartagena, Murcia, Spain

^dServicio de Anatomía Patológica, Hospital Universitario La Fe, Valencia, Spain

^eE. Fages was working at the Servicio de Neurología, Hospital Universitario la Fe, Valencia, Spain, when this paper was written

Received on 8th March 2008; accepted on 21st December 2010

A 61-year-old female developed a rapidly progressive paraneoplastic cerebellar syndrome. During the initial assessment, which included a brain magnetic resonance scan and examination of the cerebrospinal fluid (CSF), the studies were negative. The study using immunofluorescence of the patient's serum and the patient's CSF with sections of rat cerebellum showed reactivity to Purkinje cell cytoplasm and molecular layer neurons (fig. 1, panel A). The study using immunoblot with protein extracts of rat cerebellum showed specific reactivity against 62-kilodalton (kDa) and 34-kDa antigens, characteristic of anti-Yo¹ antibodies (fig. 1, panel B). The coincidence of a subacute cerebellar syndrome and well-characterised onconeural antibodies (such as anti-Yo antibodies) is diagnostic of paraneoplastic neurological syndrome.² As the conventional imaging studies were negative, we performed a whole-body fluorodeoxyglucose positron emission tomography which showed hyperenhanced lesion in the right axillary region (fig. 1, panel C). Its

histopathological study showed an infiltrating ductal breast adenocarcinoma. Despite treatment with high doses of intravenous immunoglobulin together with tumour treatment (surgery, radiotherapy and chemotherapy), the patient evolved unfavourably from the neurological point of view and died within 6 months as a consequence of complications derived from being bedridden. The histopathological study of the brain during the autopsy showed a nearly complete loss of Purkinje cells, together with reactive astrogliosis and presence of torpedoes corresponding to abnormal axons of surviving Purkinje cells (fig. 1, panel D). Hardly any lymphocytic perivascular infiltrates were seen.

The cerebellum is a frequent target of autoimmunity against central nervous system proteins in patients with systemic cancer. As in the case of our patient, the prognosis of this process is often fatal.³

Partially financed through the grant FIS PI06/080410.

* Corresponding author.

E-mail: l_bataller@yahoo.com (L. Bataller).

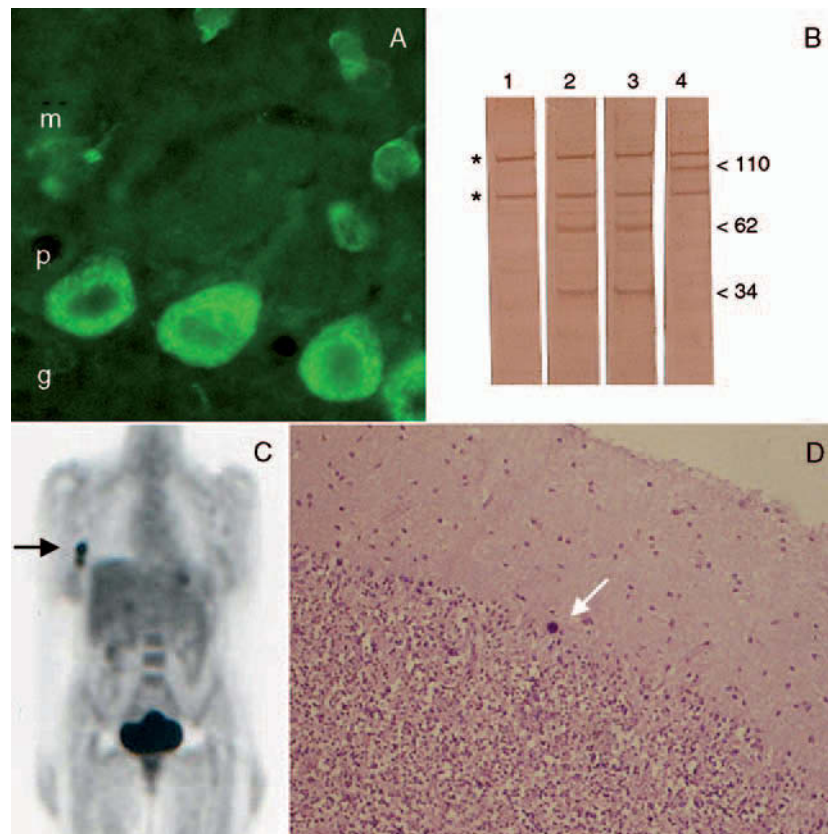


Figure 1 A) Cerebellar section of a rat incubated with the patient's serum, diluted 1:250, and developed by immunofluorescence (M: molecular layer; P: Purkinje cell layer; G: granular layer) (x400). B) Immunoblot of rat cerebellum extracts incubated with serum (1:500) of 1) healthy control; 2) current patient; 3) control patient with anti-Yo antibodies (courtesy of Dr Francesc Graus); and 4) another patient with subacute cerebellar degeneration not cancer-associated and antibodies against an unknown 110-kDa protein. The asterisks indicate non-specific reactivity. C) Whole-body fluorodeoxyglucose positron emission tomography. D) Cerebellar section of the patient's autopsy stained with haematoxylin-eosin. The arrow indicates the presence of a torpedo (x100).

References

1. Furneaux HM, Rosenblum MK, Dalmau J, Wong E, Woodruff P, Graus F, et al. Selective expression of Purkinje-cell antigens in tumor tissue from patients with paraneoplastic cerebellar degeneration. *N Engl J Med.* 1990;322:1844-51.
2. Graus F, Delattre JY, Antoine JC, Dalmau J, Giometto B, Grisold W, et al. Recommended diagnostic criteria for paraneoplastic neurological syndromes. *J Neurol Neurosurg Psychiatry.* 2004;75:1135-40.
3. Rojas I, Graus F, Keime-Guibert F, Reñé R, Delattre JY, Ramón JM, et al. Long term clinical outcome of paraneoplastic cerebellar degeneration and anti-Yo antibodies. *Neurology.* 2000;55:713-5.