

## Symptomatic carotidynia: neck pain of vascular origin<sup>\*</sup>

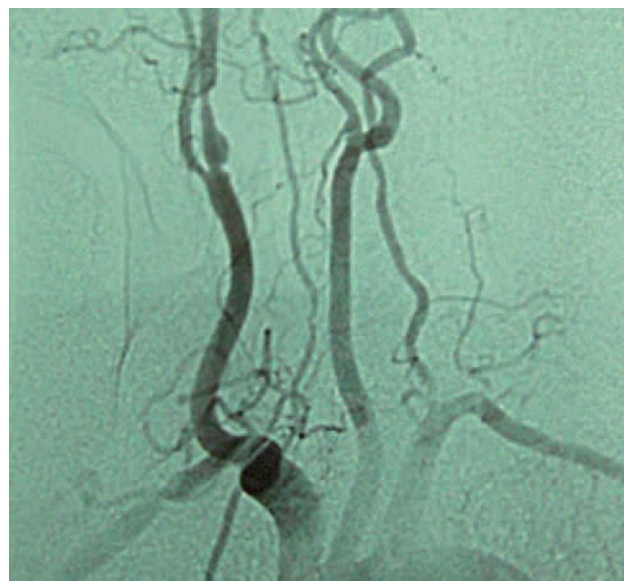
### Carotidinia sintomática: dolor cervical de origen vascular

Dear Editor:

We present the case of a 71-year old female, diabetic, hypertensive, dyslipidaemic and with a history of ischaemic heart disease. Over the course of the 7 months preceding the initial visit, she had presented several episodes of pulsing pain on the right side of the neck that radiated to the region of the ear, with oedema and tenderness on palpation in the area. Each episode lasted for less than 2 weeks. She had not presented any cerebral or retinal ischaemic event. A carotid murmur on the right hand side was the outstanding finding on examination. Both the laboratory analyses (haemogram, biochemistry coagulation, PCR, ESR) and MRI were normal. The Doppler examination of the carotid revealed a critical stenosis of more than 90% of the right carotid artery one centimetre from the bifurcation, confirmed by arteriography (fig. 1). Treatment consisted of angioplasty with stent placement, leaving the patient asymptomatic with respect to the pain she had suffered on the side of her neck.

Carotidynia is considered a syndrome that covers numerous variants of pain in the carotid region. It was first described by Fay in 1927.<sup>1,2</sup> It has been eliminated as an entity from the second version of the International Classification of Headache Disorders (ICHD-II) to be contemplated in the Appendix more as a syndrome that may be the result of numerous causes.<sup>2,3</sup> It refers to continuous or intermittent pain in the side of the neck located in the region of the carotid artery, sometimes radiating to the ipsilateral region of the face and/or ear. It can be aggravated by neck movements, swallowing or coughing. It is an uncommon cause of neck pain.<sup>2,4</sup> It has been related to various processes such as dissection, thrombosis, fibromuscular dysplasia, aneurysm, giant cell arteritis or Takayasu's arteritis, as well as other non-vascular processes such as lymphoedemas, sialadenitis, peritonsillar abscesses, or neck neoplasms, among others.<sup>5</sup> The causes of the neck pain must be determined, since these conditions must always be excluded before positing the alternative diagnosis of idiopathic carotidynia and establishing appropriate treatment. Although there are no long series of idiopathic carotidynia correlating histology with imaging studies, it does appear to be mediated by an immune response involving T cells, antigen-presenting cells, and macrophages that produce changes in the wall of the artery and that can be seen on both MRI or angio-MRI scans as circumferential or eccentric enhancement of the arterial wall with preserved lumen. This appears to translate into peri-adventitial thickening as a chronic inflammatory response and may respond to steroid treatment.<sup>2,4,6</sup>

We report a case of symptomatic carotidynia, related to critical stenosis of the internal carotid artery, that resolved once the cause was treated. This case can serve to illustrate



**Figure 1** Atheromatous plaque in the right primitive carotid, before the bifurcation, that extends to the internal carotid, producing significant stenosis at the level of the ostium and severe stenosis at the postbulbar level of regular morphology.

that tests such as ultrasound or NMR are of great use in confirming the diagnosis and, in this way, being able to apply the appropriate treatment, without losing sight of the existence of other cases of idiopathic carotidynia.

## References

1. Taniguchi Y, Horino T, Hashimoto K. Is carotidynia syndrome a subset of vasculitis? *J Rheumatol.* 2008;35:1901-2.
2. Kosaka N, Sagoh T, Uematsu H, Kimura H, Miyayama S, Noguchi M, et al. Imaging by multiple modalities of patients with a carotidynia syndrome. *Eur Radiol.* 2007;17:2430-3.
3. Woo JK, Jhamb A, Heran MK, Hurley M, Graeb D. Resolution of existing intimal plaque in a patient with carotidynia. *Am J Neuroradiol.* 2008;29:732-3.
4. Azar L, Fischer HD. Perivascular carotid inflammation: an unusual case of carotidynia. *Rheumatol Int.* 2009; 20. Available at: <http://www.springerlink.com/content/146657h306708584/fulltext.pdf> [2.11.10]
5. Da Rocha AJ, Tokura EH, Romualdo AP, Fatio M, Gama HP. Imaging contribution for the diagnosis of carotidynia. *J Headache Pain.* 2009;10:125-7.
6. Kang Park JK, Choi JC, Kim BS, Choi G, Kim SH. CT imaging features of carotidynia: a case report. *J Neuroimaging.* 2009;19:84-5.

A. Castrillo Sanz, \* A. Mendoza Rodríguez, C. Gil Polo, R. Gutiérrez Ríos

Sección de Neurología, Complejo Asistencial de Segovia, Segovia, Spain

\* Corresponding author.

E-mail: anacastillosanz@yahoo.es (A. Castrillo Sanz).

<sup>\*</sup>This paper was presented as a poster at the annual meeting of the Spanish Society of Neurology in 2010.