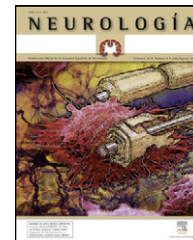




NEUROLOGÍA

www.elsevier.es/neurologia



LETTERS TO THE EDITOR

Neuropsychiatric symptoms in Lewy body diffuse disease: A case report[☆]

Síntomas neuropsiquiátricos en la enfermedad difusa por cuerpos de Lewy: a propósito de un caso

Sir,

According to today's most widely accepted international criteria,^{1–3} diffuse Lewy body disease (DLBD) is an illness that evolves with a spectrum of clinical manifestations, characterized by the presence of cognitive impairment, fluctuations in the state of alertness, sensoriperceptual disorders including visual hallucinations, and Parkinsonism. Over the last few years, the spectral characteristics of this disease have been recognized, with those patients who debut with and have a predominance of cognitive symptoms at one end and with the other end including those individuals in whom Parkinsonian symptoms prevail.⁴ Both extremes of the disease converge as the disease progresses, as revealed by neuropathological correlation studies.^{5–7} Moreover, neuropsychiatric symptoms are widely reported by various authors in both groups of patients, albeit little study has been dedicated to the onset and evolution of these symptoms in DLBD. In this article, we present a brief description of a patient who meets the criteria for DLBD and who debuted with neuropsychiatric symptoms (severe depression and visual hallucinations), many years prior to presenting cognitive and Parkinsonism-type symptoms, which has led us to conduct a review of the issue and to suggest that some patients with DLBD may begin with only neuropsychiatric symptoms and persist many years displaying only these symptoms before presenting cognitive impairment and/or Parkinsonism.

A 79-year-old male patient, diagnosed with late-onset, recurring, major depressive disorder, presented a first major depressive episode in December 1994. Ever since onset, he has presented sensoriperceptual alterations in the form of visual hallucinations, with partial response to multiple treatment strategies, leading to hospitalization on sev-

eral occasions. The initial neuropsychological assessment failed to reveal cognitive impairment (MMSE 29/30, MIS 8/8, GDS 1), although a mild dysexecutive syndrome and mild alterations of visual memory were detected as attributing to the important depressive component without having a major bearing on the basic activities of daily living. In light of the patient's scant clinical improvement, treatment with electroconvulsant therapy (ECT) was initiated, with full remission of the depressive symptoms, although the visual hallucinations persisted. The patient presented recurrence of the depressive syndrome and visual hallucinations on several occasions until January 2003, with a depressive episode including deliria, which required another hospitalization that also led to more ECT sessions given the patient's poor response to treatment (neuroleptics, antidepressants and lithium, among others), presenting confusion that improved by increasing the intervals between ECT sessions until full remission of the symptoms was achieved.

In December 2006, the depressive symptoms became worse, with components of both deliria and confusion (occasional incoherent speech); in addition, the patient presented tremor at rest in the upper right limb, as well as clumsiness in his right hand, difficulty in walking and visual hallucinations that had not remitted in all those years, but had decreased. Diagnosis was oriented toward Hoehn and Yahr's stage II Parkinsonism,⁸ probably related to neuroleptics (olanzapine). The patient was hospitalized and treated with low-dose haloperidol, which was able to control the patient's deliria. The patient showed clear improvement of his psychiatric symptoms and, as a result, the neuroleptic drugs were discontinued at 3 months; however, the Parkinson-like symptoms not only persisted, but also became worse, with greater functional impairment. Consequently, levodopa at a dose of 50 mg every 8 h was initiated and he displayed worsening of the visual hallucinations that remitted following withdrawal of L-dopa. In May 2009, the patient once again presented exacerbation of complex visual hallucinations and symptoms of confusion, with persistence of depressive symptoms (sad mood, fatigability, and apathy), as well as worsening of his Parkinsonism, despite withdrawal of the other neuroleptics and being treated solely with clozapine and venlafaxine. At this time, asymmetric Hoehn and Yahr's stage 3 Parkinsonism was observed and the patient scored 70% on the Schwab and England scale of basic activities of daily living.⁹ The patient presented a total score of 32 points on the unified Parkinson's Disease Scale (UPDRS). The cognitive

[☆] Please cite this article as: Salazar G, et al. Síntomas neuropsiquiátricos en la enfermedad difusa por cuerpos de Lewy: a propósito de un caso. Neurología. 2011;26:499–502.

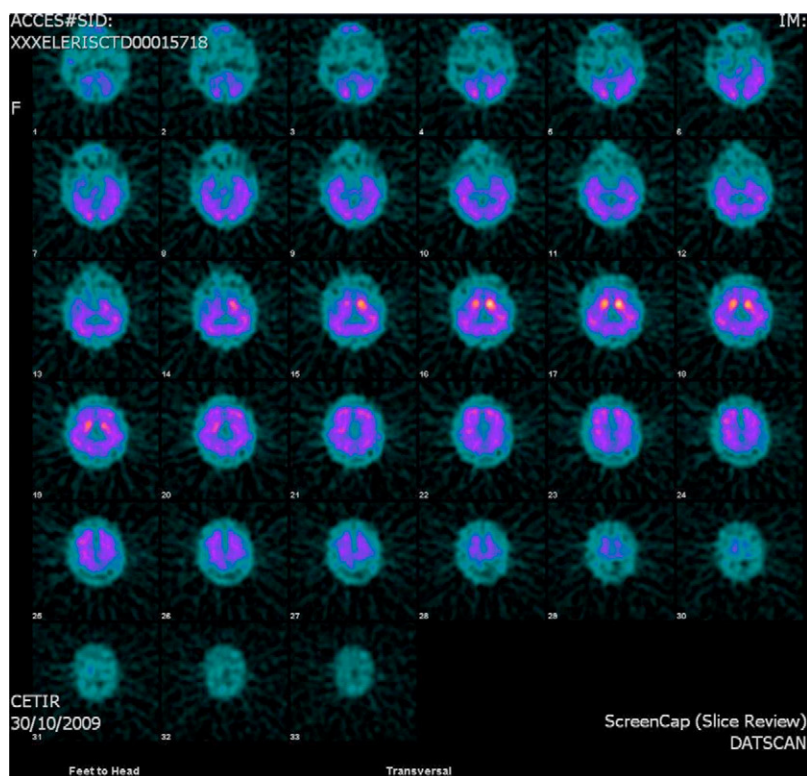


Figure 1 DATscan fluorodopa: low, asymmetric, uptake of fluorodopa is seen in the striatum.

scales revealed the following: MMSE 22/30 (delayed memory failure), MIS 4/8, blessed: 2/3/4 total=9, GDS 5. This new neuropsychological evaluation concluded that the patient presented cognitive impairment consistent with a mild stage of dementia (CDR 1), with a cortical-subcortical pattern, highlighting a severe deficit in the visual-spatial orientation and dysexecutive areas, compatible with the neuropsychological patterns seen in patients with Parkinson's disease.

Para-clinical studies revealed the following: cranial magnetic resonance: generalized cranial hypotrophy, more accentuated in both the amygdala and the hippocampus; the electroencephalogram was normal. The blood analysis showed all parameters to be normal, including blood testing for syphilis and human immunodeficiency virus, vitamin B₁₂ and folate levels, as well as thyroid hormones. The DATscan exhibited bilateral low uptake in the striatum that was asymmetrical and more noticeable in the right striatum (Fig. 1). In light of the patient's motor impairment, we initiated treatment with low dose dopamine agonist (rotigotine) given his history of worsening visual hallucinations with L-dopa. The patient showed improvement of his Parkinsonism at a dose of 8 mg of rotigotine, but his visual hallucinations became worse. As a result, we opted to lower the dose to 6 mg/day, at which he has remained stable, with a slight improvement of 30–40% in the Parkinsonism over his previous UPDRS scale score and with few visual hallucinations. We had previously increased the dose of clozapine to 75 mg/day; higher doses had increased his depressive symptoms in the past.

This is the case of a 79-year-old male patient presenting a major depression syndrome lasting more than 10 years, with visual hallucinations since the onset of the disease, that had been refractory to many conventional anti-depressant drug strategies and who, from the outset, had presented psychiatric elements of disease that pointed toward a depressive syndrome associated with organic brain disease, such as the presence of visual hallucinations and his poor response to polytherapy with antidepressants and neuroleptics. At that time, the neuropsychological tests showed only a dysexecutive disorder and mild visual symptoms without signs of cognitive impairment, which was attributed to the major depression. Given his poor response to these drugs, he underwent electroconvulsant therapy that showed scant effectiveness and significant side effects (confusional syndromes). The patient exhibited the first neurological symptoms (asymmetrical Parkinsonism) 8 years after the onset of his neuropsychiatric symptoms, initially ascribed to his medication (lithium/olanzapine), but which persisted and progressed over the following months despite having discontinued all the drugs that might cause or worsen his Parkinsonism. Mild cognitive impairment later appeared with cortical–subcortical elements that led us to request a DATscan fluorodopa test in which we could observe low asymmetrical striatal dopaminergic uptake, suggesting presynaptic Parkinsonism. The presence of asymmetric Parkinsonism and the fact that the patient's symptoms continued to progress despite having withdrawn the drugs associated with Parkinsonism, ruled out a possible pharmacological aetiology. The presence of fluctuations in his

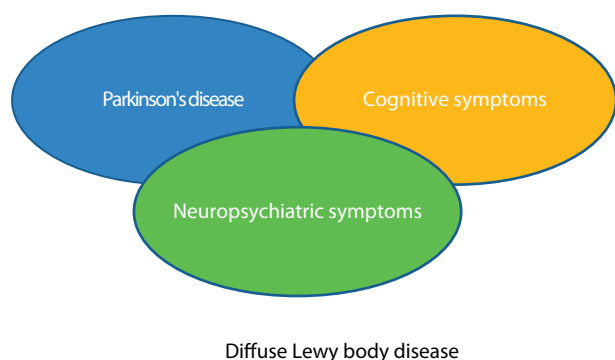


Figure 2 Three different clinical expressions of DLBD that may coincide as the disease progresses.

state of alertness and the visual hallucinations complete the accepted criteria for atypical Parkinsonism, probable diffuse Lewy body disease.¹⁰ The patient was neuropsychologically assessed at the onset of his depressive syndrome, displaying a mild dysexecutive syndrome and mild alteration of his visual memory. In a second evaluation carried out 7 years later, these visual and dysexecutive symptoms were seen to have become worse and mild dementia was observed with cortical-subcortical pattern as reported in some cases of DLBD.

DLBD is a spectral disease in which dementia and Parkinsonism are two common forms of clinical expression, according to many publications and international consensus statements, such as the American Lewy Body Dementia Association.¹¹ It has been recognized that in many patients with DLBD the clinical picture begins with profound, rapid dementia with fluctuating elements, in both the cognitive and state of alertness domains, and in others, it debuts with initial Parkinsonism with psychiatric sensoriperceptual manifestations (hallucinations), with variable response to L-dopa. This drug tends to make these symptoms worse. In spite of the fact that many research groups believe that visual hallucinations are an essential symptom of DLBD, there has been little information reported in the medical literature in relation to the onset of DLBD with neuropsychiatric symptoms, such as severe depression and visual hallucinations. One Spanish study reported a group of patients with DLBD with very severe neuropsychiatric symptoms, with a predominance of hallucinations and deliria,¹² as observed in our patient; nevertheless, there is little medical information about the course these symptoms follow in patients with DLBD. On the other hand, we are aware of the fact that our patient's diagnostic orientation is based on clinical criteria, as tends to be the case, and that we do not have a neuropathological study available by means of which to make the definitive diagnosis, which limits our observations; nonetheless, the patient meets widely accepted, clinical criteria for DLBD. We present a brain DATscan fluorodopa result compatible with presynaptic Parkinsonism and a neuropsychological study that is consistent with those described in patients with alpha-synucleinopathies. We also wish to point out that, despite the fact that this article presents an isolated case, there are some clinical-pathological correlation studies in which patients debut with neuropsychiatric

symptoms and, in a not terribly well-defined period of time, develop the remaining neurological symptoms.^{13,14}

It is possible that visual hallucinations comprise the first clinical manifestations in some patients with DLBD and, after a period of time that has yet to be determined, cognitive and extrapyramidal symptoms appear (Fig. 2). We believe that prospective studies including neuropsychological tests would of interest in patients with unrelated visual hallucinations that cannot be accounted for by any psychiatric disorder or by other known aetiologies (toxic, neoplastic, etc.) and to assess the usefulness of DATscan fluorodopa in these patients.

References

1. McKeith IG, Dickson DW, Lowe J, Emre M, O'Brien JT, Feldman H, et al. Diagnosis and management of dementia with Lewy bodies: third report of the DLB Consortium. *Neurology*. 2005;65:1863–72.
2. McKeith IG, Galasko D, Kosaka K, Perry EK, Dickson DW, Hansen LA, et al. Consensus guidelines for the clinical and pathologic diagnosis of dementia with Lewy bodies (DLB): report of the consortium on DLB international workshop. *Neurology*. 1996;47:1113–24.
3. McKeith IG, Perry EK, Perry RH. Report of the second dementia with Lewy body international workshop: diagnosis and treatment. Consortium on Dementia with Lewy Bodies. *Neurology*. 1999;53:902–5.
4. Honig LS. Recognition of vascular dementia, dementia with Lewy bodies, and front temporal dementia. Columbia University College of Physicians and Surgeons, Update for the practitioner. Available from: <http://ci.columbia.edu/c1182/web/sect.5/c1182.s5.3.html>.
5. McKeith IG, Ballard CG, Perry RH, Ince PG, O'Brien JT, Neill D, et al. Prospective validation of consensus criteria for the diagnosis of dementia with Lewy bodies. *Neurology*. 2000;54:1050–8.
6. Verghese J, Crystal HA, Dickson DW, Lipton RB. Validity of clinical criteria for the diagnosis of dementia with Lewy bodies. *Neurology*. 1999;53:1974–82.
7. Lennox G, Lowe J, Landon M, Byrne EJ, Mayer RJ, Godwin-Austen RB. Diffuse Lewy body disease: correlative neuropathology using anti-ubiquitin immunocytochemistry. *J Neurol Neurosurg Psychiatry*. 1989;52:1236–47. Available from: doi:10.1136/jnnp.52.11.1236
8. Hoehn MM, Yahr MD. Parkinsonism: onset, progression and mortality. *Neurology*. 1967;17:427–42.
9. Schwab and England activities of daily living. Gillingham FJ, Donaldson MC, editors. Third symposium of Parkinson's disease. Edinburgh: E&S Livingstone; 1969. p. 152–7.
10. Galvin JE, Boeve BF, Duda JE, Galasko DR, Kaufer D, Leverenz JB, et al. Representing the Scientific Advisory Council of the Lewy Body Dementia Association; May 2008.
11. Available from: <http://www.lbda.org/category/3438&cfid=9371011&cfToken=62733993/symptoms.html>.
12. López-Pousa S, Vilalta-Franch J, Garre-Olmo J, Pons S, Cucurella MG. Caracterización y prevalencia de los síntomas psicológicos y conductuales en pacientes con demencia. *Rev Neurol*. 2007;45:683–8.
13. Ala TA, Yang KH, Sung JH, et al. Hallucination and signs of parkinsonism help distinguish patients with dementia and cortical Lewy bodies from patients with Alzheimer's disease at presentation: a clinicopathologic study. *J Neurol Neurosurg Psychiatry*. 1997;62:16–21.
14. Ballard C, Holmes C, McKeith I, Neill D, O'Brien J, Cairns N. Psychiatric morbidity in dementia with lewy bodies: a prospec-

tive clinical and neuropathological comparative study with Alzheimer's disease. *Am J Psychiatry* 199;156:1039–45.

G. Salazar^{a,*}, D. Cuello^a, M. Frago^a, L. Benlloc^b

^a Servei de Neurologia, Hospital Consorci Sanitari de Terrassa, Barcelona, Spain

^b Servei de Psiquiatria, Hospital Consorci Sanitari de Terrassa, Barcelona, Spain

* Corresponding author.

E-mail address: gsalaz64@gmail.com (G. Salazar).

doi:10.1016/j.nrleng.2011.01.009

First case of Moebius–Poland syndrome in child prenatally exposed to misoprostol[☆]

Primer caso de síndrome de Moebius-Poland en niño expuesto prenatalmente a misoprostol

Sir,

Moebius syndrome (OMIM 157900) is characterised by facial paralysis with impairment of ocular abduction. The facial nerve (cranial nerve VII) and the abducens nerve (cranial nerve VI) are the ones most commonly involved, but other cranial nerves can also be affected. The phenotype is variable and may include congenital, orofacial and limb defects.¹

The Poland syndrome (OMIM 173800) is characterised by the presence of unilateral brachysyndactyly and ipsilateral aplasia of the sternal portion of the pectoralis major muscle. It is sometimes called Poland sequence, as it was initially described in Poland.²

The combination of Moebius and Poland syndrome is rarely seen. It has been estimated to occur in 1 in 500,000 people; in the literature we reviewed, we did not find this association with cases of prenatal exposition to misoprostol.³

We present a report on Moebius and Poland syndrome in a newborn prenatally exposed to misoprostol.

The patient, who was the son of an 18-year-old mother, was brought to consult for facial dysmorphism. However, on examination he was found to have bilateral facial paralysis, a rounded face, narrow palpebral fissures, cupid's bow lips, arched palate, micrognathia and hypoplasia with absence of pectoralis major nipple (Atelier), as well as proximal syndactyly of second and third fingers and bilateral clubfoot (Figs. 1 and 2). As an important background fact, we found that his mother had used 400 g of misoprostol orally and vaginally at 5 weeks of gestation to bring about an abortion, but had had only slight bleeding.

Misoprostol is a synthetic analogue of prostaglandin E1 approved by drug regulatory agencies in many countries for the prevention and treatment of gastric ulcers associated to the use of non-steroidal anti-inflammatories, due to its gastric acid antisecretory effect. Prenatal exposure to misoprostol has been associated to vascular disruption defects, mainly Moebius sequence and terminal transverse type limb defects.^{4,5}

The abnormalities in the vascular structure could be secondary to teratogenic effects. Teratogens can act directly by reducing blood flow or blood vessel development, changing anatomy and/or structure.^{6,7} The vascular abnormalities of the right subclavian artery observed in Poland syndrome could be related to a vascular disruption caused by misoprostol during a critical period.^{5,8}

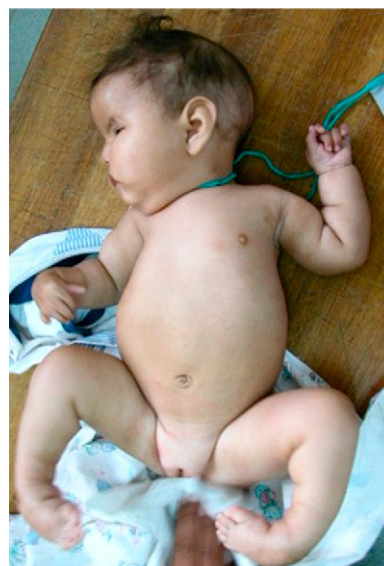

Figure 1 Note the typical phenotype of Moebius–Poland syndrome, hypoplasia of the chest with clubfoot Atelier.

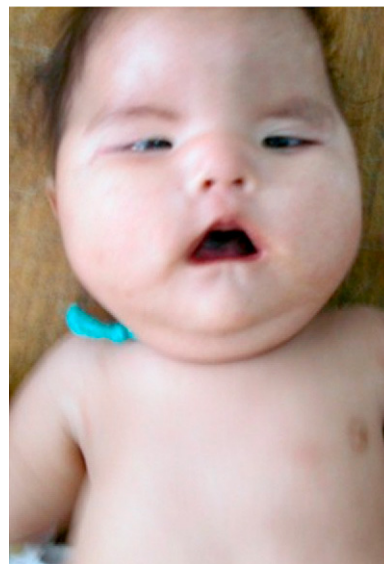

Figure 2 Note the bilateral facial paralysis, a typical characteristic of Moebius syndrome.

[☆] Please cite this article as: Pachajoa H, Isaza C. Primer caso de síndrome de Moebius-Poland en niño expuesto prenatalmente a misoprostol. *Neurología*. 2011;26:502-3.