



CASE STUDY

Solitary Fibrous Tumour of the Smooth Palate[☆]

Elena Sánchez-Legaza^{a,*}, Rosario Guerrero-Cauqui^b, Jose Idelfonso Miranda Caravallo^c, Carlos Murga Tejada^a

^a Servicio de ORL, Hospital de la Línea de la Concepción, Cádiz, Spain

^b Servicio de Anatomía Patológica, Hospital de la Línea de la Concepción, Cádiz, Spain

^c Servicio de Anestesia, Hospital de la Línea de la Concepción, Cádiz, Spain

Received 9 July 2009; accepted 3 February 2010

KEYWORDS

Solitary fibrous tumour;
Mesenchymal tumour;
Oral cavity

Abstract The solid fibrous solitary tumour of the oral cavity is an extremely rare entity. It is also of complicated diagnosis because of its extensive morphologic diversity (especially when there is a small amount of biopsied tissue) and because of its similarity to many mesenchymal injuries, mostly with hemangiopericytoma. The prognosis is reserved because of the few cases reported, mainly depending on tumour location and size.

© 2009 Elsevier España, S.L. All rights reserved.

PALABRAS CLAVE

Tumor fibroso solitario;
Tumor mesenquimal;
Cavidad oral

Tumor fibroso solitario del paladar blando

Resumen El tumor fibroso solitario de la cavidad oral es una entidad extremadamente infrecuente y difícil de diagnosticar por su amplia diversidad morfológica, especialmente cuando se trata de biopsias de pequeño tamaño por su similitud con numerosas lesiones mesenquimales como el hemangiopericitoma. Su pronóstico es reservado por los pocos casos reportados, debiendo basarse en la localización y tamaño del tumor.

© 2009 Elsevier España, S.L. Todos los derechos reservados.

Introduction

Solitary fibrous tumour (SFT) is an uncommon ubiquitous neoplasm, which was described by Klemperer and Rabin (1931) as a benign variant of pleural mesothelioma.¹

Its histogenesis is not well known. Initially, a mesothelial origin was postulated (Stout, 1950) and subsequently a mesenchymal origin, as it arises from primitive pluripotent mesenchymal cells, being differentiated from mesothelial cells, fibroblasts and other cells.²

It is located in the pleura, mediastinum, pericardium, and retroperitoneum. It is also found in other extracerebral locations such as the spinal cord, lung, breast and liver, and more rarely in the cervicofacial region. Its symptoms are related to the location and size of the lesion.

Due to its low frequency, it can be confused with other neoplasms in this area. Histological and

[☆] Please cite this article as: Sánchez-Legaza E, et al. Tumor fibroso solitario del paladar blando. Acta Otorrinolaringol Esp. 2011;62:239–41.

* Corresponding author.

E-mail address: manpro1910@hotmail.com (E. Sánchez-Legaza).

immunohistochemical studies are consequently of great help in establishing its diagnosis.

Clinical Case

We present a female patient, 80 years old, who attended consultation due to an oropharyngeal foreign body sensation. Past medical history included the removal of a uvular papilloma, 5 years earlier.

The examination revealed a polypoid tumour affecting the uvula. The MRI showed a vascular lesion limited to the uvula, without enlarged lymph nodes (Fig. 1).

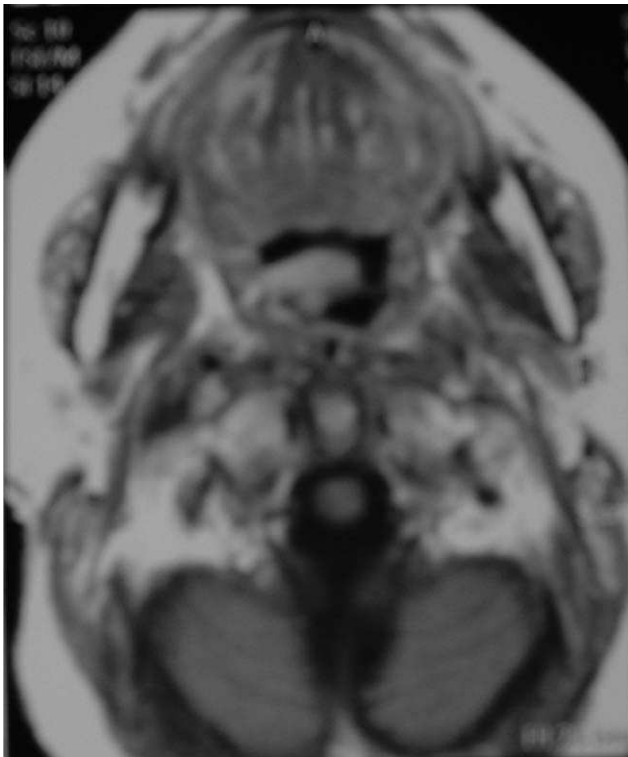

Figure 1 The MRI shows a hypervascularised and hypertrophied uvula.

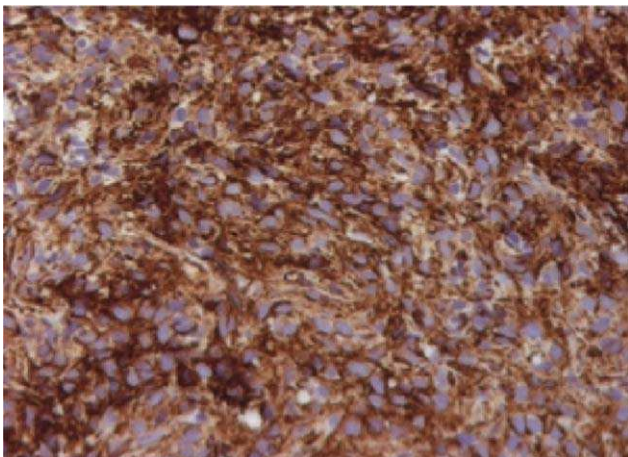


Figure 2 CD34+ spindle cell tumour.

A 0.5 cm whitish lesion of elastic consistency was removed. At the histological level, the tumour was composed of spindle cells with atypia and without necrosis, showing a strong immunoreactivity for vimentin and CD34, and variable for vimentin and BCL-2 (Fig. 2).

The patient is currently asymptomatic and free of disease after a follow-up period of 10 years.

Discussion

This is a spindle cell neoplasm of mesenchymal origin, described as a slow-growing, well-circumscribed lesion with a low rate of recurrence in areas not related to serous cavities, such as meninges, infratemporal fossa, orbit, nasal cavity and paranasal sinuses, nasopharynx, oral cavity, major salivary glands (mainly the parotid gland, followed by submaxillary gland), thyroid, peritoneal tissue, pharynx, parapharyngeal space and epiglottis.³

It is unusual in the oral cavity, as it is usually located in oral mucosa of cheek, tongue, posterior triangle, soft palate and upper lip. A total of 50 cases have been reported in the oral mucosa, with only case being located in the soft palate.⁴

It is most prevalent between the third and sixth decades of life, with a mean age of 59 years. It does not show a predilection for either gender. Clinically, it appears as a painless lesion, well circumscribed, hard and mobile, with a slow growth at the expense of the submucosa, variable in size and covered by mucosa of normal appearance.

The reason for low incidence of SFT is unknown. It may be explained by the presence of local inhibitory factors in saliva, which prevent the development of tumours in this location.^{3,4} It is usually benign, although in 10% of cases it may invade locally, displaying a malignant phenotype with metastasis.⁵

Its diagnosis is difficult, owing to the facts that there are no standardised growth patterns, that there is intratumoural morphological variability and immunophenotype heterogeneity as well. This has led authors such as Chan and Alawi to recommend carrying out certain immunostaining of the resected tumour to confirm the diagnosis. This peculiarity is particularly true in extrapleural locations, due to extreme intratumoural variability and to its similarity with other mesenchymal malignancies.^{2,6,7} This explains why SFT is especially misdiagnosed in small biopsies, even requiring a new reassessment, as in our case.

The immunohistochemical study is characterised by immunoreactivity positive for vimentin and CD34, variable and weak for BCL-2 and CD99, and negative for CD68, pan-cytokeratin, desmin and protein S-100.⁶

Cytogenetic analysis revealed a normal karyotype in 5/20 cells.⁸ CD34 is an unspecific marker, as it also appears in tumours such as leukaemia, vascular neoplasms, schwannoma and haemangiopericytoma.

The differential diagnosis is carried out with spindle cell tumours such as fibrous histiocytoma, myoepithelioma, schwannoma, myofibroma and haemangiopericytoma, as well as with other tumours: lymphoma, sarcoma, lymphangioma, ameloblastoma and dental abscess or with simple fibrous hyperplasia.^{6,7}

In 1997, Chan et al. proposed the following diagnostic criteria: circumscribed tumour, presence of foci alternating areas of hypocellular sclerosis with other areas of hypercellularity composed of spindle and ovoid cells with a clear cytoplasm, with a fascicular or storiform pattern and low mitotic activity (less than 4 per 10 high increase fields).² Other authors also propose a pattern of vascular hemangiopericytoma.⁶

The prognosis is based on tumour location, size and histological features considered as malignancy parameters, such as high cellularity, pleomorphism, high mitotic index, presence of necrosis and haemorrhage. However, the most important prognostic factor seems to be the complete excision of tumour. Malignant cases have been reported in up to 10%–23%, when the location is pleural. Although the underlying mechanism is unknown, suggestions have included *de novo* appearance and malignant transformation of a benign low-grade lesion. Extrapleural cases are almost always benign,⁹ and heal with surgical excision. Metastases are more frequent when they are located in the lung, bone and liver.^{1,10}

The treatment of choice is usually surgical excision with wide, tumour-free margins, without requiring additional treatment since those located in the head and neck rarely recur. Chemotherapy (adriamycin and dacarbazine) and radiotherapy have been used in cases with positive surgical margins.^{11,12}

Faced with suspicion of malignancy, monitoring should last for at least 10 years to rule out recurrence or metastasis.

Conflict of Interest

The authors have no conflicts of interest to declare

References

1. Hasegawa T, Matsuno Y, Shimoda T. Extrathoracic fibrous tumors: their histologic variability and potentially aggressive behavior. *Hum Pathol.* 1999;30:1464–73.
2. Chan JKC. Solitary fibrous tumour everywhere, and a diagnosis in vogue. *Histopathology.* 1997;31:568–76.
3. Nkenke E. Solitary fibrous tumor in the tongue: case report and review of the literature. *HNO.* 2007;55:287–92.
4. Shimoyama T, Horie N, Ide F. Solitary fibrous tumor of the palate: a case report and review of the literature. *J Oral Maxillofac Surg.* 2004;62:895–7.
5. González- García R. Solitary fibrous tumor of the cavity with histological features of aggressiveness. *Br J Oral Maxillofac Surg.* 2006;44:543–5.
6. Alawi F, Stratton D, Freedman PD. Solitary fibrous tumor of the oral soft tissues. A clinicopathologic and immunohisto-chemical study of 16 cases. *Am J Surg Pathol.* 2001;25:900–10.
7. Lo Muzio L, Macolo M, Capodiferro S, Favia G, Maiorano E. Solitary fibrous tumor of the oral cavity: the need for an extensive sampling for a correct diagnosis. *J Oral Pathol Med.* 2007;36:538–42.
8. Mano E, Bobner L. Chromosomal aberrations in oral solitary fibrous tumour. *Cancer Genetics Cytogenetics.* 2007;174:170–2.
9. Dunfee BL, Sakai O, Spiegel JH, Pistey R. Solitary fibrous tumor of the buccal space. *AJNR.* 2005;26:2114–6.
10. Shnayder Y, Greenfield B, Oweity T, DeLacure M. Malignant solitary fibrous tumor of the tongue. *Am J Otolaryngol.* 2003;24:246–9.
11. Shine N, Khasri M, Fitzgibbon J, O'Leary G. Solitary fibrous tumor of the floor of the mouth: case report and review of the literature. *Ear Nose Throat J.* 2006;85:437–9.
12. Shirmang TC, Davis LM, Nigri PT, Dupuy DE. Solitary fibrous tumor of the buccal space: treatment with percutaneous cryoablation. *AJNR.* 2007;28:1728–30.