



## REVIEW

## Audiovestibular manifestations in systemic vasculitis

Juan Carlos Amor Dorado,<sup>a,\*</sup> María del Pilar Barreira Fernández,<sup>a</sup>  
Sandra Regueiro Villarin,<sup>a</sup> and Miguel Ángel González-Gay<sup>b</sup>

<sup>a</sup>Servicio de Otorrinolaringología, Complejo Hospitalario Xeral-Calde, Lugo, Spain

<sup>b</sup>Servicio de Reumatología, Complejo Hospitalario Xeral-Calde, Lugo, Spain

Received November 10, 2008; accepted January 13, 2009

Available online September 20, 2009

### KEYWORDS

Systemic vasculitis;  
Audiovestibular  
manifestations;  
Hearing loss;  
Vertigo

### Abstract

Systemic vasculitides constitute a heterogeneous group of diseases with frequent overlapping in their clinical findings and the size of the vessels involved. They may be primary or secondary to other diseases. Their common characteristic is the inflammation of blood vessels, giving rise to ischaemia. In the present article, we have reviewed the most common audiovestibular features that may be observed in patients with systemic vasculitides. Audiovestibular manifestations may be the first symptom of a systemic vasculitis. Audiological manifestations include sudden hearing loss and progressive sensorineural hearing loss. Vertigo and nystagmus are vestibular symptoms that may be observed in several systemic vasculitides. Vestibular loss in caloric test, abnormal head-shaking nystagmus, head thrust test, and positioning test (benign paroxysmal positioning vertigo) may also be found. Improvement of audiovestibular function is frequently observed in patients with giant cell arteritis following corticosteroid therapy.

© 2008 Elsevier España, S.L. All rights reserved.

### PALABRAS CLAVE

Vasculitis sistémica;  
Manifestaciones  
audiovestibulares;  
Hipoacusia;  
Vértigo

### Manifestaciones audiovestibulares en las vasculitis sistémicas

### Resumen

Las vasculitis sistémicas son un grupo heterogéneo de enfermedades con solapamiento de las manifestaciones clínicas y el tamaño de los vasos afectados. Su etiología puede ser primaria o secundaria. La característica es la inflamación de los vasos sanguíneos que causa los fenómenos isquémicos. En esta revisión se lleva a cabo una descripción de las vasculitis y sus manifestaciones audiovestibulares conocidas hasta la fecha. La clínica audiovestibular puede ser la primera

\*Corresponding author.

E-mail address: Juan.Carlos.Amor.Dorado@sergas.es (J.C. Amor Dorado).

manifestación de una vasculitis sistémica. Entre las manifestaciones auditivas predomina la hipoacusia súbita y la neurosensorial progresiva, mientras que entre las vestibulares predominan vértigo y nistagmo. En la exploración vestibular destacan la hipofunción vestibular en la prueba calórica, las alteraciones en las pruebas de agitación cefálica, oculocéfálica y posicionales (vértigo posicional paroxístico benigno). El tratamiento con esteroides suele obtener mejoría de los síntomas y la disfunción audiovestibular en la mayoría de los pacientes con arteritis de células gigantes.

© 2008 Elsevier España, S.L. Todos los derechos reservados.

## Introduction

Vasculitides are a group of diseases that were considered rare years ago. However, as knowledge of them has expanded, there have become increasingly important in the differential diagnosis of patients with varied manifestations, not only rheumatological, but also with sensory and visceral affection in varied locations, extent and severity.

Systemic vasculitis comprises a heterogeneous group of diseases that often overlap each other, with various aetiologies and clinical manifestations. The common feature among them is the inflammation of the lining of blood vessels, which causes ischemic events and tissue necrosis, as well as the occlusion of the lumen of vessels and, consequently, impaired function of the affected organ.<sup>1</sup>

Any blood vessel can be affected by the vasculitic phenomenon. Moreover, the extent and site of affection of the vessels varies depending on the type of vasculitis; in general, they tend to be irregular and segmental. In severe forms, lesions spread throughout the body. In mild forms, it can be located in a single region of the body; for example, limited to the skin in patients with leukocytoclastic cutaneous vasculitis. Others, however, cause lesions in several distant organs such as kidneys or lungs in patients with microscopic polyangiitis and Wegener's granulomatosis. Some vasculitis forms appear with lesions in the same stage of development, as in the case of cutaneous lesions that appear with an outbreak of Schönlein-Henoch purpura. In others, such as polyarteritis nodosa, lesions that are at different stages of development in different organs concur.

Some forms of vasculitis may have an acute course, mainly those with a predominantly skin condition. In contrast, others such as Takayasu's arteritis have shown varying degrees of activity for over 20 years.<sup>1</sup>

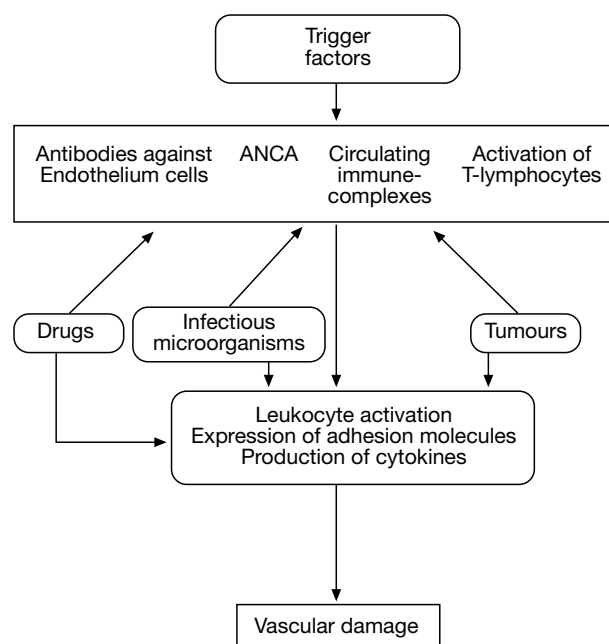
## Aetiopathogenesis

Different pathogenetic mechanisms have been described, particularly immunologic, which damage vascular integrity and cause tissue ischemia symptoms. Furthermore, tumour cells, infectious agents and drugs can also mediate in the process of vascular damage.<sup>2</sup> Some vasculitis, such as giant cell arteritis (GCA), Takayasu's arteritis and Behcet's disease, have been associated with a genetic predisposition.<sup>3</sup> On the other hand, endothelial cells, adhesion molecules and

cytokines play a key role in the development of different vasculitis syndromes<sup>4</sup>.

The mechanisms of vascular damage can be resumed as follows<sup>2,4</sup> (Figure 1):

1. Formation of immune complexes, which are essential in vasculitis affecting small vessels, such as cutaneous leukocytoclastic vasculitis, Schönlein-Henoch purpura, and mixed cryoglobulinemia. These activate the complement cascade and their chemotactic products attract neutrophils, which in turn infiltrate the vascular wall and, through their lysosomal enzymes, destroy the vessel wall. The deposition of these immune complexes occurs from a pathological point of view by leukocytolysis, leukocyte death, fibrinoid necrosis in the cells of the vascular wall and extravasation of red blood cells in the tissues.



**Figure 1** Mechanisms of vascular damage in vasculitis.

2. Vascular damage mediated by antibodies against endothelial cells, in Wegener's granulomatosis, microscopic polyangiitis, Kawasaki disease, Behcet's disease and Takayasu's arteritis.
3. Vascular damage associated with the production of antineutrophil cytoplasmic antibodies (ANCA). ANCA recognise intracellular enzymes present in the granules of neutrophils and monocytes. The most common and best characterised specificities of ANCA are the perivascular (pANCA) and the cytoplasmic (cANCA), which bind to the enzymes myeloperoxidase (MPO) and proteinase-3 (PR3), respectively. The presence of cANCA has been correlated with the diagnosis of Wegener's granulomatosis, as these antibodies are present in 90% of patients with this vasculitis before starting treatment. The pANCA are primarily associated with microscopic polyangiitis and idiopathic glomerulonephritis, but they have also been observed in other autoimmune diseases and systemic vasculitis, such as Churg-Strauss vasculitis.<sup>4</sup>
4. Vascular damage due to immune cell responses that cause the development of granulomas, as seen in Wegener's granulomatosis, Churg-Strauss vasculitis, and giant cell arteritis.<sup>4</sup>
5. Vascular damage mediated by infectious agents. Infection of vascular endothelium or subendothelial structures by infectious agents may lead to a direct toxic effect on the endothelial cell. A great variety of pathogens have been associated with the development of vasculitis. Of these, the best characterised relationship is that of classical polyarteritis nodosa and chronic infection by hepatitis B and C virus.<sup>2,4</sup>
6. Vascular damage mediated by tumour cells due to deposition of immune complexes containing tumour antigens or direct invasion of the vascular wall by malignant cells. Examples of this are the association of polyarteritis nodosa with hairy cell leukaemia, granulomatous vasculitis associated with Hodgkin's disease, and the frequent development of small vessel vasculitis associated with a wide variety of malignant diseases.<sup>2</sup>
7. Drugs, often in connection with the deposition of immune complexes, especially in cases of leukocytoclastic vasculitis caused by various medications: sulphonamides, thiazide diuretics, and penicillins.<sup>2</sup> In this process, the drugs would act as a hapten. Alternative mechanisms have been reported, which would be linked with a possible direct toxicity of drugs in the vessel walls, the action of self-antibodies that are capable of reacting against endothelial cells and a direct cellular toxicity reaction against the vessel wall triggered by drugs.

## Classification and diagnosis

Vasculitides are by nature a heterogeneous group of diseases with diversity and overlapping of clinical manifestations as well as in the size of the affected vessels. According to their aetiology, they can be classified as primary or idiopathic and secondary to other processes.

Since most vasculitis forms have no clinical features and pathognomonic laboratory tests and aetiology are not completely defined, classification in a mode that can be accepted worldwide is a virtually impossible task. Although the use of classification criteria is useful to improve our knowledge of these diseases, they should not be considered as diagnostic criteria. The classification criteria are more useful for the study of patient groups and the analysis of the epidemiology of these processes, rather than for the study and management of an individual patient.

The first attempt to classify the vasculitis was that by Zeek<sup>5</sup> in 1952. In 1964, based on the classification scheme of Zeek, Alarcon-Segovia et al<sup>6</sup> completed this classification.

**Table 1** Classification of the different vasculitis

Dominant affected vessel	Vasculitis	
	Primary	Secondary
Vasculitis predominantly affecting large vessels	Giant cell arteritis; Takayasu's arteritis	Infections (eg, syphilis)
Vasculitis predominantly affecting medium vessels	Isolated central nervous system angiitis	Aortitis associated with RA
Vasculitis predominantly affecting medium and small vessels	Classic polyarteritis nodosa	Infections (such as hepatitis B, bacterial endocarditis)
	Kawasaki disease	Secondary to RA, Churg-Strauss syndrome; drugs and infections (eg, HIV)
	Wegener's granulomatosis SLE;	
	Sjögren syndrome;	
	microscopic polyangiitis scleroderma and other connectivopathies	
Vasculitis predominantly affecting small vessels	Schonlein-Henoch purpura	Drugs and infections (eg, hepatitis B and C)
	Essential mixed cryoglobulinemia	
	Urticarial vasculitis	
	Leukocytoclastic cutaneous angiitis	
	Behcet disease	

ESL indicates erythematosus systemic lupus; HIV, human immunodeficiency virus; RA, rheumatoid arthritis.

**Table 2** Clinical manifestations of the systemic vasculitis without including the otorhinolaryngology

Disease	Clinic	Diagnosis
Giant cells arteritis	Headache. Hypersensitivity of the hairy leather Rheumatic polymyalgia Temporary arteries abnormal to the exploration Clinic visual (amaurosis fugax, blindness) Asthenia, anorexia, loss of weight, fever	Temporary artery biopsy Elevation GSV
Takayasu arteritis	Blood pressure differences Absent or diminished pulses Extremities claudication Arterial hypertension	Arteriography: Aneurysms Vascular stenosis Collateral circulation
PAN (classic panarteritis nodosa)	Systemic clinic: asthenia, anorexia Cardiac alterations Rheumatic disorder Peripheral neuropathy Digestive alterations	Biopsy: Skin Muscle Peripheral nerve
Microscopic polyangiitis	Nephropathy (focal necrotizing glomerulonephritis, etc) Systemic clinic Skin lesions (purpura, etc) Neuropathy Fever	Clinic + radiology + pathological anatomy + laboratory tests (pANCA)
Kawasaki disease	Pulmonary clinic (hemoptysis) Fever Cardiovascular clinic (myocarditis, pericarditis, mitral insufficiency) Bilateral conjunctivitis Exanthema Oropharyngeal alterations Adenopathy cervical	Echocardiogram Electrocardiogram Laboratory tests (GSV, hypoalbuminemia, elevated C-reactive protein)
Wegener disease	Upper airways affection (sinusitis, destructions of bony and cartilaginous structures, tracheobronchial inflammation) Pulmonary affection (interstitial infiltrates, pulmonary nodules) Nephropathy (necrotizing vasculitis) Mono-neuritis multiplex	Clinical suspicion + laboratory tests (cANCA) + histology Cutaneous biopsy leucocytoclastic vasculitis with IgA deposit)
Schönlein-Henoch syndrome	Cardiac clinic (cardiac insufficiency) Abdominal angina, intestinal bleeding Renal: hematuria, proteinuria, mesangial-Ig A glomerulonephritis, renal insufficiency (adults)	
Cryoglobulinemia	Arthralgias, intermittent purpura in inferiors extremities, renal affection, sensitive peripheral neuropathy, hepatic affection, diffuse abdominal pain by mesenteric infarct, pulmonary affection (asthma, hemoptysis), CNS affection (CVA, convulsions)	Cryoglobulin in blood, cutaneous biopsy (leucocytoclastic vasculitis), hypocomplementemia (C4 low) Determine whether HCV or HBV infection
Urticarial vasculitis	Dermatologic: wheal Ocular: uveitis, episcleritis Articular: arthralgia or arthritis Pulmonary: dyspnea by emphysema Cardiac: pericarditis, valvulopathy	Clinic Sometimes associated to hypocomplementemia Cutaneous biopsy (leucocytoclastic vasculitis)
Skin leukocytoclastic angiitis	Dermatologic: palpable purpura Sometimes general arthralgia and symptoms: fever, malaise, and arthralgia	Clinic limited to the skin generally Cutaneous biopsy (leucocytoclastic vasculitis)

**Table 2** (continuation)

Disease	Clinic	Diagnosis
Behçet disease	Relapsing aphthosis Anterior uveitis Genital aphthosis Cutaneous alterations (erythema nodosum, positive pathergy) Articular alterations (synovitis, arthritis) CNS affection	Clinical criteria: International Group of Study for the Behçet disease
Cogan's syndrome	Interstitial keratitis Audiovestibular alterations Cardiac alterations (aortitis, infarct) Articular affection (polyarthralgia, arthritis) Neurological clinic	Clinical: interstitial keratitis + neurosensorial hypoacusis
Rheumatoid arthritis	Articular clinical (additive polyarthritides and symmetric with affection of wrist and small articulations of hands and feet) Extra-articular manifestations (eg, rheumatoid nodules, pleuritis, pericarditis, episcleritis)	Clinic (criteria of the American College of Rheumatology) Positive anti-citrullinated peptide antibodies
Systemic lupus erythematosus	Fever, asthenia, anorexia Articular clinical (arthralgia, arthritis) Cutaneous clinical (malar erythema, papule erythematous, lesion of discoid lupus, photo-sensitivity, alopecia) Pleuro-pulmonary affection (pleuritis, pneumonitis) Cardiac alterations (pericarditis). Neuropsychiatric clinic Nephropathy (diffuse proliferative glomerulonephritis, focal proliferative, membranous)	Clinic + laboratory (ANA, anti-ADN, Anti-Sm, hypocomplementemia, leukocytopenia, lymphocytopenia, autoimmune hemolytic anemia, thrombocytopenia)
Sjögren syndrome	Ocular dryness (keratoconjunctivitis sicca) Xerostomia (caries, cheilitis) Arthralgia	Clinic Schirmer test Biopsy of minor salivary gland ANA, Anti-SSA/To, Anti-SSB/La, cryoglobulin positive

ANA indicates antinuclear antibodies; CNS, central nervous system; CVA, cerebrovascular accident; HBV, hepatitis B virus; HCV, hepatitis C virus; GSV, globular sedimentation velocity; URT, upper respiratory tract.

Shazo described a classification which was very similar to the previous one in 1975, but added the terms leukocytoclastic angiitis and Wegener's granulomatosis.<sup>2</sup> In 1976, Gilliam and Smiley added more subgroups and highlighted the considerable overlap in the size of the affected arteries in different types of systemic vasculitis.<sup>2</sup> In 1978, Fauci et al<sup>7</sup> proposed a classification that has endured for more than a decade.

In the eighties, Lie<sup>1</sup> made a new attempt at classification of systemic vasculitis, initially separating vasculitis into infectious and non-infectious.

In 1990, a subcommittee of the American College of Rheumatology (ACR) developed classification criteria for 7 types of systemic vasculitis.<sup>8</sup> The objective of this subcommittee was to standardize clinical definitions for use in epidemiological research or therapeutic studies. The method involved the identification of a group of clinical findings that were manifested with great frequency in each individual type of vasculitis (classification criteria), thus

suggesting that the vasculitis had occurred (sensitivity) or excluding others (specificity). The sensitivity and specificity of these criteria never reached 100% in any of the 7 vasculitides.<sup>9</sup>

In 1994, Jeannette et al<sup>10</sup> attempted to establish a system of standardised nomenclature of vasculitis known as Chapel Hill International Consensus. In this attempt, in addition to defining the clinical and laboratory criteria for the definition and diagnosis of ten vasculitis forms, the authors classified them into 3 groups: large size vasculitis, medium size vasculitis, and small vessel vasculitis.

Following the previously mentioned classifications, a classification system for vasculitis is proposed based on the size of the affected vessels (Table 1).<sup>11</sup>

For the diagnosis of primary vasculitis, in addition to the classification criteria of the ACR<sup>8</sup> and the Chapel Hill International Consensus<sup>10</sup> on nomenclature of systemic vasculitis, each of the entities described presented characteristic clinical manifestations (Table 2). To consider

that a patient has a secondary vasculitis, it must occur in a context defined appropriately according to the criteria of the entity to which it is related, and demonstrate the vasculitis through biopsy of one of the affected tissues.

## Inner ear disorders in vasculitis

The inner ear may be involved in organ-specific autoimmune diseases such as autoimmune inner ear disease described by McCabe in 1979,<sup>12,13</sup> and it may be the target organ in various non-organ specific systemic diseases. Among these, some are the result of direct autoimmune lesion and others of vascular damage which, in turn, can be primary or secondary to infections or collagen diseases (Table 1). Systemic vasculitis forms belong to the group of diseases that have vascular damage as their main pathogenic factor.

Moreover, regardless of the aetiology of the various diseases affecting the inner ear, pathological findings are identical. They include<sup>14</sup> degeneration and destruction of the peripheral receptor; segmental and diffuse infiltration of lymphocytes, plasma cells, and macrophages; proliferation of fibrous tissue, and varying degrees of ossification of the inner ear.

## Endolymphatic hydrops

Next, we discuss the studies to date that have associated vasculitis with auditory and/or vestibular manifestations. Table 3 presents the different audiovestibular manifestations described according to the classification of vasculitis.

Giant cell arteritis (GCA) is a multisystemic disease of unknown aetiology that occurs in people older than 50 and is predominant in women; it is usually accompanied by an elevated erythrocyte sedimentation rate. It is a vasculitis that affects vessels of medium and, especially, large size; it is also characterised by granulomatous affection of the aorta and its major branches, with a predisposition towards the cranial area, both in the arterial branches arising from the external carotid (explaining the topical headaches) and the internal carotid artery, leading to the feared blindness, either by affection of the posterior ciliary arteries or the central retinal artery. GCA is often present with temporo-parietal throbbing headaches, different from the usual, which often accompanied by polymyalgia rheumatica and, to a lesser extent, jaw claudication, amaurosis fugax, blindness, or stroke predominantly in the vertebrobasilar territory.<sup>15-18</sup>

The definitive diagnosis is obtained by a temporal artery biopsy demonstrating disruption of the internal elastic lamina with lymphocytic inflammatory infiltration and multinucleated giant cells in 50% of cases<sup>19</sup> (Figure 2).

The last 4 decades have witnessed a significant increase in the number of diagnosed cases of GCA. This increase has not only been found in areas where GCA is common,<sup>20</sup> but also where the incidence was low.<sup>21-23</sup> This fact can be explained by a greater awareness of the disease. In our population in Lugo of individuals older than 50, the incidence of GCA adjusted for age and gender is 10/100 000 inhabitants/year, but it reaches 23/100 000 inhabitants/year in the group of patients between 70 and 79.<sup>24,25</sup>

In a prospective study of 44 patients with GCA and 10 with polymyalgia rheumatica isolated from our Lugo population, the presence of audiovestibular alterations was confirmed exclusively in the group of patients with GCA, which was modified over time and improved in most of patients after initiating treatment with steroids.<sup>26</sup> In this regard, 90% of patients with GCA showed abnormalities of peripheral vestibular function at the time of diagnosis, which remained only in 29% of cases after 3 months of completion of the first audiovestibular assessment, coinciding with the start of treatment with steroids. The most significant vestibular alteration detected at 3 months was paired horizontal nystagmus in the cephalic agitation test. In addition, sensorineural hearing loss also improved at 3 months after steroid treatment in 27% of patients.<sup>26</sup> Furthermore, we found a close relationship between GCA and benign paroxysmal positional vertigo of the posterior semicircular canal in our population.<sup>27</sup>

Polymyalgia rheumatica is characterised by pain in the scapulae and proximal aspects of the shoulders, pelvis and proximal aspects of the lower extremities and the cervical region, together with morning stiffness of more than 1 h; it may be present in about 40% of patients with GCA.<sup>15</sup> However, polymyalgia rheumatica may be a separate entity<sup>16</sup> or the initial form of a GCA that does not initially show cranial condition data or other ischemic symptoms suggesting a GCA.<sup>28</sup> Therefore, the detection of audiovestibular abnormalities in one of our patients who initially showed only clinical symptoms of polymyalgia rheumatica was of particular importance. The patient did not initially present the ischemic vascular disease typical of GCA, but monitoring showed the typical manifestations attributable to it.<sup>26</sup>

Takayasu's arteritis is a chronic vasculitis of unknown aetiology that affects the aorta, its major branches, the pulmonary artery and the coronary arteries; it causes headache, absence of arterial pulses, heart failure, renovascular hypertension and ocular and cerebral ischemia. In contrast to GCA, Takayasu's arteritis primarily affects young people, especially women between 15 and 25, more commonly in Asian or Central-American populations.<sup>29</sup> In this vasculitis affecting large vessels, a patient has been described who presented sudden deafness and decreased pulse in the radial artery. The hearing condition worsened upon withdrawal of parenterally administered steroids and improved when they were reintroduced.<sup>30</sup>

Histopathological studies of the temporal bone are of great interest in patients with systemic vasculitis. Among them, those published for patients diagnosed with polyarteritis nodosa (PAN) should be highlighted. In a patient whose first manifestation of the disease was sudden unilateral deafness and vertigo, the temporal bone histopathological study showed bilateral cochlear condition in the form of loss of the organ of Corti in various portions of the cochlea, the absence of the tectorial membrane and atrophy of the stria vascularis, whereas no vestibular histopathological changes were observed.<sup>31</sup> In another patient with a diagnosis of PAN and unilateral profound hearing loss and vertigo, the histopathological study found vasculitis in the internal auditory artery, accompanied by ossification of the cochlea and the vestibular system as well as endolymphatic hydrops in the basal ramp of the cochlea.<sup>32</sup> The loss of sensory cells and neurons in the maculae of the semicircular canals,

**Table 3** Audiovestibular manifestations in systemic vasculitis

	Auditory manifestations	Vestibular manifestations
<b>Primary vasculitis</b>		
Predominantly affecting large vessels		
Giant cell arteritis	Reversible sensorineural hearing loss, sudden hearing loss, tinnitus	Vestibular hypofunction, BPPV (PSC>HSC), vertigo
Takayasu's arteritis	Sudden reversible hearing loss	Not described
Predominantly affecting medium vessels		
Classic PAN	Sensorineural hearing loss, sudden hearing loss	Vertigo
Kawasaki disease	Reversible sensorineural hearing loss, transmission hearing loss	Not described
Predominantly affecting medium and small vessels		
Wegener's granulomatosis	Serous otitis media, chronic otitis media, transmission hearing loss, sudden hearing loss, sensorineural hearing loss, tinnitus	Vertigo, central and peripheral nystagmus
Churg-Strauss syndrome	Serous otitis media, suppurating otitis media, sensorineural hearing loss	Not described
Microscopic polyangiitis	Sensorineural hearing loss, sudden hearing loss	Vertigo
Predominantly affecting small vessels		
Schönlein-Henoch purpura	Not described	Not described
Essential cryoglobulinemic vasculitis	Not described	Not described
Vasculitic urticaria	Not described	Not described
Skin leukocytoclastic angiitis	Not described	Not described
<b>Secondary vasculitis</b>		
Predominantly affecting medium and small vessels		
Rheumatoid arthritis	Transmission hearing loss, sudden hearing loss, sensorineural hearing loss	Not described
Scleroderma	Symmetrical and bilateral sensorineural hearing loss, BPPV (HSC>PSC) peripheral vestibular syndrome	
Systemic lupus erythematosus	Transmission hearing loss, sudden hearing loss	Not described
Sjögren's syndrome	Transmission hearing loss, sudden hearing loss	Not described
Predominantly affecting small vessels		
Behcet's disease	Sensorineural hearing loss, sudden hearing loss	Peripheral and central vestibular syndrome
Other vasculitis		
Cogan syndrome	Sensorineural hearing loss, tinnitus	Vertigo
Relapsing polychondritis	Sensorineural hearing loss, tinnitus	Peripheral vestibular syndrome

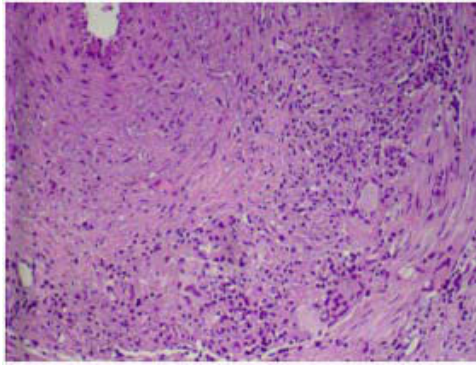
BPPV indicates benign paroxysmal positional vertigo; HSC, horizontal semicircular canal; PSC, posterior semicircular canal; PAN, panarteritis nodosa.

utricle and saccule has also been reported in PAN.<sup>33</sup> Most of the reported cases with a diagnosis of PAN met the criteria of the Chapel Hill Consensus Conference relative to microscopic polyangiitis.<sup>10</sup> Recently, the possibility has been described of obtaining a recovery of hearing through a cochlear implant in a patient diagnosed with PAN by biopsy. This reinforces the impression that the lesion is located at the cochlear level. In this group of patients with PAN and

profound bilateral hearing loss, this may be secondary to labyrinthine ischemia by a vascular phenomenon.<sup>34</sup>

Kawasaki disease (KD) is diffuse necrotizing vasculitis involving medium-sized vessels, with almost constant injury of the coronary arteries and large non-intraparenchymatous arteries. 85% of patients with KD are children under 5 in whom the disease occurs sporadically or in small outbreaks. It is predominant in males (1.5:1) and, although it is more





**Figure 2** Temporal artery showing the breakdown of the internal elastic lamina, diffuse chronic inflammatory infiltrate and some multinucleated giant cells, all characteristics of giant cells arteritis.

frequent in Japan, the disease has been diagnosed in more than 40 countries.<sup>35</sup> In a study of 62 patients diagnosed with KD, sensorineural hearing loss was described in the acute phase of the disease in 30% and conductive hearing loss in 9%. On examination of auditory function after the acute phase, neurosensory hearing loss persisted in 5.5% of patients, so the partially reversible character after treatment with steroids was confirmed.<sup>36</sup>

Wegener's granulomatosis is defined as a granulomatous inflammation that affects the airways combined with necrotizing vasculitis of small and medium vessels together with glomerulonephritis and positive cANCA.<sup>37</sup> In addition to the known hearing loss secondary to obstruction of the Eustachian tube due to granulomas in the nasopharynx, a series of 21 patients described sudden hearing loss and tinnitus.<sup>38</sup> Bilateral sensorineural hearing loss was observed in 12 of 13 patients with auditory symptoms in a series of 19 patients diagnosed with Wegener's disease by biopsy.<sup>39</sup> Some patients also described vestibular manifestations such as vertigo and peripheral nystagmus.<sup>40</sup>

Churg-Strauss allergic granulomatous vasculitis is characterised by granulomas in the upper airways, with eosinophilic infiltration and systemic vasculitis in medium and small vessels, along with a history of asthma, circulating eosinophilia and high concentrations of circulating IgE.<sup>37</sup> It has been linked with seromucinous otitis, acute otitis media and progressive sensorineural hearing loss in 9.5% of patients, who improved or stabilised after administration of steroids and immunosuppressors.<sup>41</sup>

Behcet's disease is a multisystemic, chronic and recurrent disease that almost always occurs with oral thrush and, in variable frequency, genital sores, uveitis, skin lesions and neurological, vascular and gastrointestinal manifestations<sup>42</sup> with a pathological substrate of leukocytoclastic or lymphocytic vasculitis, preferably from capillaries and venules. Auditory manifestations such as sudden deafness have been described, as well as vertigo during the course of the disease and in relapses.<sup>43,44</sup> Sensorineural hearing loss with a cochlear location was described in 30% of 62 patients diagnosed with Behcet's disease, and central vestibular syndrome<sup>45</sup> in 40%.

Cogan's syndrome is characterised by fluctuating hearing loss, tinnitus, spontaneous sudden vertigo, and interstitial keratitis. A significant alteration in the auditory and vestibular function has also been described. However, the reported damage is so severe that it does not seem to be the result of a true vasculitis, but rather of a primary labyrinthitis.<sup>46</sup>

Rheumatoid arthritis is a chronic, multisystemic inflammatory disease characterised by persistent inflammatory synovitis, usually involving peripheral joints in a symmetrical manner, predominantly the wrists, the metacarpophalangeal and proximal interphalangeal joints of the hands, elbows and knees and metatarsal-phalangeal of feet. It is more common in women; although its aetiology is unknown, there is a genetic predisposition, as shown by the tendency to familial aggregation, the high concordance with rheumatoid arthritis in monozygotic twins and the association with genes within the major histocompatibility complex, particularly with certain alleles that share a common sequence of amino acids within the hypervariable control region of the HLA-DRB1 chain, called shared epitope.<sup>47</sup> One study has linked the sudden hearing loss in patients with RA with an underlying vasculitic process affecting the eighth cranial nerve.<sup>48</sup>

In the town of Lugo, as in the Anglo-Saxon population, an association of rheumatoid arthritis with HLA-DR4 alleles has been observed, in particular with HLA-DRB1\*0401 and \*0404. These alleles have also been shown as markers of vascular damage in patients with rheumatoid arthritis in Lugo, since patients with these alleles are at increased risk of endothelial vascular dysfunction,<sup>49</sup> a marker of early-stage atherosclerosis and an increased risk of cardiovascular events.<sup>50</sup>

Interestingly, in a series of 33 patients diagnosed with idiopathic sudden hearing loss in our Lugo population, we also observed an association of HLA-DR4 with increased susceptibility to the disease and a worse prognosis for recovery with steroid treatment.<sup>51</sup> Consistent with this, an increased susceptibility to sensorineural hearing loss has been described in patients with rheumatoid arthritis with respect to a control group. Specifically, in a series of 194 patients diagnosed with rheumatoid arthritis, sensorineural hearing loss was described in 39%.<sup>52</sup> The coincidence of findings involving HLA-DR4 alleles with increased severity of rheumatoid arthritis<sup>47</sup> and its association with increased risk of vascular damage in this disease,<sup>49,50</sup> together with the finding of an increased risk of sudden deafness with worse functional outcome in people presenting HLA-DR4,<sup>51</sup> may indicate that these alleles would be true markers of endothelial vascular damage regardless of the underlying disease.

Scleroderma and systemic sclerosis are included in the collagenosis group. Systemic sclerosis is a disease characterised by excessive deposition of connective tissue and extracellular matrix proteins in different organs and tissues, and is more common in women. Its aetiology is unknown, but it is known to involve disorders of collagen synthesis as well as vascular and immune system abnormalities. Two clinical forms have been established: the limited and the diffuse variants. The predominate features in the limited form are Raynaud's phenomenon, clinical data defined in the CREST syndrome (calcinosis, Raynaud's phenomenon,



sclerodactyly, oesophageal disorders, and telangiectasia), increased risk of pulmonary hypertension and presence of positive antinuclear antibodies anticentromere B positive and distal skin condition in the extremities.<sup>53</sup> In the diffuse form, the predominate features are proximal skin condition and more intense injury to internal organs that leads to increased risk of pulmonary fibrosis and renal scleroderma crisis, typically associating with anti-SCL70 positive antibodies.<sup>53</sup>

Recently, in the population of Lugo, we have described hearing and vestibular alterations, as well as affectation of postural control of static balance in systemic sclerosis, both in limited and in diffuse forms. The aetiology is probably vasculitic, although a direct autoimmune mechanism in the inner ear can not be ruled out. In this patient group studied, we highlight symmetrical, bilateral sensorineural hearing loss, vestibular hypofunction on caloric testing and alterations in tests of cephalic agitation and oculocephalic manoeuvre.<sup>54</sup> We also describe a close association with benign paroxysmal positional vertigo. In the study of postural control through the clinical test of sensory interaction on balance (CTSIB), we found a predominance of vestibular patterns, ie, difficulty in maintaining balance in conditions 5 and 6 of that test. These findings show the existence of peripheral auditory and vestibular damage for the first time in patients with systemic sclerosis.<sup>55</sup>

Systemic lupus erythematosus (SLE) is the prototype of autoimmune disease, which primarily affects women between 15 and 50 and also causes secondary vasculitis.<sup>56</sup> Sensorineural hearing loss has been observed with relative frequency in this group of patients with SLE, and both autoimmune and vasculitic mechanisms<sup>57</sup> have been involved in its pathogenesis.

Hearing loss and vertigo of probable ischemic origin have been described in relapsing polychondritis, an autoimmune disease that affects, unilaterally or bilaterally, the cartilage of the ear, nose and trachea. Its pathophysiology has been explained assuming the existence of a vasculitis of the labyrinthine artery and its branches.<sup>58</sup>

Another disease involving audiovestibular manifestations and vasculitis is Sjögren's syndrome. This is a slowly progressing, chronic auto-immune disease, characterised by lymphocytic infiltration of exocrine glands, as well as hyper-reactivity and proliferation of B cells that end up producing xerostomia and dry eyes. It may be primary or secondary; in the latter case, it is accompanied by another auto-immune disease with systemic clinic, as occurs in 30% of patients. It mainly affects women between 40 and 50. Like SLE, Sjögren's syndrome also causes secondary vasculitis.<sup>56</sup> Sensorineural hearing loss concomitant with cardiolipin antibodies<sup>59</sup> has been described in 14 of 30 patients with Sjögren's syndrome. A sudden hearing loss has also been reported as initial and exceptional presentation in a case of Sjögren's syndrome.<sup>60</sup>

As for serological markers that could help diagnose diseases involving vascular damage, some studies suggest an aetiopathogenic role of anti-endothelial cell antibodies (AECA). These could be regarded as markers of immune-mediated vascular damage in vasculitis, as well as sudden hearing loss, where some authors assign it a direct involvement in physiopathology.<sup>61,62</sup> However,

in our population, we could not confirm the diagnostic or pathogenic role of AECA in patients diagnosed with GCA through temporal artery biopsy in whom alterations of vestibular function and sensorineural hearing loss had been confirmed.<sup>63</sup>

As far as we know, there is no specific marker to support the diagnosis of immune-mediated inner ear disease. We must suspect it based on a combination of a compatible clinic together with the findings derived from conducting vestibular, hearing and laboratory tests for each disease.

## Conclusions

The vasculitis forms are a heterogeneous group of diseases in which audiovestibular symptoms are relatively more common than was initially considered, both at the beginning of the vasculitis and in the evolution of the process. Studies confirm that the search for changes in auditory and vestibular tests shows both peripheral and central disorders. In addition, the audiovestibular alterations could be explained by an ischemic mechanism mediated by the inflammatory vasculitic phenomenon, but one cannot rule out the role of a direct autoimmune mechanism in some diseases of the inner ear.

## Conflict of interests

The authors declare no conflict of interests.

## References

1. Lie JT. Vasculitis, 1815 to 1991: classification and diagnostic specificity (Dunlop-Dottridge lecture). *J Rheumatol*. 1991; 19:19:83-89.
2. Gonzalez-Gay MA, García-Porrúa C. Etiopatogenia y clasificación de las vasculitis sistémicas. In: Alonso Ruiz A, Alvaro-Gracia Alvaro JM, Blanch i Rubio J, et al. (Ed.) *Manual SER de enfermedades reumáticas*. 3 ed., Madrid: Médica Panamericana; 2000. p. 349-54.
3. Gonzalez-Gay MA, García-Porrúa C. The epidemiology of the vasculitides. *Rheum Dis Clin North Am*. 2001;27:729-49.
4. Cid Xutgla MC, Coll-Vinent Puig B, Grau Junyent JM. Vasculitis: mecanismos patogenéticos de la inflamación vascular. In: Egido J, Gomez-Reino J, Herrero-Baumont G, Rodríguez de la Serna, editors. *Manual de inflamación*. Madrid: Medical & Marketing Communications; 1999. p. 367-91.
5. Zeek PM. Periarthritis nodosa: a critical review. *Am J Clin Pathol*. 1952;22:777-90.
6. Alarcon-Segovia D, Brown Jr AL. Classification and etiologic aspects of necrotizing angitis: an analytic approach to a confused subject with a critical review of the evidence for hypersensitivity in polyarteritis nodosa. *Mayo Clin Proc*. 1964;39:205-22.
7. Fauci AS, Haynes BF, Katz P. The spectrum of vasculitis: clinical, pathologic, immunologic, and therapeutic considerations. *Ann Intern Med*. 1978;89:660-76.
8. Hunder GG, Arend WP, Bloch DA, Calabrese LH, Fauci AS, Fries JF. The American College of Rheumatology 1990 criteria for the classification of vasculitis: introduction. *Arthritis Rheum*. 1990;33:1065-7.

9. Michel BA, HunderGG, Bloch DA, Calabrese LH. Hypersensitivity vasculitis and Henoch-Schönlein purpura: a comparison between the 2 disorders. *J Rheumatol.* 1992;19:721-8.
10. Jennette JC, Falk RP, Andrassy K, Bacon PA, Churg J, Gross, WL, et al. Nomenclature of systemic vasculitides. Proposal of an international consensus conference. *Arthritis Rheum.* 1994;37:187-192.
11. Gonzalez-Gay MA, Mantecon MA. Vasculitis sistémicas: Concepto y clasificación. In: Blanco Garcia FJ, Carreira Delgado P, Martin Mola E, et al. (Ed.). *Manual SER de enfermedades reumáticas.* Madrid: Medica Panamericana; 2004. p. 233-7.
12. McCabe BF. Autoimmune sensorineural hearing loss. *Ann Otol Rhinol Laryngol.* 1979;88:585-9.
13. Garcia Berrocal JR, Ramirez-Camacho R. Immuneresponse and immunopathology of the inner ear: an update. *J Laryngol Otol.* 2000;114:101-7.
14. Yoon TH, Paparella MM, Schachern PA. Systemic vasculitis: a temporal bone histopathologic study. *Laryngoscope.* 1989;99:600-609.
15. Gonzalez-Gay MA, Barros S, Lopez-Diaz MJ, Garcia-Porrúa C, Sanchez-Andrade A, Llorca J. Giant cell arteritis: disease patterns of clinical presentation in a series of 240 patients. *Medicine (Baltimore).* 2005;84:269-76.
16. Gonzalez-Gay MA. Giant cell arteritis and polymyalgia rheumatica: two different but often overlapping conditions. *Semin Arthritis Rheum.* 2004;33:289-93.
17. Gonzalez-Gay MA, García-Porma C, LlorcaJ, Hajeer AH, Branas F, Dababneh, A, et al. Visual manifestations of giant cell arteritis. Trends and clinical spectrum in 161 patients. *Medicine (Baltimore).* 2000;79:283-92.
18. Gonzalez-Gay MA, Garcia-Porrúa C, Vazquez-Caruncho M. Polymyalgia rheumatica in biopsy proven giant cell arteritis does not constitute a different subset but differs from isolated polymyalgia rheumatica. *J Rheumatol.* ;1998;25:1750-5.
19. Gonzalez-Gay MA, Garcia-Porrúa C, Llorca J, Gonzalez-Louzao C, Rodriguez-Ledo P. Biopsy-negative giant cell arteritis: clinical spectrum and predictive factors for positive temporal artery biopsy. *Semin Arthritis Rheum.* 2001;30:249-56.
20. Machado EB, Michet CJ, Ballard DJ, Hunder GG, Beard CM, Chu, CP, et al. Trends in incidence and clinical presentation of temporal arteritis in Olmsted County, Minnesota, 1950-1985. *Arthritis Rheum.* 1988;31:745-9.
21. Sonnenblick M, Neshet G, Friedlander Y, Rubinow A. Giant cell arteritis in Jerusalem: a 12-year epidemiological study. *Br J Rheumatol.* 1994;33:938-41.
22. Gonzalez-Gay MA, Blanco R, Sanchez-Andrade A, Vazquez-Caruncho M. Giant cell arteritis in Lugo (Spain): a more frequent disease with less classic features. *J Rheumatol.* 1997;24:2166-70.
23. Gonzalez-Gay MA, Garcia-Porrúa C, Rivas MJ, Rodriguez-Ledo P, Llorca J. Epidemiology of biopsy proven giant cell arteritis in northwestern Spain: trend over an 18 year period. *Ann Rheum Dis.* 2001;60:367-71.
24. Gonzalez-Gay MA, Miranda-Fillooy JA, Lopez-Diaz MJ, Perez-Alvarez R, Gonzalez-Juanatey C, Sanchez-Andrade A, et al. Giant cell arteritis in northwestern Spain: a 25-year epidemiologic study. *Medicine (Baltimore).* 2007;86:61-8.
25. Gonzalez-Gay MA, Garcia-Porrúa C, Amor-Dorado JC. Arteritis de células gigantes y polimialgia reumática. In: Ramos Casals M, Garcia Carrasco M, Gomez de Salazar JR, Calvo Alen J, Font Franco J, editors. *Enfermedades autoinmunes sistémicas y reumatológicas.* Barcelona: Masson; 2005. p. 197-209.
26. Amor-Dorado JC, Llorca J, Garcia-Porrúa C, Costa C, Perez-Fernandez N, Gonzalez-Gay MA. Audiovestibular manifestations in giant cell arteritis: a prospective study. *Medicine (Baltimore).* 2003;82:13-26.
27. Amor-Dorado JC, Llorca J, Costa-Ribas C, Garcia-Porrúa C, Gonzalez-Gay MA. Giant cell arteritis: a new association with benign paroxysmal positional vertigo. *Laryngoscope.* 2004;114:1420-1425.
28. Gonzalez-Gay MA, Garcia-Porrúa C, Amor-Dorado JC, Llorca J. Giant cell arteritis without clinically evident vascular involvement in a defined population. *Arthritis Rheum.* 2004;51:274-7.
29. Hall S, Barr W, Lie JT, Stanson AW, Kazmier FL, Hunder GG. Takayasu's arteritis: A study of 32 North American patients. *Medicine (Baltimore).* 1985;64:89-99.
30. Maruyoshi H, Toyama K, Kojima S, Kawano H, Ogata N, Miyamoto, S, et al. Sensorineural hearing loss combined with Takayasu's arteritis. *Intern Med.* 2005;44:124-8.
31. Jenkins HA, Pollak AM, Fisch U. Polyarteritis nodosa as a cause of sudden deafness. A human temporal bone study. *Am J Otolaryngol.* 1981;2:99-107.
32. Gussen P. Polyarteritis nodosa and deafness. A human temporal bone study. *Arch Otorhinolaryngol.* 1977;26:263-71.
33. Adkins WY, Ward PH. Temporal bone showing polyarteritis nodosa, otosclerosis, and occult neuroma. *Laryngoscope.* 1986;96:645-52.
34. Psillas G, Kyriafinis G, Danizilidis J. Polyarteritis nodosa and cochlear implantation. *J Laryngol Otol.* 2007;121:196-9.
35. Dym L. Kawasaki disease. *Curr Opin Rheumatol.* 1993;5:41-5.
36. Knott PD, Orloff LA, Harris JP, Novak RE, Burns JC, Kawasaki Disease Multicenter Hearing Loss Study Group. Sensorineural hearing loss and Kawasaki disease: a prospective study. *Am J Otolaryngol.* 2001;22:343-8.
37. Gonzalez-Gay MA, Garcia-Porrúa C, Guerrero J, Rodriguez-Ledo P, Llorca J. The epidemiology of the primary systemic vasculitides in northwest Spain: implications of the Chapel Hill Consensus Conference definitions. *Arthritis Rheum.* 2003;49:388-393.
38. Llompart X, Aumaitre O, Kemeny JL, Mom T, Gilain L. Early otorhinolaryngological manifestations of Wegener's granulomatosis. Analysis of 21 patients. *Ann Otolaryngol Chir Cervicofac.* 2002;119:330-6.
39. Kempf HG. Ear involvement in Wegener's granulomatosis. *Clin Otolaryngol.* 1989;14:451-6.
40. Bennett RW, Staker LV. Wegener's granulomatosis presenting as vertigo. *West J Med.* 1987;146:359-61.
41. Bacciu A, Bacciu S, Mercante G, Ingegnoli F, Grasselli C, Vaglio, A, et al. Ear, nose and throat manifestations of Churg-Strauss syndrome. *Acta Otolaryngol.* 2006;126:503-9.
42. Gonzalez-Gay MA, Garcia-Porrúa C, Branas F, Lopez-Leizaro L, Olivieri I. Epidemiologic and clinical aspects of Behcet's disease in a defined area of Northwestern Spain, 1988-1997. *J Rheumatol.* 2000;27:703-
43. Belkahlia A, Ben Ayed H, Ben H'Mida M, Hamza M. Auditory and vestibular lesions in Behcet's disease. *Ann Otolaryngol Chir Cervicofac.* 1982;99:469-76.
44. Narvaez J, Valverde-Garcia J, Alegre-Sancho JJ, Juanola X, Clavaguera MT, Roig-Escofet D. Sudden cochlear hearing loss in a patient with Behcet's disease. *Rev Rheum (Engl ed).* 1998;65:63-4.
45. Kulahti I, Balci K, Koseoglu E, Yuce I, Cagli S, SenturkM. Audiovestibular disturbances in Behcet's patients: report of 62 cases. *Hear Res.* 2005;203:28-31.
46. Schuknecht HF, Nadol Jr JB. Temporal bone pathology in a case of Cogan's syndrome. *Laryngoscope.* 1994;104:1135-42.
47. Gonzalez-Gay MA, Garcia-Porrúa C, Hajeer AH. Influence of human leukocyte antigen-DRB1 on the susceptibility and severity of rheumatoid arthritis. *Semin Arthritis Rheum.* 2002;31:355-60.
48. Merrin PK, Macfarlane DG. Vestibulocochlear dysfunction in a patient with rheumatoid disease and vasculitis. *Ann Rheum Dis.* 1991;50:393-4.
49. Gonzalez-Juanatey C, Testa A, Garcia-Castelo A, Garcia-Porrúa C, Llorca J, Vidan, A, et al. HLA-DRB1 status affects endothelial

- function in treated patients with rheumatoid arthritis. *Am J Med.* 2003;114:647-52.
50. Gonzalez-Gay MA, Gonzalez-Juanatey C, Lopez-Diaz MJ, Pineiro A, Garcia-Porrúa C, Miranda-Filloo JA, et al. HLA-DRB1 and persistent chronic inflammation contribute to cardiovascular events and cardiovascular mortality in patients with rheumatoid arthritis. *Arthritis Rheum.* 2007;57:125-32.
  51. Amor-Dorado JC, Paco L, Martin J, Lopez-Nevot MA, Gonzalez-Gay MA. Human leukocyte antigen-DQB1 and -DRB1 associations in patients with idiopathic sudden sensorineural hearing loss from a defined population of Northwest Spain. *Acta Otolaryngol.* 2005;125:1277-82.
  52. García Callejo FJ, Conill Tobías N, Muñoz Fernandez N, De Paula Vernetta C, Alonso Castaneira I, Marco Algarra J. Hearing impairment in patients with rheumatoid arthritis. *Acta Otorrinolaringol Esp.* 2007;58:232-8.
  53. Arias-Núñez MC, Llorca J, Vázquez-Rodríguez TR, Gómez-Acebo I, Miranda-Filloo JA, Martín J, et al. Systemic sclerosis in northwestern Spain: a 19-year epidemiologic study. *Medicine (Baltimore).* 2008;87:272-80.
  54. Amor-Dorado JC, Arias-Núñez MC, Miranda-Filloo JA, Gonzalez-Juanatey C, Llorca J, Gonzalez-Gay MA. Audiovestibular manifestations in patients with limited systemic sclerosis and centromere protein-B (CENP-B) antibodies. *Medicine (Baltimore).* 2008;87:131-41.
  55. Amor-Dorado JC, Barreira-Fernandez MP, Arias-Núñez MC, Gómez-Acebo I, Llorca J, Gonzalez-Gay MA. Benign paroxysmal positional vertigo and clinical test of sensory interaction and balance in systemic sclerosis. *Otol Neurotol.* 2008;29:1155-61.
  56. Gonzalez-Gay MA, García-Porrúa C. Systemic vasculitis in adults in northwestern Spain, 1988-1997. Clinical and epidemiologic aspects. *Medicine (Baltimore).* 1999;78:292-308.
  57. Andonopoulos AP, Naxakis S, Goumas P, Lygatsikas C. Sensorineural hearing disorders in systemic lupus erythematosus. A controlled study. *Clin Exp Rheumatol.* 1995;13:137-41.
  58. Schuknecht HF. Ear pathology in autoimmune disease. *Adv Otorhinolaryngol.* 1991;46:50-70.
  59. Tumiati B, Casoli P, Parmeggiani A. Hearing loss in the Sjogren syndrome. *Ann Intern Med.* 1997;126:450-3.
  60. García Berrocal JR, Arellano B, Vargas JA, Trinidad A, Ramírez Camacho R, Vergara J. Enfermedad inmunomediada del oído interno: Presentación de casos clínicos. *Acta Otorrinolaringol Esp.* 1997;48:565-70.
  61. Cadoni G, Fetoni AR, Agostino S, De Santis A, Manna R, Ottaviani F, et al. Autoimmunity in sudden sensorineural hearing loss: possible role of anti-endothelial cell autoantibodies. *Acta Otolaryngol Suppl.* 2002;548:30-3.
  62. Ottaviani F, Cadoni G, Marinelli L, Fetoni AR, de Santis A, Romito A, et al. Anti-endothelial autoantibodies in patients with sudden hearing loss. *Laryngoscope.* 1999;109:1084-7.
  63. Amor-Dorado JC, Garcia-Porrúa C, Gonzalez-Gay MA. Anti-endothelial cell antibodies and biopsy-proven temporal arteritis. *Lupus.* 2002;11:134.