

Maxillary Sinus Cancer Review in 23 Patients Treated With Postoperative Radiotherapy

Rubén D. Manrique,^a Leopoldo G. Deive,^a Michel A. Uehara,^b Roslyn K. Manrique,^c José L. Rodríguez,^a and Carmelo Santidrian^a

^aDepartamento de Otorrinolaringología, Hospital do Meixoeiro, Vigo, Pontevedra, Spain

^bDepartamento de Otorrinolaringología, Hospital La Fe, Valencia, Spain

^cDepartamento de Oftalmología, Hospital Universitario La Paz, Madrid, Spain

Objective: To describe the survival and outcome of maxillary sinus cancer in patients managed with surgery and post-operative radiotherapy during the last 10 years in our hospital.

Patients and method: Descriptive, retrospective, non-randomized study of 23 patients with cancer of the maxillary sinus managed at the Vigo University Hospital Complex, Spain, with radical surgery and post-operative radiotherapy, between 1995 and 2004.

Results: The 3-year actuarial survival was 47.8% and the adjusted actuarial survival was 60.8%. Permanent local tumour control was achieved in 60.8% of cases (14/23). Local tumour recurrence was the main cause of treatment failure (33.3%; 4/12). The most significant prognostic factors affecting local tumour control and survival were: clinical stage ($P < .031$), suprastructural location of the tumour ($P < .001$), and presence of positive resection margins ($P < .001$).

Conclusions: Local recurrence was found to be very high and generally the main cause of death. New treatment protocols should be assessed.

Revisión del cáncer del seno maxilar en 23 pacientes tratados con radioterapia posoperatoria

Objetivo: Describir el comportamiento del cáncer del seno maxilar y la experiencia acumulada durante 10 años en el manejo de este tipo de neoplasia en nuestro hospital mediante el tratamiento con cirugía y radioterapia postoperatoria.

Pacientes y método: El presente es un estudio descriptivo, retrospectivo y no aleatorizado, que se llevó a cabo en el Complejo Hospitalario Universitario de Vigo, con 23 pacientes con cáncer de seno maxilar que recibieron tratamiento con fines curativos entre los años 1995 y 2004. Todos fueron sometidos a cirugía radical y radioterapia postoperatoria.

Resultados: La supervivencia actuarial a 3 años fue del 47,8% y la corregida, del 60,8%. El control local permanente se consiguió en 14/23 (60,8%) pacientes. La causa principal de fracaso del tratamiento fue la recurrencia local 4/12 (33,3%). Los factores pronósticos más significativos que afectaron al control local y la supervivencia fueron: el estadio clínico ($p < 0,031$), la localización del tumor en la supraestructura ($p < 0,001$) y los márgenes de sección quirúrgicos positivos ($p < 0,001$).

Conclusiones: La recurrencia local es muy alta y generalmente la principal causa de muerte. Hay que explorar nuevos protocolos de tratamiento.

Key words: Maxillary sinus cancer. Post-operative radiotherapy. Actuarial survival.

Palabras clave: Cáncer de seno maxilar. Radioterapia postoperatoria. Supervivencia actuarial.

INTRODUCTION

Maxillary sinus cancer is relatively rare neoplasm, with an incidence representing a small percentage (0.2%) of human

malignant tumours, only 1.5% of all head and neck malignant neoplasms, and between 50% and 80% of tumours in the paranasal sinuses.^{1,2}

In most cases, tumours of the paranasal sinuses are discovered along with others in the nasal cavity, because in the vast majority of patients the cancer is diagnosed in advanced stages, making it difficult to determine the origin of the neoplasm.

These tumours tend to remain localized for a long time and during evolution they invade adjacent structures such as bone, base of the skull, facial soft tissue, oral cavity, and orbits.¹⁻⁴

The authors have not indicated any conflict of interest.

Correspondence: Dr. R.D. Manrique.
Puerto Rico, 14, 3.º C. 36204 Vigo. Pontevedra. España.
E-mail: rben03811@hotmail

Received May 21, 2007.

Accepted for publication October 15, 2007.

Nowadays, it is generally accepted that the best treatment for maxillary sinus cancer is surgery plus radiotherapy⁵⁻⁸; nevertheless, in more advanced stages, both surgery and radiotherapy have limitations. Even where resection of the maxillary sinus is possible, the extension of the tumour outside the confines of the sinus makes it impossible for surgeons to resect the entire area affected without mutilation of the patient and with the danger of spreading tumour cells during the procedure.

Taking into account the publications reporting better results with combined treatment,⁵⁻⁹ patients diagnosed with maxillary sinus cancer at the Vigo University Hospital Complex (CHUVI in its Spanish acronym) were treated from 1995 to 2004 with surgery and postoperative radiotherapy. The objective of this paper is to describe the behaviour of maxillary sinus cancer and the experience gained in handling this type of cancer at our hospital for 10 years through treatment with surgery and postoperative radiotherapy.

PATIENTS AND METHOD

This is a non-randomized, descriptive, retrospective, longitudinal study covering the years between 1995 and 2004. In this period, 45 patients were treated at CHUVI for maxillary sinus cancer; of these, 51.1% (23) received curative therapy; 22 (48.9%) patients were excluded from the study because of non-epithelial histology type or very advanced disease; they were considered inoperable and were given palliative therapy, usually chemotherapy, and radiotherapy.

The treatment used was surgery plus postoperative radiotherapy applied after 8 (2) weeks. Patients considered operable were included after a detailed, joint assessment of the extent of the disease involving the otorhinolaryngologist, the maxillofacial surgeon, and the radiotherapist.

In tumours of the infrastructure or the suprastructure where it was possible to preserve the orbital contents due to the absence of bone infiltration (bottom of the orbit), the operation performed was upper jaw resection (UJR) with emptying of the homolateral nostril, including resection of the ethmoidal cells and preserving the papyraceous plate of the ethmoid. After resection of the surgical piece, samples were taken from the sphenoid sinus and pterygomaxillary fossa for the corresponding histopathology study, making it possible to determine the compromised areas in which microscopic residues have remained, thus allowing the radiotherapist to plan the most adequate irradiation fields.

In cases where the bottom of the orbit was affected (bone infiltration), patients also underwent exenteration. In patients with clinically positive nodes, a modified radical neck dissection was conducted (MRND).

The tumour was irradiated: *a*) if the surgical resection was complete and the margins were free of disease (>1 cm), the dose was 50-55 Gy; *b*) if the surgical resection was complete but the proximal edges were positive (>1 cm), the dose used was 60 Gy; *c*) if there was contact with the edges, the dose was 66 Gy; and *d*) if the edges were positive, the dose was 70 Gy.

The classification used to stage the cases was the TNM system proposed by the fifth edition of the American Joint Committee on Cancer (AJCC).¹⁰

Statistical analysis was performed by the epidemiology service at Meixoeiro Hospital. In the comparison of survival in relation to age, gender, histological type, degree of tumour differentiation, location of the suprastructure or infrastructure, and positive or negative surgical section margins, the χ^2 test was used for proportions and Student's *t* for means. The actuarial and corrected survival rates were calculated for 3 years. The confidentiality of the data was preserved to ensure the ethical nature of this paper.

RESULTS

The mean age was 63 years (48-87) at the time of diagnosis, more frequent in males (2.8 men for every woman). The most common symptom leading to consultation was pain in 15 patients (62.2%) and nasogenian tumour in 14 (60.8%). Symptoms were generally varied: nasal obstruction (11), epistaxis (8), nasal secretion (6), visual abnormality (4), epiphora (3), gingival tumour (3), palatal tumour (2), cervical tumour (2), ulceration of the chin (1), and bleeding gums (1). These appeared in most cases, depending on whether the location of the tumour was in the suprastructure or infrastructure of the maxillary sinus (defined by the Ohngren's line).

The radiological findings showed that 90% of patients had involvement of the medial wall of the maxillary sinus and 68% the lateral wall. In 59% of cases, the bottom part of the orbit or the ethmoidal cells were affected. There was destruction of the cheek bone and the alveolus in 43.5% and 38.7%, respectively. Involvement of the back wall of the maxillary sinus and the pterygoid plate was observed in 35.5% to 29% of patients.

Among the histological varieties found, adenocarcinoma accounted for the highest incidence with 11 cases (47.8%), squamous cell carcinoma in 7 (30.4%), and cystic adenoid carcinoma in 5 (21.7%).

In 10 cases (43.4%), the orbit could be preserved, while in 13 (56.6%) with orbital floor involvement the exenteration of the orbit was carried out in conjunction with resection of the maxillary sinus. MRND was performed in 2 cases (8.7%).

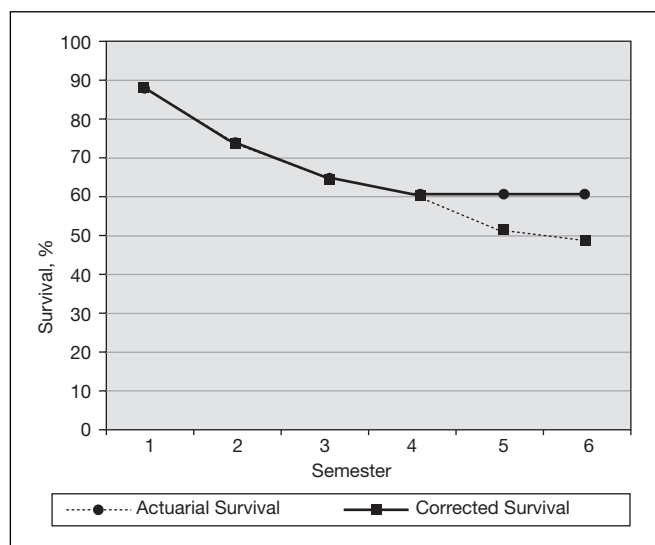
There were only 2 cases classified as T₂: one of them was disease-free during the follow-up period and the other died from other causes 33 months later, with the primary tumour under control.

Of the 17 patients grouped as T₃, 9 (39.1%) are alive and with no evidence of disease. In this group, 1 patient was classified as T₃ N₁ and was remained disease-free during the follow-up period. The survival of patients classified as T₃ N₀ was 50% (8/16). In this group, 1 patient died of intercurrent non-neoplastic disease 2 years after treatment and 1 patient developed a second primary cancer (of the uterus, lung, and stomach), which was the cause of death as the primary tumour of the maxillary sinus was under control. Only 33.3% (1/3) of T₄ N₀ patients are alive and

Table 1. Causes of Treatment Failure

<i>Cause</i>	<i>Patients, n (%)</i>
Local recurrence	4 (33.3)
Persistence of the disease	3 (25.7)
Remote metastasis	1 (8.3)
Non-neoplastic intercurrent disease	1 (8.3)
Second primary tumour	1 (8.3)
Unknown	2 (16.7)
Total	12 ^a

^aTwelve patients died during the 3-year follow-up.

**Figure.** Actuarial and corrected survival after 3 years.

with no evidence of disease. The patient classified as T₄ N₁ died 7 months after treatment.

Two patients (8.7%) were at clinical stage II, 73.9% (17 patients) were clinical stage III, and 17.4% (4 patients) were clinical stage IV. One patient in group T₃ (4.3%) and 1 in group T₄ (4.3%) presented metastatic nodes in the neck.

Among the causes of treatment failure (Table 1) it was found that local recurrence in the irradiated area was the major cause of failure: 7 out of 12 patients (58.3%) had local recurrence (4 patients) or persistent disease (3 patients). Recurrences took place mostly in the first 2 years of follow-up. Remote metastasis was present in 1 patient (8.3%), 1 died from a second primary cancer, 1 due to intercurrent non-neoplastic disease, and 2 for unknown reasons.

Acute treatment-related complications such as radioepithelitis and moderate to severe mucositis occurred in 56.5% of patients (13/23). Most of these patients recovered from the acute symptoms 2 weeks after irradiation with topical and symptomatic treatment.

As for later complications, constant tear production was observed in 2 patients, 1 patient developed trismus (he had been re-irradiated in the orbital area due to recurrence) and fibrosis in the neck was observed in 1 case.

Table 2. Survival After 3 Years by Type of Surgery^a

<i>Type of Surgery</i>	<i>Survival, n/N</i>	<i>%</i>
UJR	5/8	62.5
UJR + exenteration of orbit	5/13	38.5
UJR + MRND	1/2	50
Total	11/23	47.8

^aMRND indicates modified radical neck dissection; UJR, upper jaw resection.

Table 3. Survival After 3 Years by Stage and T N M

<i>TNM</i>	<i>Stage</i>	<i>Survival, n/N</i>	<i>%</i>
T ₂ N ₀ M ₀	II	1/2 ^a	50
T ₃ N ₀ M ₀	III	8/16 ^{a,b}	50
T ₃ N ₁ M ₁	III	1	100
T ₄ N ₀ M ₀	IV	1/3	33.3
T ₄ N ₁ M ₀	IV	0	0
Total		11/23	47.8

^a1 case died due to other causes with the primary maxillary sinus tumour under control.

^b1 case died due to another primary tumour; the primary maxillary sinus tumour was under control.

Actuarial survival after 3 years for the 23 patients treated (Figure) was 47.8% (11/23) and corrected survival (considering patients who died from other causes but without evidence of disease) was 60.8% (14/23). Permanent local control was achieved in 60.8% (14/23).

According to the histology results, adenocarcinomas, the most frequent group of carcinomas, were found to have the best survival rate: 54.5% (6/11); in squamous cell and cystic adenoid carcinomas, survival was 42.8% and 40% (3/7 and 2/5, respectively).

With regard to survival and type of surgery (Table 2), we can see that more than 50% of patients undergoing UJR with or without MRND are alive and with no evidence of disease. However, only in 38.5% of patients undergoing UJR + orbital exenteration was the disease under control after 3 years. Most of the patients with suprastructure cancer were subjected to exenteration of the orbit because it was affected. The survival at 3 years of patients with cancer of the infrastructure was of 52% whereas it was only 24% ($P < .001$) among those with cancer of the suprastructure.

One of the findings in terms of local disease control had to do with whether or not the surgical margins were affected: 56.5% of cases had infiltrated surgical margins in the histological examination of the surgical sample. Only 46.1% (6/13) of patients with positive surgical margins had the disease under control after 3 years, while 80% (8/10) of patients with negative surgical margins were alive and without evidence of disease after 3 years ($P < .001$).

Depending on the stage (Table 3), survival was 52.9% for clinical stage III, 50% for clinical stage II, and 25% for clinical stage IV ($P = .031$).

DISCUSSION

Patients with maxillary sinus cancer usually arrive at the hospital with advanced tumours. Of 45 patients, only 23 could be treated (51.1%) with curative intent. The other 22 (48.9%) were treated with palliative radiotherapy and chemotherapy. It is interesting to note that in recent years the results of treatment have not changed much. In our series, inoperable advanced cases are slightly fewer (22/23) than in the curative treatment group, often due to the delay in obtaining a proper diagnosis, or because the patients arrived at the hospital from remote locations without the possibility of specialized medical care.

The delay in diagnosis (the fact that the otolaryngologist does not have this disease in mind) has been documented by Wille¹¹ in 220 patients; the symptoms of 171 were treated between 6 and 26 months for chronic inflammatory processes before the correct diagnosis was reached.

In our series, 90% of patients had bone destruction at the time of their hospital admission, which is indicative of advanced disease. Similar findings have been published.^{2,12-14} Poor results obtained in the short term are due to the fact we are confronted with patients with T₃-T₄ tumours. In addition, the symptoms are unfortunately easily confused, in initial stages, with allergic or inflammatory processes, leading to a delay in obtaining a correct diagnosis.

Most studies^{7,8,15,16} show a clear prevalence among men, in a ratio of 2:1. This study found a ratio of 2.8 men for every woman (17/6). Men went to the hospital at an earlier stage and a greater proportion of women arrived at inoperable stages.

There is a lot of speculation about the possible aetiological factors of this malignancy in most published series^{2,6}; adenocarcinomas of the nasal cavity and ethmoidal sinus have been linked to workers in the timber and leather industry,¹⁷ and this study found that 63.6% (7/11) of patients with a histological diagnosis of adenocarcinoma were carpenters.

Symptoms vary greatly and depend on the extent and location of the tumour, its growth rate, size, volume, and whether or not there is metastasis. Frequently the symptoms are not proportional to the extension of the tumour. The most common symptoms were: pain, nasogenian tumour, abnormal vision, nasal obstruction, and secretion. Authors such as Grossman et al¹⁸ and Osborn et al¹⁹ found that nasal obstruction was the most common symptom; for others, such as Salem et al,¹² it was pain.

The most common histological type in our series was adenocarcinoma (11 cases, 47.8%), as opposed to squamous cell carcinoma reported by most authors.^{2,6,12,14} This may be due to factors such as genetic susceptibility or immunodeficiency, which in our series were few cases, as it is a rare condition.¹

Survival in relation to histological type was similar in squamous cell carcinoma, adenocarcinoma, and cystic adenoid carcinoma, and the trend towards improved survival in adenocarcinomas is striking. Klintenberg et al¹⁵ reported good radiosensitivity in this group of tumours.

The most important prognostic factors were: clinical stage, location of the tumour in the suprastructure or infrastructure, and whether or not the surgical margins were affected. The last 2 were the most significant ($P < .001$).

The incidence of lymph node metastasis ranged from 7% to 22%²⁰⁻²² (most series report an incidence of about 10%^{14,21}). We found neck metastasis at the time of diagnosis in only 8.7% of cases (2/23), despite the fact that 91.3% of our patients were classified as T₃-T₄. Most of the series showed a survival below 15% after 5 years when there was lymph node involvement at the time of diagnosis.^{5,14,21,22} Prophylactic treatment of the nodes studied as N₀ is controversial; there are series which show ganglion relapses above 29% in untreated N₀ cases.^{2,22,23}

Another prognosis factor with statistical significance relates to the location of the primary tumour in the maxillary sinus. Like most other publications,^{14,24,25} we found that patients with tumour in the infrastructure have a better survival rate than those with tumours in the suprastructure. Survival after 3 years was 52% and 24% respectively ($P = .001$). Local recurrence in lesions to the infrastructure was lower due to improved access for adequate surgical resection.

As for the relationship with the condition of the surgical resection margins, of the 13 patients with affected surgical margins, only 6 (46.1%) are alive and free of disease after 3 years. Of the 10 remaining patients with negative margins, 8 (80%) show no evidence of disease ($P < .001$), which means that the use of postoperative radiotherapy, at the doses employed in the group with affected surgical margins, has not been sufficiently effective in completely eliminating the residual disease. This could be because the air spaces of the paranasal sinuses are difficult to quantify in terms of the irradiation dosage, often applied subjectively.²⁶ Looser et al²⁷ compared the clinical significance of positive and negative margins in 1775 patients. The incidence of recurrences in the location of the primary tumour was 31.7% of the patients with free margins and 71% in those with affected margins.

Local recurrence remains the main problem of treatment failure (Table 1).^{11,14,15} In 33.3% (4/12), recurrences were in the irradiated volume, and 1 recurrence was in the orbit, which had been protected from the irradiation beam to preserve vision. The orbit should be included at the slightest suspicion of likely microscopic disease. Recent improvements in the use of conformal radiotherapy and in modulating the intensity of radiation have allowed greater precision in the treatment of tumours of the paranasal sinuses, protecting vital structures adjacent to the tumour, however, this technique does not provide therapeutic benefits.²⁸ Boone et al³ reported an 11% incidence of lymph node and remote metastasis. Distant metastasis in our series was 4.3% (1 patient).

As can be seen, local recurrence remains very high and is generally the main cause of death, therefore new surgical techniques, different radiotherapy segmentation schemes, and the use of neoadjuvant chemotherapy must be explored in order to improve local control of this disease and survival.

Clinical stage is an important prognostic factor. The histological type and grade had no influence on local control or survival. Tumours located on the infrastructure have a

better prognosis than those located on the superstructure. Local control and survival are better for patients who have negative section margins.

REFERENCES

- Núñez F, Suárez C, Álvarez I, Losa JL, Barthe P, Fresno M. Sino-nasal adenocarcinoma: Epidemiological and clinico-pathological study of 34 cases. *J Otolaryngol*. 1993;22:86-90.
- Paulino AC, Marks JE, Bricker P, et al. Results of treatment of patient with maxillary sinus carcinoma. *Cancer*. 1998;83:457-65.
- Boone LM, Harbe TH. Malignant disease of paranasal sinuses and the nasal cavity. *AJR Am J Roentgenol*. 1968;102:627-38.
- Frich JC. Treatment of advanced squamous cell carcinoma of the maxillary sinus. *Int J Radiat Oncol*. 1982;8:1452-9.
- Bristol IJ, Ahamad A, Garden AS, et al. Postoperative radiotherapy for maxillary sinus cancer: long-term outcomes and toxicities of treatment. *Int J Radiat Oncol Biol Phys*. 2007;68:719-30.
- Hoppe BS, Stegman LD, Zelefsky MJ, et al. Treatment of nasal cavity and paranasal sinus cancer with modern radiotherapy techniques in the postoperative setting—the MSKCC experience. *Int J Radiat Oncol Biol Phys*. 2007;67:691-702.
- Kawashima M, Ogino T, Hayashi R, et al. Influence of postsurgical residual tumor volume on local control in radiotherapy for maxillary sinus cancer. *Jpn J Clin Oncol*. 2001;31:195-202.
- Tiwari R, van der Wal J, van der Waal I, Snow G. Studies of the anatomy and pathology of the orbit in carcinoma of the maxillary sinus and their impact on preservation of the eye in maxillectomy. *Head Neck*. 1998;20:193-6.
- Bryce DP. Cancer of the antrum. In: Gates GA, editor. *Current therapy in otolaryngology-head and neck surgery*. Philadelphia: Mosby; 1984. p. 1984-5.
- American Joint Committee on Cancer. *Manual for staging of cancer*. Philadelphia: JB Lippincott; 1992.
- Wille C. Malignant tumours in the nose and its accessory sinuses. *Acta Otolaryngol*. 1947; Suppl 65.
- Salem LE, Zaharia M, Travezan R. Carcinoma of the paranasal sinuses. *Am J Surg*. 1963;106:826-30.
- Holsti LR, Rinne R. Treatment of malignant tumors of paranasal sinuses. *Acta Radiol (Stockh)*. 1967;6:337-50.
- Ohngren LG. Malignant tumours of the maxillo-ethmoid region. *Acta Otolaryngol Suppl*. 1933;19:1.
- Giri SP, Ready E, Gerner L, et al. Management of advanced squamous cell carcinoma of the maxillary sinus. *Cancer*. 1992;69:657-61.
- Tsujii H, Kamada T, Arimoto T, Mizoe J, Shirato N, Matsuoka Y, et al. The role of radiotherapy in the management of maxillary sinus carcinoma. *Cancer*. 1990;57:2261-6.
- Acheson ED, Macbeth M, Hodfield EH. Carcinoma of the nasal cavity and accessory sinuses in wood workers. *Lancet*. 1967;1311.
- Grossman AA, Donnelly WA, Snitman MF. Management of malignancy of maxillary sinuses. *CMAJ*. 1950;62:576-84.
- Osborn DA, Winston L. Carcinoma of the paranasal sinuses. *J Laryngol*. 1961;71:387-405.
- Ahmad K, Cordoba RB, Fayos JV. Squamous cell carcinoma of the maxillary sinus. *Arch Otolaryngol*. 1981;107:48-51.
- Jiang GL, Ang KK, Peters LJ, Wendt CD, Oswald MJ, Goepfert H. Maxillary sinus carcinomas: natural history and results of postoperative radiotherapy. *Radiat Oncol*. 1991;21:193-200.
- Paulino AC, Fisher SG, Marks JE. Is prophylactic neck irradiation indicated in patients with squamous cell carcinoma of the maxillary sinus? *Clin Invest Radiat Oncol Biol Phys*. 1997;39:283-9.
- Jiang GL, Ang KK, Peters LJ, Wendt CD, Oswald MJ, Goepfert H. Maxillary sinus carcinomas: natural history and results of postoperative radiotherapy. *Radiat Oncol*. 1991;21:193-200.
- Jesse R. Preoperative vs. postoperative radiotherapy in the treatment of squamous cell carcinoma 57 paranasal sinuses. *Am J Surg*. 1965;110:552-6.
- Waldron JN, O'Sullivan B, Gullane P, et al. Carcinoma of the antrum maxillary: a retrospective analysis of the 110 cases. *Radiat Oncol*. 2000;57:167-73.
- Lohr F. Conformal three-dimensional photon radiotherapy for paranasal sinus tumors. *Radiat Oncol*. 2000;56:227-31.
- Looser KG, Shah JP, Strong EW. Significance of positive margins in surgically resected epidermoid carcinoma. *Head Neck Surg*. 1978;1:107-11.
- Adams EJ, Nutting CM, Convery DJ, et al. Potential role of intensity-modulated radiotherapy in the treatment of tumors of the maxillary sinus. *Int J Radiat Oncol Biol Phys*. 2001;51:579.