



CONTENTS	
1	DESCRIPTION OF THE SURAL NERVE AND ITS RELATION TO INVASIVE TECHNIQUES IN PHYSICAL THERAPY
2	ORIGINAL ARTICLE
3	ORIGINAL ARTICLE
4	ORIGINAL ARTICLE
5	ORIGINAL ARTICLE
6	ORIGINAL ARTICLE
7	ORIGINAL ARTICLE
8	ORIGINAL ARTICLE
9	ORIGINAL ARTICLE
10	ORIGINAL ARTICLE
11	ORIGINAL ARTICLE
12	ORIGINAL ARTICLE
13	ORIGINAL ARTICLE
14	ORIGINAL ARTICLE
15	ORIGINAL ARTICLE
16	ORIGINAL ARTICLE
17	ORIGINAL ARTICLE
18	ORIGINAL ARTICLE
19	ORIGINAL ARTICLE
20	ORIGINAL ARTICLE
21	ORIGINAL ARTICLE
22	ORIGINAL ARTICLE
23	ORIGINAL ARTICLE
24	ORIGINAL ARTICLE
25	ORIGINAL ARTICLE
26	ORIGINAL ARTICLE
27	ORIGINAL ARTICLE
28	ORIGINAL ARTICLE
29	ORIGINAL ARTICLE
30	ORIGINAL ARTICLE
31	ORIGINAL ARTICLE
32	ORIGINAL ARTICLE
33	ORIGINAL ARTICLE
34	ORIGINAL ARTICLE
35	ORIGINAL ARTICLE
36	ORIGINAL ARTICLE
37	ORIGINAL ARTICLE
38	ORIGINAL ARTICLE
39	ORIGINAL ARTICLE
40	ORIGINAL ARTICLE
41	ORIGINAL ARTICLE
42	ORIGINAL ARTICLE
43	ORIGINAL ARTICLE
44	ORIGINAL ARTICLE
45	ORIGINAL ARTICLE
46	ORIGINAL ARTICLE
47	ORIGINAL ARTICLE
48	ORIGINAL ARTICLE
49	ORIGINAL ARTICLE
50	ORIGINAL ARTICLE
51	ORIGINAL ARTICLE
52	ORIGINAL ARTICLE
53	ORIGINAL ARTICLE
54	ORIGINAL ARTICLE
55	ORIGINAL ARTICLE
56	ORIGINAL ARTICLE
57	ORIGINAL ARTICLE
58	ORIGINAL ARTICLE
59	ORIGINAL ARTICLE
60	ORIGINAL ARTICLE
61	ORIGINAL ARTICLE
62	ORIGINAL ARTICLE
63	ORIGINAL ARTICLE
64	ORIGINAL ARTICLE
65	ORIGINAL ARTICLE
66	ORIGINAL ARTICLE
67	ORIGINAL ARTICLE
68	ORIGINAL ARTICLE
69	ORIGINAL ARTICLE
70	ORIGINAL ARTICLE
71	ORIGINAL ARTICLE
72	ORIGINAL ARTICLE
73	ORIGINAL ARTICLE
74	ORIGINAL ARTICLE
75	ORIGINAL ARTICLE
76	ORIGINAL ARTICLE
77	ORIGINAL ARTICLE
78	ORIGINAL ARTICLE
79	ORIGINAL ARTICLE
80	ORIGINAL ARTICLE
81	ORIGINAL ARTICLE
82	ORIGINAL ARTICLE
83	ORIGINAL ARTICLE
84	ORIGINAL ARTICLE
85	ORIGINAL ARTICLE
86	ORIGINAL ARTICLE
87	ORIGINAL ARTICLE
88	ORIGINAL ARTICLE
89	ORIGINAL ARTICLE
90	ORIGINAL ARTICLE
91	ORIGINAL ARTICLE
92	ORIGINAL ARTICLE
93	ORIGINAL ARTICLE
94	ORIGINAL ARTICLE
95	ORIGINAL ARTICLE
96	ORIGINAL ARTICLE
97	ORIGINAL ARTICLE
98	ORIGINAL ARTICLE
99	ORIGINAL ARTICLE
100	ORIGINAL ARTICLE

## ORIGINAL ARTICLE

# Description of the sural nerve and its relation to invasive techniques in physical therapy

Alejandro López-Ferraz<sup>a,\*</sup>, Francisco J. Valderrama-Canales<sup>b</sup> and Fermín Valera-Garrido<sup>c</sup>

<sup>a</sup> Fisioterapia Gonion, Tenerife, Canarias, Spain; Departamento de Fisioterapia, Universidad de La Laguna, Tenerife, Canarias, Spain

<sup>b</sup> Centro de Donación de Cuerpos y Salas de Disección, Universidad Complutense de Madrid; Departamento de Anatomía y Embriología Humanas, Facultad de Medicina, Universidad Complutense de Madrid, Madrid, Spain

<sup>c</sup> MVClinic, Madrid, Spain; Real Madrid C.F.; Facultad de Medicina, Universidad San Pablo CEU, Madrid, Spain

### KEYWORDS

Sural nerve;  
Achilles tendon  
(calcaneal tendon);  
Invasive procedures;  
Physiotherapy

### Abstract

**Introduction:** The sural nerve is a sensory nerve that runs down the posterior leg reaching the lateral aspect of the Achilles tendon, and running parallel to it, until the retromalleolar course of the nerve. The use of invasive physiotherapy techniques in the territory of the sural nerve compromises its integrity.

**Objectives:** To describe the relationship of the sural nerve with the Achilles tendon and adjacent structures in order to determine safe approach routes in invasive physiotherapy procedures.

**Material and methods:** 10 legs from embalmed corpses were analysed with the epifascial plane dissected in the dorsal region. The distance from the point of insertion of the Achilles tendon was measured to the point at which the sural nerve crosses over the tendon. The distance was also measured between the said crossing point and the musculotendinous junction of the Achilles tendon with the gastrocnemius muscle, and the lateral distances between the Achilles tendon and the sural nerve at 3, 5, 7, 9 and 10 cm from the calcaneal tendon insertion.

**Results:** The crossing point of the sural nerve on the Achilles tendon occurred at an average distance of 105.37 mm (SD: 12.87) from the insertion point of the tendon on the calcaneus. In relation to the gastrocnemius musculotendinous junction, the crossing point of the sural nerve on the tendon occurred at an average distance of 83.44 mm (SD 9.49). In half of the cases the lateral distance was progressively greater in the distal direction. In all cases, the maximum lateral distance was reached at 3 cm from the calcaneal tendon insertion.

**Conclusions:** The sural nerve has a direct anatomical relationship with the Achilles tendon. The variability of this and the proximity of both structures preclude the establishment of safe areas by manual approach guidance. Therefore, ultrasound-guided approaches are recommended during invasive techniques applied in this region.

© 2016 MVClinic. Published by Elsevier España, S.L.U. This is an open access article under the CC BY-NC-ND license (<http://creativecommons.org/licenses/by-nc-nd/4.0/>).

\*Corresponding author.

E-mail address: alexlopez20\_04@hotmail.com (A. López Ferraz).

**PALABRAS CLAVE**

Nervio sural;  
Tendón de Aquiles  
(tendón calcáneo);  
Procedimientos  
invasivos;  
Fisioterapia

**Descripción del nervio sural y su relación con los abordajes invasivos de fisioterapia****Resumen**

**Introducción:** El nervio sural es un nervio sensitivo que tras recorrer la cara posterior de la pierna alcanza el borde lateral del tendón de Aquiles y discurre paralelo a él hasta el recorrido retromaleolar del nervio. La utilización de técnicas de fisioterapia invasiva en torno al territorio del nervio sural compromete su integridad.

**Objetivos:** Describir la relación del nervio sural con el tendón de Aquiles y las estructuras adyacentes para determinar vías de abordaje seguras en los procedimientos invasivos de fisioterapia.

**Material y métodos:** Se analizaron 10 piernas de cadáveres embalsamados, con el plano superficial de la región posterior disecado. Se midió la distancia del punto de inserción del tendón de Aquiles hasta el punto de cruce del nervio sural sobre dicho tendón, entre dicho punto de cruce y la unión miotendinosa del tendón de Aquiles con los gastrocnemios, y las distancias laterales entre el tendón de Aquiles y el nervio sural a 3, 5, 7, 9 y 10 cm de la inserción tendinosa.

**Resultados:** El punto de cruce del nervio sural sobre el tendón de Aquiles se estableció a una distancia promedio del punto de inserción del tendón en el calcáneo de 105,37 mm (DE: 12,87). El cruce del nervio sural sobre el tendón respecto a la unión miotendinosa del gastrocnemio se estableció a una distancia promedio de 83,44 mm (DE: 9,49). En la mitad de los casos la distancia lateral es progresivamente mayor en sentido distal. En todos los casos, la máxima distancia lateral se alcanza a 3 cm de la inserción del tendón en el calcáneo.

**Conclusiones:** El nervio sural guarda una relación anatómica directa con el tendón de Aquiles. La variabilidad de la relación y la proximidad de ambas estructuras impiden establecer zonas seguras de abordaje mediante guía manual, por lo que se recomienda el abordaje ecoguiado de las técnicas de fisioterapia invasiva en la región.

© 2016 MVClinic. Publicado por Elsevier España, S.L.U. Este es un artículo open access distribuido bajo los términos de la licencia CC BY-NC-ND (<http://creativecommons.org/licenses/by-nc-nd/4.0/>).

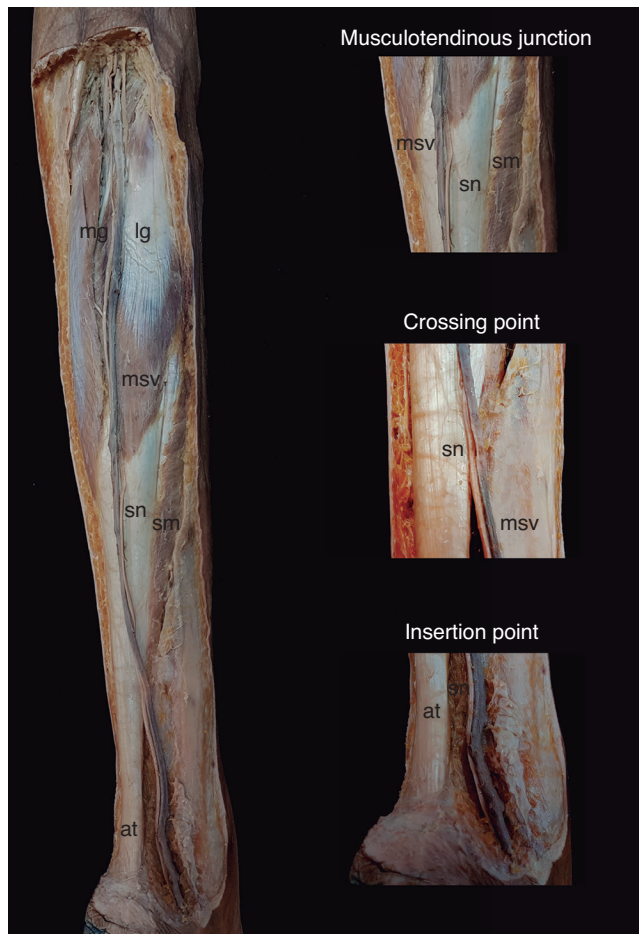
**Introduction**

The sural nerve is a sensitive nerve formed by the union of the medial sural nerve, a branch of the tibial nerve and the communicating peroneal branch coming from the common peroneal nerve, either directly or via a lateral sural branch. After passing between the two heads of the gastrocnemius muscles, lateral and medial, it perforates the sural fascia, normally in the middle third, in order to meet the small saphenous vein and receive the communicating peroneal branch. Thus, it reaches the lateral border of the Achilles tendon (calcaneal tendon) and the lateral calcaneal branch originates from one of its main collateral branches. After its retromalleolar passage and upon reaching the styloid process of the 5<sup>th</sup> metatarsal bone, there is certain variability in its divisions, as it always supplies the lateral dorsal branch of the fifth toe, however it can provide, in total, the last three dorsal digital nerves of the foot. In this case, the dorsal medial nerve of the 5<sup>th</sup> toe also originates from the sural nerve, together with the dorsal digital nerve of the 4<sup>th</sup> toe<sup>1</sup> (fig. 1).

In the scientific literature, anatomic studies of the sural nerve both on cadavers<sup>2,3</sup> as well as *in vivo* with ultrasound analysis<sup>4,5</sup> describe the variability of the same with different localisation patterns. Specifically, Kammar et al.<sup>5</sup> performed an ultrasound study on 66 subjects of different ages and genders, which indicated that the lateral disposition of the sural nerve in relation to the Achilles tendon is variable. In this sense, the systematic review and metaanalysis pub-

lished by Ramakrishnan et al. in 2015<sup>6</sup> concludes that, among the population, anatomical variations in the formation and course of the sural nerve are common and that, professionals, especially surgeons, must bear this circumstance in mind in order to avoid iatrogenic injuries during surgical procedures. Webb et al.<sup>7</sup> have described sural nerve injuries in up to 14% of patients after percutaneous repairs of the Achilles tendon, and Park et al.<sup>8</sup> conclude that approximately 25% of people treated with radiofrequency for venous recanalisation in the lower limbs suffer from neuritis of the sural nerve, which, in some cases, may last for over 15 months. In physiotherapy, no studies to this date have analysed the adverse effects associated with the application of invasive procedures over the area, which could eventually injure the sural nerve. However, Valera and Minaya<sup>9</sup> have described the potential existing risk associated with the application of percutaneous needle electrolysis in the interphase between the Achilles tendon and Kager's fat pad in an approach performed from lateral to medial (fig. 2).

In the daily practice of the physiotherapist, injuries affecting structures on the posterior aspect of the leg are common (i.e. lesions of the Achilles tendon, soleus, gastrocnemius, tibialis posterior or flexor hallucis longus muscles). In athletes, chronic Achilles tendinopathy is one of the most common affectations, especially in runners and sports involving jumping. According to Kujala et al.<sup>10</sup>, long distance runners have a risk of up to 52% of suffering an injury to the Achilles tendon throughout their life. In 2010, direct strength measurements performed by Doral et al.<sup>11</sup> revealed

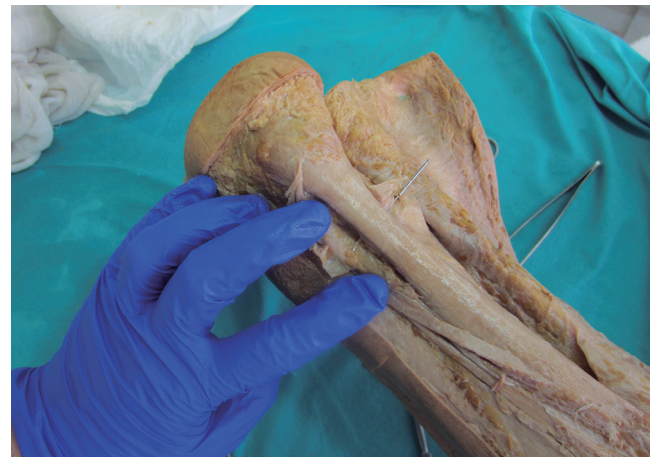

**Figure 1** Dissection of the posterior leg region. The tributaries of the small saphenous vein (msv) have been removed to enable a better view of the sural nerve (sn). Three relevant areas for this study are displayed in detail: the distal leg region, the crossing point of the sural nerve (sn) with the lateral border of the Achilles tendon (at) and the crossing point of the sural nerve (sn) with the musculotendinous junction of the medial and lateral gastrocnemius (mg, and lg, respectively). A partial view of the soleus muscle (sm) is also displayed. Orientation; p (proximal); l (lateral or external).

that, during a sprint, the Achilles tendon supports loads of up to 12.5 times the total body weight. However, a study by Ames et al.<sup>12</sup> mentions the opposite extreme, concluding that 30% of patients with chronic Achilles tendinopathy are people who live a sedentary lifestyle.

Regarding the clinical location, Khan-Farooqui and Andersson<sup>13</sup> reported that, between 2 and 6 cm distance proximal to the enthesis lies the least vascularised area of the Achilles tendon, and thus the area most susceptible to suffering degeneration.

Among the many techniques used in daily physiotherapy clinical practice for the treatment of tendinopathies, in general<sup>14</sup>, and for the treatment of Achilles tendinosis, in particular<sup>15</sup>, as well as for the various painful disorders of muscular origin affecting the posterior leg, invasive procedures are highlighted, such as percutaneous needle electrolysis for tendinopathies<sup>16,17</sup>. This recent technique is increasingly used today, in addition to other invasive techniques such as dry needling for pathologies with muscle origins<sup>18</sup>.



**Figure 2** Cadaveric approach on the Achilles tendon-Kager's fat interphase in the medial to lateral direction.

The present study aims to provide relevant information regarding the sural nerve, concerning its position, its course, and its relation with the Achilles tendon and the adjacent structures in order to establish, if possible, criteria of uniformity and safety in invasive physiotherapy treatments in the area surrounding this nerve.

## Material and methods

### Study design and selection of the cadaveric sample

An observational descriptive study was performed at the Centro de Donación de Cuerpos de la Universidad Complutense de Madrid [Centre of Organ Donations of the Complutense University of Madrid] (UCM).

For the study a sample of ten prosection samples was used, taken from human embalmed cadavers, provided by the Centro de Donación de Cuerpos de la UCM; these pieces had previously been dissected under supervision of professors with expertise.

The cadavers from where the prosection samples were obtained, were processed for their conservation according to the guidelines of the Centro de Donación de Cuerpos de la UCM<sup>20</sup>.

### Inclusion criteria

Cadaveric lower limb specimens (whether or not these were obtained from complete cadavers), which had previously undergone a dissection of the superficial plane of the posterior leg region. The inclusion criteria, given that these were cadaveric pieces donated by a public institution, basically consisted of the availability and suitability of the same. These are samples used specifically for study by both students and health professionals. Therefore, at the time of our research, we selected those pieces where the dissection plane performed was correct and which conserved, intact and in position, the structures that were the objective of the study: i.e. leg and foot contained in the piece, superficial plane dissection (subcutaneous or epifascial), small saphenous vein conserved in its course, sural nerve conserved in its course, and conserved Achilles tendon. According to

these criteria, 10 suitable samples were obtained for the purpose of performing the measurements (fig. 3).

The ethical criteria for this study is considered fulfilled *per se*, as the criteria for voluntary donations has been followed<sup>21,22</sup>, knowing the purposes for which these were performed.

### Description of the distances and their measurements (fig. 3)

**Distance A.** This was the distance between the insertion point of the Achilles tendon on the calcaneus and the crossing point between the sural nerve and said tendon on its lateral border. The insertion point is defined as the most prominent point of the insertion of the Achilles tendon on the posterosuperior aspect of the calcaneus. The crossing point is the site on the lateral border of the Achilles tendon, where the sural nerve makes contact with the same in order to then become superficial to the tendon and run over its posterior aspect.

In order to perform the measurements, one of the external jaws of the digital calliper was placed on the insertion point, and another was placed on the horizontal representation of the crossing point of the nerve on the lateral tendon border.

**Distance B.** The distance between the musculotendinous junction of the lateral gastrocnemius with the Achilles tendon and the crossing point for the sural nerve and Achilles tendon on its lateral border. The musculotendinous junction was defined as the most distal point in which the presence of muscle fibre from the lateral gastrocnemius muscle was visible over the Achilles tendon and the crossing point of the sural nerve, as for the previous measurement.

**Distance C.** The lateral distance between the sural nerve and the Achilles tendon at 3, 5, 7, 9 and 10 cm from the insertion of said tendon.

The point of reference was an imaginary sagittal line passing through the centre of the tendon body in order to separate this into two equal parts. The insertion point was defined as described in distance A.

A measurement of the lateral horizontal distance was made between the Achilles tendon and the sural nerve, at 3, 5, 7, 9 and 10 cm from the tendinous insertion point.

### Data collection protocol

The variables under study were the distances between the structures defined as the object of study (fig. 3). These are continuous quantitative variables, expressed in millimetres (mm). An electronic digital calliper with a LCD Screen was used as a tool for taking measurements (Vernier type), with a mean measuring range from 0-150 mm, and a resolution of  $\pm 0.01$  mm, with an exactitude of  $\pm 0.02$  mm ( $< 100$  mm) and of  $\pm 0.03$  mm ( $> 100$ -200 mm). The calliper is constituted by outer jaws for measuring the external dimensions of an object and inside jaws for measurements of internal dimension, together with a rod for measuring depth.

For the measurement of all distances, three measurements were made and the mean of all three was registered.

Besides the measurements, photographs of each sample were taken for the identification of relevant structures. A NIKON D3200 camera was used with a Nikon DX 18-55 mm lens (Nikon corporation, Tokyo, Japan).

### Statistical analysis

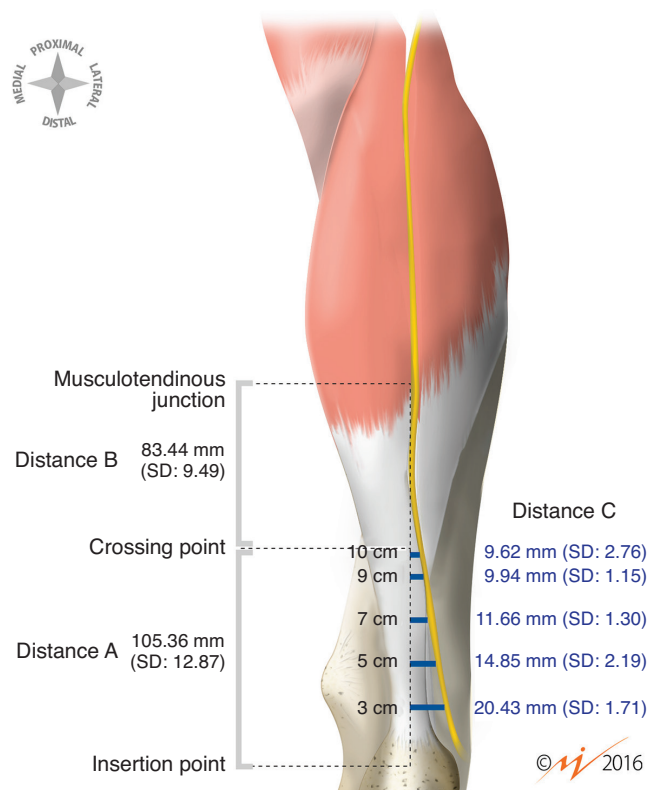
The data were collected and treated using a SPSS 22.0. statistics program (SPSS, Chicago, IL, USA). The mean, standard deviation, maximum and minimum values were calculated, as well as correlations between the continuous quantitative study variables. A calculation of the different correlations between measured distances was performed, in order to assess whether anthropometric guidelines exist which may influence the localisation and arrangement of the structures under study.

### Results

Measurements of the sural nerve were performed in 10 lower limbs, throughout the course of the same, until the passage of the nerve towards the dorsolateral aspect of the foot, bearing in mind its relation with relevant structures found in its course, especially regarding the gastrocnemius muscle and the Achilles tendon. This is due to the importance of these structures during invasive physiotherapy approaches.

In all cases, we found that the sural nerve establishes contact with the lateral border of the Achilles tendon, below the musculotendinous junction of the lateral gastrocnemius, in order to then move towards a posterior plane accompanied by the saphenous vein, situated medial to the same in 100% of the cases.

The descriptive statistics for the measurements performed are shown in table 1. The crossing point of the sural



**Figure 3** Description of the measurements and their results.



**Table 1** Descriptive statistics. Mean, minimum, maximum and standard deviation of each measurement

	Minimum	Maximum	Mean	Standard deviation
Distance A (calcaneus-crosspoint)	82.60	120.47	105.36	12.87
Distance B (musculotendinous-crosspoint)	65.13	96.69	83.44	9.49
Distance C (laterality-3 cm)	17.81	22.73	20.43	1.71
Distance C (laterality-5 cm)	10.76	18.14	14.84	2.08
Distance C (laterality-7 cm)	9.56	13.24	11.66	1.30
Distance C (laterality-9 cm)	8.39	11.18	9.93	1.15
Distance C (laterality-10 cm)	6.32	13.42	9.62	2.76

nerve over the lateral border of the Achilles tendon occurs at a mean distance of 105.36 mm (SD: 12.87) from the insertion point of the tendon on the calcaneus. The maximum distance found in this sample was 120.47 mm whereas the minimum found was 82.60 mm.

The crossing point of the sural nerve over the tendon in relation to the musculotendinous junction of the gastrocnemius occurred in this sample at an average distance of 83.44 mm (SD: 9.49). The maximum distance found was 96.69 mm, whereas the minimum distance found was 65.13 mm.

In 7 of 10 cases (70%), the distance between the tendon insertion on the calcaneus and the crossing point of the nerve was greater than the distance between the said crossing point and the musculotendinous junction of the Achilles tendon with the lateral gastrocnemius muscle.

In 5 of the 10 cases (50%), the lateral distance is progressively greater in the distal direction from 10 to 3 cm, as measured in this study, whereas in the other 5, this rule is

not followed, and a slight increase of the lateral distance occurs in the section between 7 and 10 cm distance above the insertion.

In all cases, the maximum lateral distance (mean = 20.43, SD: 1.71 mm) is reached at the lowest point of the measurements performed, that is, at 3 cm from the insertion of the tendon on the calcaneus.

In 50% of the cases, the smaller lateral distance was found at the highest point of the measurements performed in the study, at 10 cm from the insertion, whereas in 4 of the cases (40%), this minimal lateral distance was located at 9 cm and, in only one case (10%), this minimal distance was found at 7 cm.

As observed in table 2, there is a strong positive correlation (0.74) between the distances of the insertion of the tendon on the calcaneus and the crossing point of the sural nerve on the same and the distance between the said crossing point and the musculotendinous junction of the Achilles tendon-gastrocnemius.

**Table 2** Correlations between the different measures

	Correlations		
	Distance B (myotendinous-crosspoint)	Distance C (laterality-3 cm)	Distance C (laterality-5 cm)
Distance A (calcaneus-crosspoint)	.074	-.465	-.738
Distance B (musculotendinous-crosspoint)	1	.345	-.031
Distance C (laterality-3 cm)	.345	1	.538
Distance C (laterality-5 cm)	-.031	.538	1
Distance C (laterality-7 cm)	-.591	.045	.491
Distance C (laterality-9 cm)	-.125	.390	.414
Distance C (laterality-10 cm)	-.357	.260	.650
	Distance C (laterality-7 cm)	Distance C (laterality-9 cm)	Distance C (laterality-10 cm)
Distance A (calcaneus-crosspoint)	-.276	-.291	-.629
Distance B (musculotendinous-crosspoint)	-.591	-.125	-.357
Distance C (laterality-3 cm)	.045	.390	.260
Distance C (laterality-5 cm)	.491	.414	.650
Distance C (laterality-7 cm)	1	.653	.730
Distance C (laterality-9 cm)	.653	1	.707
Distance C (laterality-10 cm)	.730	.707	1

In general, a negative correlation (weak at 7 and 9 cm with values of  $-.276$  and  $-.291$ , respectively, moderate at 3 and 10 cm with values of  $-.465$  and  $-.629$ , respectively, and strong at 5 cm with a value of  $-.738$ ) exists between the distance of the insertion of the tendon on the calcaneus to the crossing point and the lateral measurements of the sural nerve to the tendon at different heights.

Likewise, a negative correlation (weak at 5, 9 and 10 cm with values of  $-.031$ ,  $-.125$  and  $-.357$  respectively or moderate at 7 cm with a value of  $-.591$ ) between the distance from the crossing point of the sural nerve and the musculotendinous junction and the lateral distances of the sural nerve to the tendon at different heights was found. This tendency is not followed in the correlation of both marks at 3 cm from the insertion, in which a weak positive correlation was found ( $0.34$ ).

## Discussion

A large number of invasive procedures, both diagnostic (neurological studies of conduction and biopsies) and therapeutic (surgical, medical and physiotherapy related) are performed on the posterior leg area close to the sural nerve<sup>2,6,23</sup>. Nieto et al.<sup>2</sup>, for instance, describe posterolateral surgical approaches performed on the tibia and fibula

or the liberation of compartments in compartmental syndromes. In addition, a variety of invasive approaches are currently being performed in physiotherapy (such as dry needling, electrolysis, acupuncture, mesotherapy or neuromodulation, among others) for the treatment of the Achilles tendon, the gastrocnemius muscles and adjacent structures (fig. 4).

Injuries to the sural nerve, as with all neuropathies affecting a sensitive nerve, produce clinical symptoms consisting of paraesthesia, numbness, or pain, on the lateral aspect of the ankle and foot, without motor symptoms<sup>2</sup>.

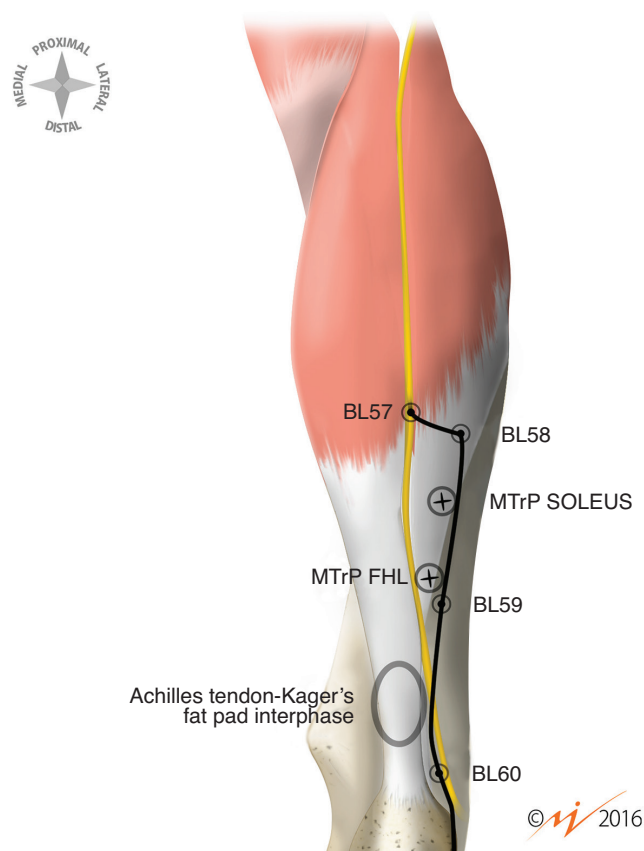
Based on the observations and descriptions performed in the present study, we conclude that, in all cases, the crossing point between the sural nerve and the Achilles tendon takes place at a distance of 105.36 mm (SD: 12.87), which differs from Kammar in 2014<sup>5</sup>, in which they reported an average of 116.8 mm. Most likely, this difference is explained by the fact that this study was performed upon cadaveric specimens, which influences the state of dehydration of the tissues, as well as other variables, such as the age and gender of the subjects. Both this measurement and that of the distance between the crossing point of the nerve over the tendon and the musculotendinous junction of the gastrocnemius muscles appear to be highly influenced by the height of individuals. Indeed, the latter measurement with a mean of 83.44 mm (SD: 9.49) is not mentioned in other studies, however we believe this to be an interesting finding in relation to clinical approaches. Regarding this aspect, one of the limitations of the present study is that it was not possible to perform anthropometric measurements, nor collect data from all the samples regarding age and gender. Nonetheless, the various previous studies<sup>24-27</sup> did not encounter differences between the different trajectory patterns of the sural nerve.

Regarding the lateral distances of the sural nerve in relation to the Achilles tendon at the different heights used as references, it is especially interesting to note that, despite the small sample, in all cases we found that the greater lateral distance was always found on the lowest point of the performed measurements (3 cm), this coincides with the study by Kammar et al.<sup>5</sup>. Although the measurements do not coincide, they are greater in the present study than in the previously cited report<sup>5</sup>, however they are lower than those found in the study by Nieto et al.<sup>2</sup> and similar to those reported by Nandra et al.<sup>30</sup>.

## Implication of the results in invasive physiotherapy approaches

Among the different Achilles tendon injuries that are clinically approached with invasive physiotherapy techniques, tendinosis is described as the most common<sup>31</sup>. Tendinosis is a term that has been widely accepted in the recent literature in patients with a chronic condition associated with pain and loss of function and with structural changes visible in imaging tests<sup>32</sup>.

The most common area for chronic injuries has been defined as that between 2 and 6 cm from the insertion, due to the poor vascularisation of the area<sup>2</sup>. Ultrasound studies performed in B mode and Doppler have demonstrated areas of degeneration and an increase of blood flow associated with neovascularisation in this area of injury, mainly upon



**Figure 4** Relation between the sural nerve in the area of risk and the different invasive physiotherapy techniques. Symbol +: localization of the myofascial trigger point (MTrP); BL57, BL58, BL59, BL60: acupuncture points for the bladder meridian; oval shaped area: body of the Achilles tendon.

the ventral aspect of the Achilles tendon<sup>32</sup>. The results of our study, despite its limitations, demonstrate that, under no circumstances, is a transversal approach of the interphase between the ventral zone of the Achilles tendon and the Kager's fat pad performed in the lateral to medial direction safe, due to the fact that the presence of all levels of the sural nerve entails a high risk of injury to this structure. These findings confirm and support the methodology described by Valera and Minaya in the approach of this area with percutaneous electrolysis<sup>9</sup> (fig. 4).

Regarding the transverse approach in the medial to lateral direction<sup>9</sup>, this can be considered safer, as long as one considers that, in the case of surpassing the total tendon width with the needle, there is an important risk of coming into contact with the sural nerve on the opposite side and, therefore, in the case of the application of an electric current such as percutaneous nerve electrolysis, this would cause an important injury of the same.

In the case of the treatment of the deep insertional fascicle of the Achilles tendon on the calcaneus or targeted at the paratendon<sup>9</sup>, obviously there is a lower risk of injury to the sural nerve.

According to our findings, there is certain variability in the distance between the lateral border of the tendon and the sural nerve. Furthermore, we have verified that there is a greater risk the closer one is from the insertion to the musculotendinous junction of the Achilles tendon, although a direct proportion cannot be established. This circumstance is especially important for the acupuncture points BL57 and BL58 of the bladder meridian<sup>33</sup>, which are located in the proximity of the musculotendinous junction of the Achilles tendon, where the sural nerve is epifascial. In the case of points BL59 and BL60 regarding the tendon body, it would be equally possible to damage the nerve (fig. 4).

In the sample studied, the difference between the tendinous insertion and the crossing point of the sural nerve is confirmed to be always greater than the distance between the said crossing point and the musculotendinous junction of the gastrocnemius, and these present a strongly positive correlation between each other. In other words, it is expected that when one increases, so will the other. Regarding this fact, we would expect greater distances in taller individuals. This correlation between both distances is worth considering in approaches using dry needling<sup>28</sup> of the trigger point (MTrP)<sup>3</sup> of the soleus muscle classically described by Travell and Simons in 1992<sup>29</sup>, and the MTrP of the flexor hallucis longus (fig. 4) which is found in the same area. Due to the variability in the height of the crossing point of the sural nerve over the Achilles tendon and its course along the posterior aspect of the area occupied at greater depth by the soleus muscle and the flexor hallucis longus, ultrasound-guided dry needling is recommended in order to minimize risks.

The data extracted from the present study allows us to affirm that it is not possible to perform an exact estimation of the ideal length of the needle used for the intervention nor the depth of the application of the technique in a way that is completely exempt from risks, without the support of imaging.

For all the above, and based on the potential risks, we recommend, in any case, the performance of ultrasound-guided applications in conjunction with invasive physiotherapy techniques upon the Achilles tendon and tissues

adjacent to the sural nerve. In this sense, the study by Ricci et al.<sup>34</sup> (2010) concludes that in 39 out of 40 lower limbs studied (97%) it was possible to identify the sural nerve. More recently, the study by Rodríguez-Acevedo et al. (2016) on the sonoanatomy of the sural nerve concluded that in 100% of cases it was possible to identify the nerve under ultrasound in a sample of 115 subjects, and that, in 44.3% of the cases, anatomic variations were evidenced.

## Study limitations and future recommendations

In the first place, the main limitation is the sample size, which is considered small ( $n = 10$ ). In future studies it would be recommendable to confirm the results with a greater sample in order to obtain more significant information. Despite this, the results obtained coincide with the majority of previously published studies<sup>4,5,7</sup>.

In second place, the study was performed using previously performed dissections of embalmed cadavers. In this sense, the tissues subjected to the process of embalming lose elasticity and the original properties of the tissue due to this process. A study by Cutts<sup>35</sup> (1988) regarding the contraction of muscle fibres during the fixation of cadaveric tissue described the existence of a small, but significant, loss of longitude of muscles subjected to this process. For all the above reasons, it would be recommendable to replicate this study on fresh cadavers or otherwise on dissections performed purposely for the study, which may offer more valid information regarding the analysed structures.

Thirdly, the measurements were performed using a manual instrument and in a single plane. It would be recommendable to use imaging software with computerised measurements taken on photographic images, which would enable the performance of measurements in the sagittal plane. This is an aspect that is important for the precise determination of the position of the structures. Additionally, this would provide greater exactitude and reproducibility of the study under the same conditions.

Lastly, we recommend that the data obtained be contrasted with measurements of the same structures in living individuals using ultrasound studies. In this sense, a factor worth considering is the change in the structure and muscle function in relation to a person's age, as described by Faulkner et al.<sup>36</sup>. Human skeletal muscle suffers atrophy as something inherent to ageing with a decrease of the transverse fibre area and the number of the same. These values are similar between 20 and 50 years, however, between 50 and 80 years of age, they are reduced to 50%, which may alter the measurements performed between subjects.

## Acknowledgments

We wish to thank the Centro de Donación de Cuerpos of the UCM, Spain, as well as Professor Dr. Francisco José Valderrama-Canales for his dedication, predisposition and knowledge, and, above all, for the passion towards his work, which he instils so well and which should be an example for all health professionals.

Our gratitude goes out to all those who selflessly collaborate with science via the donation of their bodies, as well as their family members for allowing us to advance science.

## References

- Vega J, Golanó P, Martínez M, Pérez-Carro L, de Prado M. Neuropatías compresivas de tobillo y pie. Bases anatómicas. *Orthotips* 2006;2(4):305-20.
- Nieto JL, Vergara Amador E, Amador JA. Nervio sural: estudio anatómico y consideraciones clínicas. *Colomb Med* 2009;40:252-8.
- Shankar N, Selvam RP, Dhanpal N, Reddy R, Alapati A. Anatomical variations of the sural nerve in the leg: a fetal study. *Neurol India* 2010 Jan-Feb;58(1):24-8.
- Rodríguez-Acevedo O, Elstner K, Zea A, Diaz J, Martinic K, Ibrahim N. The sural nerve: Sonographic anatomy, variability and relation to the small saphenous vein in the setting of endovenous thermal ablation. *Phlebology* 2016 Jan 28.
- Kammar H, Carmont MR, Kots E, Laver L, Mann G, Nyska M, et al. Anatomy of the sural nerve and its relation to the Achilles tendon by ultrasound examination. *Orthopedics* 2014;37(3):e298-e301.
- Ramakrishnan PK, Henry BM, Vikse J, Roy J, Saganiak K, Mizia E, et al. Anatomical variations of the formation and course of the sural nerve: A systematic review and meta-analysis. *Ann Anat* 2015 Nov;202:36-44.
- Webb J, Moorjani N, Radford M. Anatomy of the sural nerve and its relation to the Achilles tendon. *Foot Ankle Int* 2000 Jun;21(6):475-7.
- Park JY, Galimzahn A, Park HS, et al. Midterm results of radio-frequency ablation for incompetent small saphenous vein in terms of recanalization and sural neuritis. *Dermatol Surg* 2014;40:383-9.
- Valera Garrido F, Minaya Muñoz F. *Electrolisis percutánea musculoesquelética ecoguiada*. Barcelona: Elsevier, 2017 (in press).
- Kujala UM, Sarna S, Kaprio J. Cumulative incidence of Achilles tendon rupture and tendinopathy in male former elite athletes. *Clinical Journal of Sport Medicine* 2005;15(3):133-5.
- Doral MN, Alam M, Bozkurt M, Turhan E, Atay OA, Dönmez G, et al. Functional anatomy of the Achilles tendon. *Knee Surgery, Sports Traumatology, Arthroscopy* 2010;18(5):638-43.
- Ames PRJ, Longo UG, Denaro V, Maffulli N. Achilles tendon problems: not just an orthopaedic issue. *Disabil Rehabil* 2008;30(20-22):1646-50.
- Khan-Farooqi W, Anderson RB. Achilles tendon evaluation and repair: what primary care physicians need to know to make the diagnosis and referral. *The Journal of Musculoskeletal Medicine* 2010;27(4):188.
- Long L, Briscoe S, Cooper C, Hyde C, Crathorne L. What is the clinical effectiveness and cost-effectiveness of conservative interventions for tendinopathy? An overview of systematic reviews of clinical effectiveness and systematic review of economic evaluations. *Health Technol Assess* 2015 Jan;19(8):1-134.
- Habets B, van Cingel RE. Eccentric exercise training in chronic mid-portion Achilles tendinopathy: a systematic review on different protocols. *Scand J Med Sci Sports* 2015 Feb;25(1):3-15.
- Valera-Garrido F, Minaya-Muñoz F, Sánchez-Ibáñez J. Efectividad de la electrolisis percutánea intratisular (EPI®) en las tendinopatías crónicas del tendón rotuliano. *Trauma Fund MAPFRE* 2010;21(4):227-36.
- Minaya Muñoz F, Valera Garrido F, Sánchez Ibáñez JM, Medina Mirapeix F. Estudio de coste-efectividad de la electrolisis percutánea intratisular (EPI®) en las epicondralgias. *Fisioterapia: revista de salud, discapacidad y terapéutica física* 2012;34(5):208.
- Morihisa R, Eskew J, McNamara A, Young J. Dry needling in subjects with muscular trigger points in the lower quarter: a systematic review. *Int J Sports Phys Ther* 2016 Feb;11(1):1-14.
- Maranillo E, Valderrama-Canales FJ, Rodríguez-Vázquez JF, Sañudo JR, Pascual-Font A, Vázquez MT. Guides and protocols for a good practice. III. The dissection. *Eur J Anat* 2015;19(Suppl 1):29-30.
- Valderrama-Canales FJ, Rodríguez-Vázquez JF, Vázquez MT, Maranillo E, Pascual-Font A, Sañudo JR. Guides and protocols for a good practice. II. Traceability of the cadaver: From reception to removal. *Eur J Anat* 2015;19(Suppl 1):25-8.
- Doñate F. Ethical and legal aspects of corpse donation. *Eur J Anat* 2015;19(Suppl 1):5-8.
- Rodríguez-Vázquez JF, Vázquez T, Valderrama-Canales FJ, Maranillo E, Sañudo JR, Pascual-Font A. Guides and protocols for a good practice. I. Act of donation and donation card. *Eur J Anat* 2015;19(Suppl 1):23-4.
- Eid EM, Hegazy AM. Anatomical variations of the human sural nerve and its role in clinical and surgical procedures. *Clin Anat* 2011 Mar;24(2):237-45.
- Strauch B, Goldberg N, Herman CK. Sural nerve harvest: Anatomy and technique. *J Reconstr Microsurg* 2005;21:133-6.
- Pimentel ML, Fernandes RMP, Babinski MA. Anomalous course of the medial sural cutaneous nerve and its clinical implications. *Braz J Morphol Sci* 2005;22:179-82.
- Mahakkanukrauh P, Chomsung R. Anatomical variations of the sural nerve. *Clin Anat* 2002;15:263-6.
- Aktan Ikiz ZA, Uçerler H, Bilge O. The anatomic features of the sural nerve with an emphasis on its clinical importance. *Foot Ankle Int* 2005;26:560-7.
- Valera Garrido F, Minaya Muñoz F. *Fisioterapia invasiva*. Barcelona: Elsevier, 2013.
- Travell JG, Simons, DG. *Myofascial Pain and Dysfunction: The Trigger Point Manual*. Baltimore, MD: Williams & Wilkins, 1983.
- Nandra RS, Matharu GS, Porter KM. Acute Achilles tendon rupture. *Trauma* 2012;14(1):67-81.
- Maffulli N. Overuse tendon conditions: time to change a confusing terminology. *Arthroscopy: The Journal of Arthroscopic & Related Surgery* 1998;14(8):840-3.
- Sunding K, Fahlström M, Werner S, Forssblad M, Willberg L. Evaluation of Achilles and patellar tendinopathy with greyscale ultrasound and colour Doppler: using a four-grade scale. *Knee Surg Sports Traumatol Arthrosc* 2016 Jun;24(6):1988-96.
- Focks C. 2 ed. *Atlas de acupuntura*. Barcelona: Elsevier; 2009.
- Ricci S, Moro L, Antonelli Incalzi R. Ultrasound imaging of the sural nerve: ultrasound anatomy and rationale for investigation. *Eur J Vasc Endovasc Surg* 2010;39:636-41.
- Cutts A. Shrinkage of muscle fibres during the fixation of cadaveric tissue. *J Anat*. 1988 Oct;160:75-8.
- Faulkner JA, Larkin LM, Claflin DR, Brooks SV. Age-related changes in the structure and function of skeletal muscles. *Clinical and Experimental Pharmacology and Physiology* 2007;34(11):1091-6.