



IMAGE OF THE MONTH

Floating membranes in PAIR

Membranas flotantes visualizadas durante PAIR

Moinak Sen Sarma*, Surender Kumar Yachha

Sanjay Gandhi Postgraduate Institute of Medical Sciences, Lucknow, India

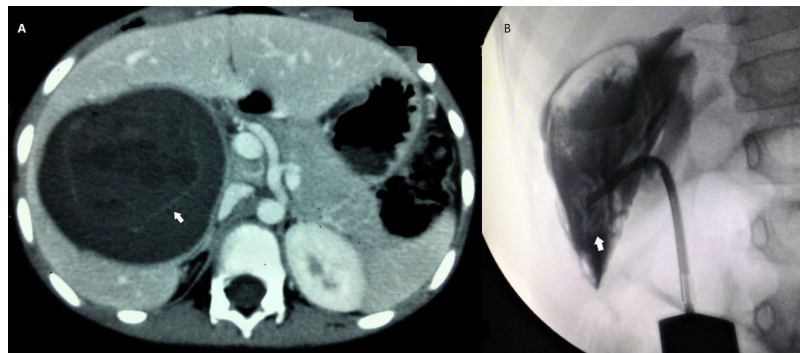


Figure 1 (A) Computed tomography showing large cyst in liver with water-lily sign (arrow) and areas of central hypoattenuation (daughter cysts). (B) PAIR procedure showing floating membranes (arrow).

Visualisation of hydatid membranes in a liver cyst during intervention is a rare image. We present a 10 year old boy presented with progressively enlarging lump in right hypochondrium with intermittent fever for last 4 years. Serology and computed tomography (Fig. 1A) were suggestive of liver echinococcosis (water-lily sign). The patient was a candidate for PAIR (puncture, aspiration, injection and

re-aspiration) procedure. A whirl of floating membranes were seen during the aspiration phase (Fig. 1B). Scoleces were visible on microscopic examination of the fluid. 300 ml of 20% hypertonic saline was injected. Patient responded to the radiological intervention and 3 months of oral albendazole therapy. He remains asymptomatic till 60 months follow-up.

* Corresponding author.

E-mail address: moinaksen@yahoo.com (M. Sen Sarma).