



## ORIGINAL ARTICLE

## Adenosquamous cancer of the pancreas: A multicenter retrospective study



José Manuel Ramia-Angel<sup>a,b</sup>, Isabel Jaén-Torrejimeno<sup>c</sup>,  
Alejandro Serrablo-Requejo<sup>d,e</sup>, Gonzalo P. Rodríguez-Laiz<sup>a,b</sup>, Diego López-Guerra<sup>c</sup>,  
Teresa Abadía-Forcén<sup>d</sup>, Cristina Alenda<sup>a,f</sup>, Mario Serradilla-Martín<sup>d,e,\*</sup>,  
Gerardo Blanco-Fernández<sup>c,g</sup>

<sup>a</sup> Servicio de Cirugía General, Hospital General Universitario, Alicante, Spain

<sup>b</sup> ISABIAL: Instituto de Investigación Sanitaria y Biomédica, Alicante, Spain

<sup>c</sup> Servicio de Cirugía General, Complejo Hospitalario de Badajoz, Badajoz, Spain

<sup>d</sup> Servicio de Cirugía General, Hospital Universitario Miguel Servet, Zaragoza, Spain

<sup>e</sup> Instituto de Investigación Sanitaria de Aragón, Zaragoza, Spain

<sup>f</sup> Servicio de Anatomía Patológica, Hospital General Universitario, Alicante, Spain

<sup>g</sup> Universidad de Extremadura, Badajoz, Spain

Received 5 August 2021; accepted 16 December 2021

## KEYWORDS

Adenosquamous;  
Pancreas;  
Cancer;  
Surgery

## Abstract

**Introduction:** Adenosquamous cancer of the pancreas (ASCP) is an aggressive, infrequent subtype of pancreatic cancer that combines a glandular and squamous component and is associated with poor survival.

**Methods:** Multicenter retrospective observational study carried out at three Spanish hospitals. The study period was: January 2010–August 2020. A descriptive analysis of the data was performed, as well as an analysis of global and disease-free survival using the Kaplan–Meier statistic.

**Results:** Of a total of 668 pancreatic cancers treated surgically, twelve were ASCP (1.8%). Patient mean age was  $69.2 \pm 7.4$  years. Male/female ratio was 1:1. The main symptom was jaundice (seven patients). Correct preoperative diagnosis was obtained in only two patients. Nine pancreatoduodenectomies and three distal pancreatectomies were performed. 25% had major complications. Mean tumor size was  $48.6 \pm 19.4$  mm. Nine patients received adjuvant chemotherapy. Median survival time was 5.9 months, and median disease-free survival was 4.6 months. 90% of patients presented recurrence. Ten of the twelve patients in the study (83.3%) died, with disease progression being the cause in eight. Of the two surviving patients, one is disease-free and the other has liver metastases.

\* Corresponding author.

E-mail address: [marioserradilla@hotmail.com](mailto:marioserradilla@hotmail.com) (M. Serradilla-Martín).

**Conclusion:** ASCP is a very rare pancreatic tumor with aggressive behavior. It is rarely diagnosed preoperatively. The best treatment, if feasible, is surgery followed by the standard chemotherapy regimens for pancreatic adenocarcinoma.  
© 2021 Published by Elsevier España, S.L.U.

## PALABRAS CLAVE

Adenoescamoso;  
Páncreas;  
Cáncer;  
Cirugía

## Cancer adenoescamoso de páncreas. Estudio retrospectivo multicéntrico

### Resumen

**Introducción:** El cáncer adenoescamoso de páncreas (CPAS) es un subtipo de cáncer de páncreas agresivo e infrecuente que combina un componente glandular y escamoso, y presenta baja supervivencia.

**Métodos:** Estudio observacional retrospectivo multicéntrico realizado en tres hospitales españoles. El período de estudio fue: enero 2010 - agosto 2020. Se realizó un análisis descriptivo de los datos, así como un análisis de supervivencia global y libre de enfermedad mediante Kaplan-Meier.

**Resultados:** De un total de 668 cánceres de páncreas tratados quirúrgicamente, doce fueron CPAS (1,8%). La edad media de los pacientes fue de  $69,2 \pm 7,4$  años. La proporción hombre/mujer fue de 1: 1. El síntoma principal fue la ictericia (siete pacientes). Se obtuvo un diagnóstico preoperatorio correcto en solo dos pacientes. Se realizaron nueve duodenopancretectomías cefálicas y tres pancreatoesplenectomías distales. El 25% tuvo complicaciones mayores. El tamaño medio del tumor fue de  $48,6 \pm 19,4$  mm. Nueve pacientes recibieron quimioterapia adyuvante. La mediana de supervivencia fue de 5,9 meses y la mediana de supervivencia libre de enfermedad fue de 4,6 meses. El 90% de los pacientes presentó recidiva. Diez de los doce pacientes del estudio (83,3%) fallecieron, y la progresión de la enfermedad fue la causa en ocho. De los dos pacientes que sobrevivieron, uno está libre de enfermedad y el otro tiene metástasis hepáticas.

**Conclusión:** El CPAS es un tumor pancreático muy raro y de comportamiento agresivo. Rara vez se diagnostica antes de la operación. El mejor tratamiento, si es posible, es la cirugía seguida de los regímenes de quimioterapia estándar para el adenocarcinoma de páncreas.

© 2021 Publicado por Elsevier España, S.L.U.

## Introduction

Adenosquamous cancer of the pancreas (ASCP) is an aggressive, infrequent subtype of pancreatic cancer which combines glandular and squamous component and is associated with poor survival.<sup>1-4</sup> There are no studies of the geographical incidence of ASCP, although most publications are based on populations in Asia or from the SEER database in the US.<sup>5-9</sup> Only three European series have been published to date.<sup>1,3,9</sup>

The etiology of ASCP is unknown. Several hypotheses have been published regarding its histogenesis.<sup>5</sup> According to the collision theory, two histologically distinct tumors may arise independently in the pancreatic tissue and eventually coalesce. Alternatively, it has been proposed that squamous metaplasia occurs due to obstructive ductal inflammation, or that a pancreatic pluripotential cell differentiates into a squamous or adenocarcinoma.<sup>5,8,9</sup> It is not known whether the typical risk factors for ASCP are the same as for pancreatic adenocarcinoma (PA).<sup>5,9</sup>

The diagnosis of ASCP requires the presence of at least 30% of a squamous component in the tumor.<sup>2,3,5,6,8,9</sup>

Nevertheless, this figure is controversial due to the subjectivity of the measurement and the difficulty of defining the percentage on the basis of a biopsy alone. Some authors suggest that in the presence of squamous cells ASCP should be considered.<sup>9</sup> Tumor cell necrosis in ASCP is common, and the growth rate is twice that of PA due to the rapid proliferation of the squamous component.<sup>8,9</sup> ASCP immunohistochemistry is positive for CK5/6 and 7 and p63, and negative for CK20, p16, and p53.<sup>1,9</sup> It is usually located in the periphery and the adenocarcinoma in the center, with a transition zone in which the glandular structures become squamous. It frequently presents vascular invasion, but only rarely lymph node metastases.

The prognosis of ASCP is poor with survivals of 4–19 months and early relapses probably related to squamous component.<sup>1-9</sup>

Here, we present a multicenter retrospective series from Spain with data from three hospitals, aiming to determine the epidemiological characteristics of this rare tumor and to present the oncological results obtained.

## Methods

Multicenter, retrospective observational study of prospective data from pancreatic cancer databases stored at the Hepato-Pancreato-Biliary Surgery Departments of three Spanish hospitals. The study period was between 1 January 2010 and 31 August 2020. The inclusion criterion was any pancreatic tumor operated on with final pathological diagnosis of ASCP, and the exclusion criteria were other histological findings (squamous cell carcinoma, adenocarcinoma, etc.). The study was carried out in accordance with STROBE guidelines (supplementary Table 1).<sup>10</sup>

Each participating hospital appointed a local manager to carry out the data recording and to liaise with the overall study coordinator. All data were recorded by local manager at each hospital, and the project coordinator had access to medical data only.

## Definitions

Diagnosis was based mainly on CT scan, MRI and EUS plus biopsy. The surgical techniques included pancreatoduodenectomy and distal pancreatectomy. For the diagnosis of ASCP, the presence of a squamous component occupying at least 30% in the tumor tissue was established as mandatory. Complications were assessed at 90 days using the Clavien-Dindo (CD) classification, and those defined as Clavien-Dindo grade IIIa or higher were considered major.<sup>11</sup> For the recording of complications, the medical and nursing notes of the electronic histories of each patient were consulted. For the complications specifically associated with pancreatic surgery, the definitions of the International Study Group on Pancreatic Surgery (ISGPS) of delayed gastric emptying,<sup>12</sup> post-pancreatic hemorrhage<sup>13</sup> and pancreatic fistula<sup>14</sup> were used. The resection margins of the surgical specimen were categorized according to the definitions of the Royal College of Pathologists: R0 (margin to the tumor  $\geq 1$  mm), R1 (margin to the tumor  $< 1$  mm) and R2 (macroscopically positive margin).<sup>15</sup> Tumors were staged according to the TNM classification 8 Ed.,<sup>16</sup> but arterial involvement is considered T4 only in ASCP. Chemotherapy was given in a variety of regimens if the patient was  $>T2$  or had positive nodes and was fit to receive this treatment after surgery. The follow-up regimen comprised an outpatient clinical visit every three months during the first two years including tumor marker assessment and CT/MRI. No patient received neoadjuvant chemotherapy.

## Variables

The following variables were studied: age, gender, main clinical symptom; serology tests: hemoglobin (g/dl), bilirubin (mg/dl), ALT (U/l), AST (U/l), calcium (mg/dl), CEA (ng/ml) and CA19-9 (U/ml); radiological/endoscopic tests performed (CT/MRI/EUS), including lesion size and location, preoperative biopsy, preoperative diagnosis of ASCP; surgical procedure performed and morbidity/mortality.<sup>11–14</sup> The histological data retrieved were TNM tumor size and lymph nodes harvested, grade, and R status. Chemotherapy protocol, time of relapse, disease-free and overall survival from

date of diagnosis, cause of death and postoperative follow-up (months) were also recorded.

## Statistical analysis

Categorical variables are presented as frequencies and percentages. Continuous variables were tested for Gaussian distribution by the Shapiro–Wilk test; those with normal distribution were presented as means and standard deviations (SD) and non-normal variables were reported as medians and interquartile ranges (IQR). Kaplan–Meier survival analysis was performed to model all-cause mortality and relapse-free survival from the day of surgery. Data were analyzed using R version 3.1.3 (<http://www.r-project.org>) and the appropriate packages.

## Results

During the study period, the three units operated on a total of 668 pancreatic cancers, of which twelve were ASCP (1.8%). Mean age of patients with ASCP was  $69.2 \pm 7.4$  years, and the male/female ratio was 1:1 (six men and six women). The main symptom was jaundice (seven patients), abdominal pain (three), cholangitis (one), and vomiting (one). All 12 patients underwent abdominal CT (Fig. 1), nine EUS, and seven abdominal MRI. Nine tumors were located in the head of the pancreas and three in the body/tail. Mean preoperative tumor size was  $39 \pm 19$  mm. Preoperative biopsies were performed in nine patients (75%), 8 by EUS and one biopsy of ampullar lesion, but only two identified ASCP. Therefore, in ten patients (three not biopsied and seven biopsied) (83.3%), the preoperative diagnosis was adenocarcinoma of the pancreas (PA). The mean laboratory test values were: hemoglobin: 11.5 g/dl (1.70) (normal values: 11.5–16 g/dl); total bilirubin: 2.89 mg/dl [0.32;9.47] (0–1.2 mg/dl); AST: 87.0 U/l [20.5;180] (0–32 U/l); ALT: 81.5 U/l [26.5;250] (0–33 U/l); CEA: 7.88 ng/dl (7.25) (0–5 ng/dl); CA 19-9: 47.5 U/l [38.4;67.6] (0–37 U/l), and serum calcium: 8.67 (1.05) mg/dl (8.5–10.5 mg/dl) (Table 1).

As regards surgical technique, nine pancreatoduodenectomies were performed (in one case associated with right hemicolectomy and in another with wedge resection of one small unique liver metastasis), and three distal pancreatectomies (in one patient combined with left nephrectomy and partial gastrectomy). The resection of neighboring organs was always due to local tumor growth. Fifty-eight per cent of patients had minor complications (three grade I and four grade II), and 25% major complications (two IIIa and one V due to multiorgan failure). Regarding the complications of pancreatic surgery, two patients had type B pancreatic fistula of ISGPS classification, three had biochemical fistula (previous known as A) and seven did not have postoperative fistula. One patient presented delayed gastric emptying type A of ISGPS and another postoperative hemorrhage type A of ISGPS; two intra-abdominal abscesses were detected and treated by percutaneous drainage (Table 2).

The mean definitive tumor size recorded in the specimen was  $48.6 \pm 19.4$  mm. The degree of differentiation was G2 (two patients), G3 (eight) and undetermined in two. No necrosis was observed in five patients (41.7%). The R0 rate

**Table 1** Epidemiological and diagnostic tests.

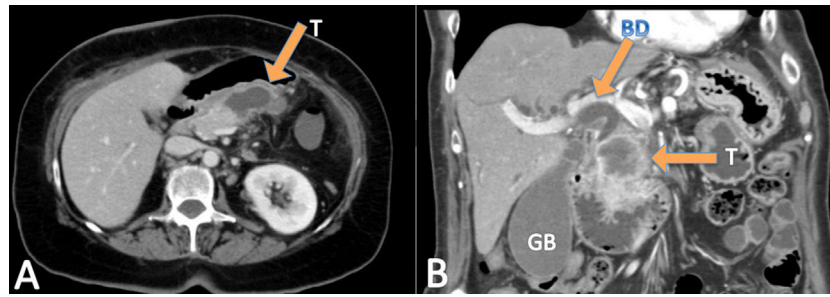
Case	Age	Gender	Main clinical symptom	CT	MRI	Size (mm)	USE	Preop. biopsy	Preop. ASCP biopsy	TB (mg/dl)	AST (U/l)	ALT (U/l)	CEA (ng/ml)	CA 19.9(U/ml)	Hb (g/dl)	Ca (mg/dl)
1	73	Male	Abdominal pain	YES	NO	50	NO	NO	NO	0.9	19	30	No	No	14.1	8
2	67	Female	Jaundice	YES	YES	26	YES	YES	NO	0.73	89	115	No	No	9.3	7.3
3	63	Male	Acute Cholangitis	YES	YES	45	YES	YES	NO	4.88	141	197	0.8	67.1	13	9.4
4	60	Female	Jaundice	YES	NO	21	YES	YES	NO	0.36	21	16	9.2	38.4	12.4	9
5	73	Female	Jaundice	YES	NO	16	YES	YES	YES	13.72	85	48	3.2	46.8	13.2	9.7
6	64	Female	Abdominal pain	YES	NO	31	YES	YES	YES	0.2	52	31	7.8	286	8.4	9
7	79	Female	Jaundice	YES	NO	27	YES	YES	NO	8.06	230	291	21.3	28	11.7	9.5
8	73	Female	Abdominal pain	YES	YES	85	NO	NO	NO	0.2	11	8	No	No	10.9	7.5
9	71	Male	Jaundice	YES	YES	34	YES	YES	NO	7.7	209	377	no	67.6	12.4	9.3
10	55	Male	Jaundice	YES	NO	40	YES	NO	NO	17.2	170	236	No	3.6	9.9	7
11	78	Male	Jaundice	YES	YES	Ampuloma (no mesurable)	NO	YES	NO	15	432	615	No	47.46	12.2	10.2
12	74	Male	Vomiting	YES	NO	50	YES	YES	NO	0.2	12	6	4.95	671	11	8.1

Preop: preoperative. TB: total bilirubin. Hb: hemoglobin. Ca.: calcium.

Table 2  
Surgery and pathology.

Case	Surgical technique	Clavien	Pancreas fistula BQ/B/C	DGE	Hemorrhage a/b/c	Biliary fistula	IA abscess	Size (mm)	Lymph nodes (+/total)	Grade	Necrosis	IHQ	R	TNM
1	Distal pancreatectomy + splenectomy	II	NO	NO	NO	NO	NO	60	6/11	G3	NO	ND	R1	pT3N1M0
2	Pancreatoduodenectomy	V	BQ	NO	A	NO	NO	32	1/25	G3	NO	ND	R0	pT2N1M0
3	Pancreatoduodenectomy	II	BQ	NO	NO	NO	NO	70	2/14	G3	NO	ND	R1	pT3N1M0
4	Pancreatoduodenectomy	II	NO	NO	NO	NO	SI	38	2/19	G3	NO	ND	R0	pT2N1M0
5	Pancreatoduodenectomy	I	NO	NO	NO	NO	NO	20	1/17	G3	NO	CK7, p40, p63 y MUC1	R0	pT2N1M0
6	Distal pancreatectomy plus splenectomy + nephrectomy + parical gastrectomy	IIIA	B	NO	NO	NO	NO	55	0/14	ND	ND	ND	R0	pT3N0M0
7	Pancreatoduodenectomy	O	NO	NO	NO	NO	NO	53	0/12	ND	ND	ND	R0	pT3N0M0
8	Distal pancreatectomy + splenectomy	I	BQ	NO	NO	NO	NO	90	0/18	G3	ND	ND	R1	pT3N0M0
9	Pancreatoduodenectomy + liver wedge resection	IIIA	B	A	NO	NO	SI	45	1/6	G2	ND	ND	R0	pT2N1M1
10	Pancreatoduodenectomy	O	NO	NO	NO	NO	NO	35	1/13	G3	ND	ND	R2	pT2N1M0
11	Pancreatoduodenectomy	II	NO	NO	NO	NO	NO	30	1/41	G2	ND	ND	R0	pT2N1M0
12	Pancreatoduodenectomy + right hemicolectomy	I	NO	NO	NO	NO	NO	55	1/15	G3	ND	IMS -	R0	pT3N1M0

BQ: biochemical. DGE: delayed gastric emptying. IA: intra-abdominal abscess. ND: no disposable. IHQ: immunohistochemistry study.



**Figure 1** (A) CT: adenosquamous tumor in distal pancreas. (B) CT: adenosquamous tumor in pancreatic head. T: tumor. GB: gallbladder. BD: bile duct.

**Table 3** Oncological results.

Case	Adjuvant therapy	Relapse	Type of relapse	Exitus	Free disease survival months	Overall survival months
1	Gemcitabine-Capecitabine	Yes	Liver metastasis	Disease progression	0.9	4.1
2	No	No	–	Postoperative urological sepsis	–	2.2
3	No	Yes	Peritoneal carcinomatosis	Disease progression	2.0	3.9
4	Gemcitabine	Yes	Liver metastasis	No	2.9	36.2
5	Gemcitabine	No	–	No	4.6	4.6
6	Gemcitabine-oxaliplatin	Yes	Local relapse	Disease progression	8.6	18.7
7	No	Yes	Liver + carcinomatosis	Disease progression	7.4	10.0
8	Gemcitabine	No	–	Upper digestive bleeding	4.1	4.1
9	Tegafur + folinic acid	Yes	Liver metastasis	Hypercalcemia and fungal infection	4.6	6
10	Gemcitabine-Abraxane	Yes	Liver metastasis + local relapse	Disease progression	1.3	4.4
11	Gemcitabine	Yes	Liver metastasis	Disease progression	3.8	7.7
12	Gemcitabine-Capecitabine + RT	Yes	Liver metastasis	Disease progression	4.9	17.5

RT: radiotherapy.

was 66.7%. The TNM distribution was T2N1M0 (five patients), T2N1M1 (one, due to a single resected liver metastasis), T3N0M0 (three); T3N1M0 (three).

Nine patients received adjuvant chemotherapy (9/12.75%), two were unfit for chemotherapy and one patient died in postoperative period. Eight received regimens based on gemcitabine: two alone, four in combination with capecitabine, one with abraxane and one with oxaliplatin, and one patient was administered 5-fluorouracil plus folinic acid. One patient received radiation therapy. No patient received neoadjuvant chemotherapy (Table 2).

Median survival time from date of diagnosis was 5.9 months, and median disease-free survival was 4.6 months. The 1-year survival probability was 0.38 (95% CI: 0.19–0.81). One patient died in the immediate postoperative period due to multiorgan failure (8.3%), and another four months after surgery due to upper gastrointestinal bleeding, with no evidence of recurrence. Of the remaining 10 patients, nine (90%) presented recurrence: five liver metastases, one liver metastases and locoregional recurrence, one liver metastases and peritoneal carcinomatosis, one peritoneal

carcinomatosis and one locoregional recurrence. In total, 10 of the 12 patients in the study (83.3%) died, with disease progression being the cause in eight. Of the two surviving patients, one is disease-free but only has a follow-up of 4.2 months and the other has liver metastases diagnosed at 29 months with overall survival of 35 months (Table 3, Figs. 2 and 3).

## Discussion

ASCP is an extremely rare condition, accounting for only 0.38–4% of all pancreatic tumors.<sup>3</sup> It was first described in 1907 by Herheimer.<sup>1,2,5,8,9,17–19</sup> It has received multiple names, including adenoacanthoma, adenocarcinoma with squamous metaplasia, and mucoepidermoid carcinoma.<sup>9,17,18</sup>

The typical ASCP patient is male (male/female ratio 2:1), in the sixth decade of life.<sup>3–5</sup> There is no consensus among the series regarding the most frequent location (either the head of the pancreas or the tail).<sup>1,2,3,5,7–9,17</sup> In our series, the

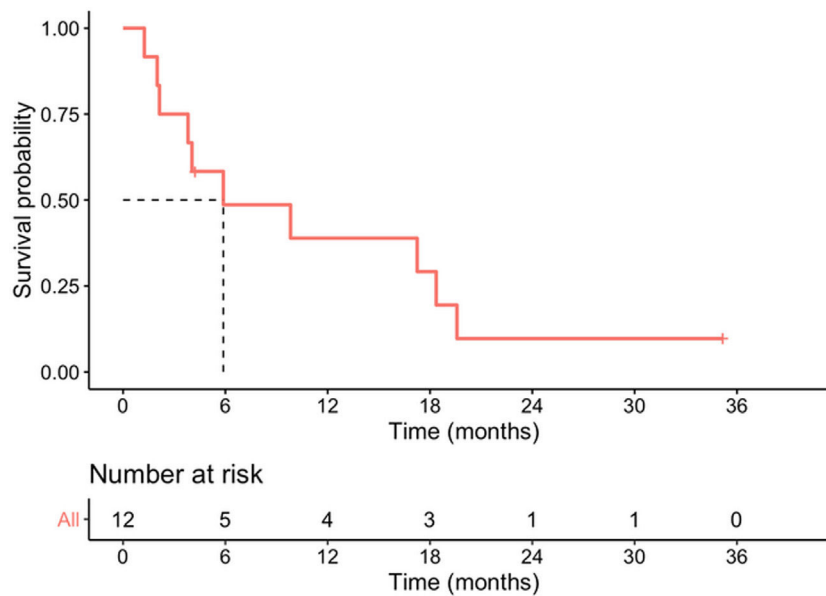


Figure 2 Survival probability.

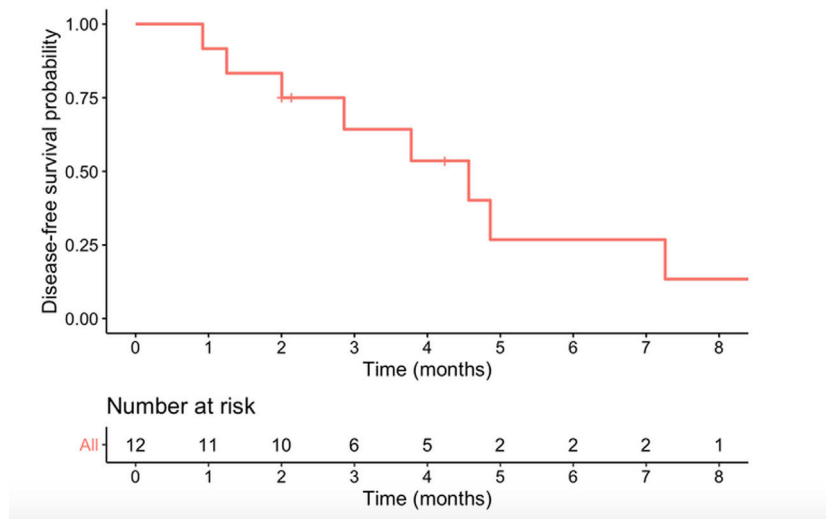


Figure 3 Disease free survival probability.

male/female ratio was 1:1, mean age was 69 years and the tumor site was three times more likely to be the head of the pancreas than the body/tail.

Clinically, patients with ASCP present symptoms similar to those of PA: abdominal and/or back pain, weight loss, nausea and or vomiting, anorexia, and jaundice.<sup>1,5,17</sup> In our study jaundice was the most frequently recorded main symptom, caused by the predominance of pancreatic head lesions. As previously reported elsewhere, laboratory tests in our sample presented elevated liver parameters, anemia, and elevated tumor markers.<sup>1,2,5,7,9–11,18</sup> A few cases of malignant hypercalcemia associated with ASCP have been described.<sup>5,9</sup> None of our patients presented this condition pre-operatively, but one case was recorded later (a patient with tumor recurrence).

The radiological features of ASCP based in literature data are: these tumors tend to be ill-defined, show central necrosis in 75%; they are solid in 25%, they present enhancement, vascular and neural entrapment and exophytic growth, and duodenal invasion in up to 30% of ASCPs.<sup>5,9,17,19</sup> In PET-CT, ASCP has more intense FDG uptake than conventional PA both on early and delayed phase. Retention index value of PASC is positive.<sup>20</sup> The usual preoperative radiological and histological diagnosis is PA,<sup>9</sup> and in our series more than 80% of the patients received this diagnosis. The diagnosis of ASCP is generally made after the histological study of the surgical specimen; in our series, it was diagnosed after the preoperative biopsy in only two cases.

The recommended treatment for ASCP, when feasible, is surgical resection in order to improve survival.<sup>1,4,5,9,18</sup> It is



not clarified whether neoadjuvant therapy might improve oncology outcomes.<sup>4</sup> As there are no specific neoadjuvant or adjuvant treatment regimens for ASCP, the same ones are used as for PA.<sup>1</sup> It has been suggested that platinum-based therapies may improve survival.<sup>5,9,17</sup> Older age and comorbidities were associated with a reduced likelihood of receiving adjuvant or neoadjuvant chemotherapy.<sup>4</sup> It is not clear whether radiotherapy can improve oncological outcomes in ASCP.<sup>9</sup> Survival rates in ASCP are 21.2–50.7% at one year, 10.8–29% at two years, and 8–14% at three years, with a median survival that ranges between 5 and 15 months according to series.<sup>1,7–9,18,21</sup> Hue et al got a better survival in the surgery plus chemotherapy group<sup>4</sup>. The rates are always lower than those reported for PA.<sup>1,7–9,18,19</sup> Our results are similar to those published in the literature, which record very short survival periods.

Comparative studies of ASCP and PA show that ASCP are frequently poorly differentiated, larger, with higher vascular and perineural invasion, and greater lymph node involvement (though not in all series), which explains their worse prognosis.<sup>1,7,8</sup> But, Kaiser et al showed that after matching for the unevenly distributed prognostic factors survival after resection of ASCP and PA was comparable<sup>3</sup>.

Recurrence is normally early, affecting the liver, lung and retroperitoneum, and malignant ascites is frequent.<sup>1,8,9</sup> In our series, recurrence occurred early and was localized, either in the liver or locally. Factors associated with poor survival in ASCP series are tumor size, lymph node involvement, presence of metastases, high CA19-9 levels, advanced age, location in the distal pancreas, positive surgical margin, the impossibility of surgical resection and the non-administration of adjuvant treatment.<sup>1,3,9</sup>

The limitations of the study are its retrospective nature, the small number of cases, the analysis only of surgical cases may imply a selection bias, as it is a multicenter study, the radiological techniques may differ between centers, which does not allow establishing more definitive data on the radiological characteristics of these tumors and finally the immunohistochemical study was only performed in a single patient, so it cannot be ruled out that the presence of a squamous component may be secondary to invasion of other organs (bile duct, duodenum, etc.). The strengths are that very few studies have been conducted in Europe on this type of tumor.

## Conclusions

ASCP is a very rare, aggressive pancreatic tumor. It is rarely diagnosed preoperatively unless squamous cells are observed in a preoperative biopsy. Central necrosis is the only radiological finding that can suggest its presence. The best treatment, if feasible, is surgery followed by the standard chemotherapy regimens for PA, as there are no conclusive studies indicating that other alternatives would obtain better results. A European multicenter study could provide us with more complete information on this type of tumors in western patients.

## Authors' contributions

Conception and design of the work: JM Ramia.

Acquisition, analysis, or interpretation of data: all authors.

Drafting the work or revising: JM Ramia, M Serradilla, Gerardo Blanco.

Final approval of the version to be published: All authors.

## Statement of ethics

The study was approved by the Research Ethics Committee of the Hospital General Universitario de Alicante Ethics Committee decided that patients' informed consent was not required since the study was retrospective and observational and entailed no risk and the majority of patients were dead.

## Data availability statement

All data generated or analysed during this study are included in this article [and/or] its supplementary material files. Further enquiries can be directed to the corresponding author.

## Funding sources

This manuscript did not receive any funding.

## Conflict of interest

The authors have no conflicts of interest to declare.

## Appendix A. Supplementary data

Supplementary data associated with this article can be found, in the online version, at [doi:10.1016/j.gastrohep.2021.12.006](https://doi.org/10.1016/j.gastrohep.2021.12.006).

## References

- Boecker J, Feyerabend B, Tiemann K, Buchwalow I, Wagner KC, Oldhafer KJ, et al. Adenosquamous carcinoma of the pancreas comprise a heterogeneous group of tumors with the worst outcome. A clinicopathological analysis of 25 cases identified in 562 pancreatic carcinomas resected with curative intent pancreas. 2020;49:683–91, <http://dx.doi.org/10.1097/MPA.0000000000001548>.
- Imaoka H, Shimizu Y, Mizuno N, Hara K, Hijioka S, Tajika M, et al. Clinical characteristics of adenosquamous carcinoma of the pancreas: a matched case-control study. *Pancreas*. 2014;43:287–90, <http://dx.doi.org/10.1097/MPA.000000000000089>.
- Kaiser J, Hinz U, Mayer P, Hank T, Niesen W, Hackert T, et al. Clinical presentation and prognosis of adenosquamous carcinoma of the pancreas – matched-pair analysis with pancreatic ductal adenocarcinoma. *Eur J Surg Oncol*. 2021;47:1734–41, <http://dx.doi.org/10.1016/j.ejso.2021.02.011>.
- Hue JJ, Katayama E, Sugumar K, Winter JM, Ammori JB, Rothermel LD, et al. The importance of multimodal therapy in the management of nonmetastatic adenosquamous carcinoma of the pancreas: analysis of treatment sequence and strategy. *Surg (United States)*. 2021;169:1102–9, <http://dx.doi.org/10.1016/j.surg.2020.11.026>.
- Moslim MA, Lefton MD, Ross EA, Mackrides N, Reddy SS. Clinical and histological basis of adenosquamous carcinoma of the



- pancreas: a 30-year experience. *J Surg Res.* 2021;259:350–6, <http://dx.doi.org/10.1016/j.jss.2020.09.024>.
6. Katz MH, Taylor TH, Al-Refaie WB, Hanna MH, Imagawa DK, Anton-Culver H, et al. Adenosquamous versus adenocarcinoma of the pancreas: a population-based outcomes analysis. *J Gastrointest Surg.* 2011;15:165–74, <http://dx.doi.org/10.1007/s11605-010-1378-5>.
  7. Boyd CA, Benarroch-Gampel J, Sheffield KM, Cooksley CD, Riall TS. 415 patients with adenosquamous carcinoma of the pancreas: a population-based analysis of prognosis and survival. *J Surg Res.* 2012;174:12–9, <http://dx.doi.org/10.1016/j.jss.2011.06.015>.
  8. Komatsu H, Egawa S, Motoi F, Morikawa T, Sakata N, Naitoh T, et al. Clinicopathological features and surgical outcomes of adenosquamous carcinoma of the pancreas: a retrospective analysis of patients with resectable stage tumors. *Surg Today.* 2015;45:297–304.
  9. Borazanci E, Millis SZ, Korn R, Han H, Whatcott CJ, Gatalica Z, et al. Adenosquamous carcinoma of the pancreas: molecular characterization of 23 patients along with a literature review. *World J Gastrointest Oncol.* 2015;7:132–40, <http://dx.doi.org/10.4251/wjgo.v7.i9.132>.
  10. Ghaferi AA, Schwartz TA, Pawlik TM. STROBE reporting guidelines for observational studies. *JAMA Surg.* 2021;156:577–8, <http://dx.doi.org/10.1001/jamasurg.2021.0528>.
  11. Dindo D, Demartines N, Clavien PA. Classification of surgical complications: a new proposal with evaluation in a cohort of 6336 patients and results of a survey. *Ann Surg.* 2004;240:205–13, <http://dx.doi.org/10.1097/01.sla.0000133083.54934.ae>.
  12. Wente MN, Bassi C, Dervenis C, Fingerhut A, Gouma DJ, Izbicki JR, et al. Delayed gastric emptying (DGE) after pancreatic surgery: a suggested definition by the International Study Group of Pancreatic Surgery (ISGPS). *Surgery.* 2007;142:761–8, <http://dx.doi.org/10.1016/j.surg.2007.05.005>.
  13. Wente MN, Veit JA, Bassi C, Dervenis C, Fingerhut A, Gouma DJ, et al. Postpancreatectomy hemorrhage (PPH): an International Study Group of Pancreatic Surgery (ISGPS) definition. *Surgery.* 2007;142:20–5, <http://dx.doi.org/10.1016/j.surg.2007.02.001>.
  14. Bassi C, Marchegiani G, Dervenis C, Sarr M, Abu Hilal M, Adham M, et al. The 2016 update of the International Study Group (ISGPS) definition and grading of postoperative pancreatic fistula: 11 years after. *Surgery.* 2017;161:584–91, <http://dx.doi.org/10.1016/j.surg.2016.11.014>.
  15. College of American Pathologists. Protocol for the examination of specimens from patients with carcinoma of the exocrine pancreas. Version 4.1.0.0, 2020. <https://documents.cap.org/protocols/cp-gihepatobiliary-pancreasexocrine-20-4100.pdf>.
  16. van Roessel S, Kasumova GG, Verheij J, Najarian RM, Maggino L, de Pastena M, et al. International validation of the eighth edition of the American Joint Committee on Cancer (AJCC) TNM staging system in patients with resected pancreatic cancer. *JAMA Surg.* 2018;153:e183617, <http://dx.doi.org/10.1001/jamasurg.2018.3617>.
  17. Ito T, Sugiura T, Okamura, Yamamoto Y, Ashida R, Ohgi K, et al. Long-term outcomes after an aggressive resection of adenosquamous carcinoma of the pancreas. *Surg Today.* 2019;49:809–19, <http://dx.doi.org/10.1007/s00595-019-01807-8>.
  18. Stauffer JA, Asbun HJ. Rare tumors and lesions of the pancreas. *Surg Clin North Am.* 2018;98:169–88, <http://dx.doi.org/10.1016/j.suc.2017.09.013>.
  19. Feng YF, Chen JY, Chen HY, Wang TG, Shi D, Lu YF, et al. 110 patients with adenosquamous carcinomas of the pancreas (PASC): imaging differentiation of small ( $\leq 3$  cm) versus large ( $> 3$  cm) tumors. *Abdom Radiol (NY).* 2019;44:2466–73, <http://dx.doi.org/10.1007/s00261-019-01989-2>.
  20. Su W, Zhao S, Chen Y, Zuo C, Cui B, Wang M, et al.  $^{18}\text{F}$ -FDG PET/CT feature of pancreatic adenosquamous carcinoma with pathological correlation. *Abdom Radiol (NY).* 2020;45:743–9, <http://dx.doi.org/10.1007/s00261-019-02393-6>.
  21. Luo G, Fan Z, Gong Y, Jin K, Yang C, Cheng H, et al. Characteristics and outcomes of pancreatic cancer by histological subtypes. *Pancreas.* 2019;48:817–22, <http://dx.doi.org/10.1097/MPA.0000000000001338>.