

by biopsy alone, liver resection can also be required as a definitive treatment when steroid therapy is futile.⁵

Conflict of interests

The authors declare no conflict of interests.

References

1. Kleger A, Seufferlein T, Wagner M, Tannapfel A, Hoffmann TK, Mayerle J. IgG4-related autoimmune diseases. *Dtsch Arztebl Int.* 2015;112:128–35.
2. Zen Y, Fujii T, Sato Y, Masuda S, Nakanuma Y. Pathological classification of hepatic inflammatory pseudotumor with respect to IgG4-related disease. *Mod Pathol.* 2007;20:884–94.
3. Shibata M, Matsubayashi H, Aramaki T, Uesaka K, Tsutsumi N, Sasaki K, et al. A case of IgG4-related hepatic inflammatory pseudotumor replaced by an abscess after steroid treatment. *BMC Gastroenterol.* 2016;16:89.
4. Calvo J, Carbonell N, Scatton O, Marzac C, Ganne-Carrie N, Wendum D. Hepatic nodular lymphoid lesion with increased IgG4-positive plasma cells associated with primary biliary cirrhosis: a report of two cases. *Virchows Arch.* 2015;467:613–7.
5. Ahn KS, Kang KJ, Kim YH, Lim TJ, Jung HR, Kang YN, et al. Inflammatory pseudotumors mimicking intrahepatic

- cholangiocarcinoma of the liver; IgG4-positivity and its clinical significance. *J Hepatobiliary Pancreat Sci.* 2012;19:405–12.
6. Komorowski AL, Li WF, Millan CA, Huang TS, Yong CC, Lin TS, et al. Temporary abdominal closure and delayed biliary reconstruction due to massive bleeding in patients undergoing liver transplantation: an old trick in a new indication. *J Hepatobiliary Pancreat Sci.* 2016;23:118–24.
 7. Umehara H, Okazaki K, Masaki Y, Kawano M, Yamamoto M, Saeki T, et al. Comprehensive diagnostic criteria for IgG4-related disease (IgG4-RD), 2011. *Mod Rheumatol.* 2012;22:21–30.

Oleksandr Legkiy^{a,*}, Justyna Wajda^{a,b}, Anna Ćwierz^a, Joanna Wysocka^c, Andrzej L. Komorowski^a

^a Department of Surgical Oncology, Maria Skłodowska-Curie Memorial Cancer Center and Institute of Oncology, Cracow, Poland

^b Department of Anatomy, Jagiellonian University Medical College, Cracow, Poland

^c Department of Pathology, Maria Skłodowska-Curie Memorial Institute, Cancer Centre, Cracow, Poland

* Corresponding author.

E-mail address: oleksandr.legkiy@gmail.com (O. Legkiy). 2444-3824/

© 2018 Elsevier España, S.L.U. All rights reserved.

Acute epidural haematoma as a presentation of hepatocellular carcinoma: Case report and literature review[☆]



Hematoma epidural agudo como presentación de carcinoma hepatocelular: a propósito de un caso y revisión de la literatura

A 59-year-old Thai woman living in Spain for the past 20 years with a personal history of a partial nephrectomy and hysterectomy, who was not taking any regular medication. She attended our hospital's emergency department having suffered from general malaise, abdominal distension, jaundice and choluria over the course of two weeks, with her symptoms worsening in the second week. While having her history taken, she mentioned that she had received a blood transfusion in the 1980s. She said she did not take any medicines, herbal products or have tattoos. She travelled often, having visited Thailand and Switzerland in the last year. She had consumed 16 g of alcohol per day for the past five years. During the physical examination, she presented jaundiced skin and mucous membranes and painless

hepatosplenomegaly. Her laboratory tests revealed a previously unknown coagulopathy and abnormal liver parameters: total bilirubin 8.11 mg/dl, direct bilirubin 5.85 mg/dl, GOT 368 U/l, GPT 137 U/l, GGT 625 U/l, AP 190 U/l, CRP 14.39 mg/dl and prothrombin activity of 53%. Twenty-four hours after admission, she presented a sudden-onset intense holocranial headache and a rapid decline in consciousness (Glasgow Coma Score [GCS] of 5), with no focal neurological deficit. The patient was transferred to intensive care, where she underwent orotracheal intubation and a computed tomography (CT) scan of the head with intravenous contrast. The CT scan (Fig. 1) revealed the presence of a left-sided frontoparietal acute epidural haematoma (AEH) measuring 85 × 42 mm, with associated intracranial expansion and hypertensive hydrocephalus in the contralateral ventricle, probably secondary to an osteolytic cranial vault lesion, suggesting a metastatic aetiology. She underwent emergency neurosurgery, with a left frontotemporal craniotomy, evacuation of the haematoma and tumour resection.

The patient presented poor clinical progress, maintaining a GCS score of 3–4 as well as anuria. From a gastrointestinal point of view, an abdominal ultrasound was performed, showing liver cirrhosis with a focal heterogeneous lesion in segment II measuring 4 cm, a partial portal vein tumour thrombus with a hepatofugal flow and mild ascites. Her blood work up tested positive for the hepatitis C virus (HCV) antigen and antibody, with raised alpha-fetoprotein (2476 ng/ml). According to both clinical and analytical data, she presented a Child-Pugh score of C14 and a MELD score of 24. An anatomical pathology study of the skull lesion (bone and epidural) revealed the presence of epithelial tumour cells with abundant eosinophilic cytoplasm,

[☆] Please cite this article as: Delgado Maroto A, del Moral Martínez M, Diéguez Castillo C, Casado Caballero FJ. Hematoma epidural agudo como presentación de carcinoma hepatocelular: a propósito de un caso y revisión de la literatura. *Gastroenterol Hepatol.* 2019;42:177–179.

Table 1 Summary of published cases of patients with a spontaneous AEH due to HCC metastasis.

Authors and year of publication	Age (years)	Gender	Origin	Signs and symptoms	Known history of HCC	CT findings	Surgical findings	Clinical course
Nakagawa et al, ² 1992	52	Male	Japan	Headache and sharp mental decline	No	Acute epidural haematoma	Haemorrhagic bone tumour	Died two months later due to liver failure
Nakao et al, ³ 1992	58	Male	Japan	Headache and painful scalp mass	Yes	Bone tumour and epidural mass	Chronic epidural haematoma and bone tumour	Died six months later due to liver failure
Hayashi et al, ⁴ 2000	70	Male	Japan	Headache and left-sided hemiparesis	Yes	Lentiform nucleus hyperintensity	Bone tumour and epidural haematoma	Died two months later due to liver failure and pneumonia
Mclver et al, ⁵ 2001	50	Male	USA	Headache and left-sided hemiparesis	No	Osteolytic lesion and acute epidural haematoma	Bone tumour and epidural haematoma	No neurological deficit and treatment with palliative chemotherapy
Kanai et al, ⁶ 2009	56	Male	Japan	Headache, sharp mental decline and scalp mass	No	Osteolytic lesion and acute epidural haematoma	Bone tumour and epidural haematoma	Died three weeks later due to liver failure
Woo et al., ⁷ 2010	46	Male	South Korea	Headache and sharp mental decline	Yes	Acute epidural haematoma	Bone tumour, epidural and subdural haematoma	Died five days later due to multiple organ failure
Kim et al, ⁸ 2010	53	Male	South Korea	Sharp mental decline	Yes	Acute epidural haematoma	Bone and dural tumour, and epidural haematoma	Vegetative state
Kim et al, ⁹ 2016	41	Male	South Korea	Headache, sharp mental decline and vomiting	Yes	Osteolytic lesion and acute epidural haematoma	Bone tumour and acute and chronic epidural haematoma	Died four months later due to liver failure
This case	59	Female	Thailand	Headache and sharp mental decline	No	Osteolytic lesion and acute epidural haematoma	Bone tumour and epidural haematoma	Died four days later due to multiple organ failure

AEH: acute epidural haematoma; HCC: hepatocellular carcinoma.

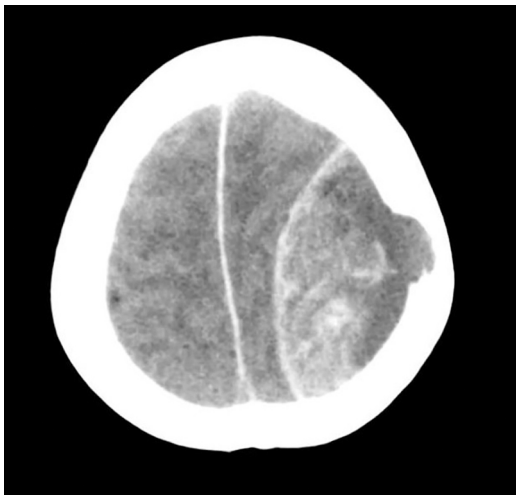


Figure 1 Head CT: left-sided frontoparietal acute epidural haematoma. Osteolytic cranial vault lesion of a probable metastatic aetiology.

prominent nuclei and a trabecular structure, compatible with hepatocellular carcinoma (HCC) metastases. In the end, the patient died four days after surgery.

The incidence of HCC is less than 5% and it is typically located in the lungs (34–70%) and lymph nodes (16–40%). Bone metastases make up 1.6–16%, generally in the vertebrae, pelvis and ribs, being rare in the skull (0.4–1.6%).¹

An AEH usually develops secondary to a traumatic brain injury, but may arise spontaneously in the context of neoplastic diseases, infections, vascular malformations or coagulation disorders. Intracranial haemorrhage secondary to metastasis is rare, with an incidence of 0.9–11%. They usually occur within a tumour or the brain itself, and very rarely in the epidural area.^{6–8} The formation of an AEH secondary to a HCC metastasis is very rare. In the literature reviewed, we found just eight published cases, as set out in Table 1.^{2–9} According to this review, they generally affect Asian males, with or without a history of known liver disease, who present with a headache and sharp mental decline. AEH is diagnosed by CT, although bone lesions are only observed in half of cases. All patients undergo surgery and the prognosis is poor, either due to the AEH itself or liver failure. It should be noted that this is the first case reported in a female.

The literature review performed by Hsieh et al.¹ gathers a total of 68 cases of skull metastases due to HCC. The most common form of presentation is a subcutaneous mass, although 10% of patients present intracranial haemorrhagic

events. It is not known why these types of metastasis cause AEH, although the most widely accepted hypothesis posits that it is due to the breakdown of vessel structures in the peritumoral tissue, secondary to tumour growth.^{1,9}

In conclusion, we should consider the existence of skull metastases in patients with HCC, particularly if they present with neurological signs and/or symptoms. We should also keep in mind the risk of fulminating AEH.

References

1. Hsieh CT, Sun JM, Tsai WC, Tsai TH, Chiang YH, Liu MY. Skull metastasis from hepatocellular carcinoma. *Acta Neurochir (Wien)*. 2007;149:185–90.
2. Nakagawa Y, Yoshino E, Suzuki K, Tatebe A, Andachi H. Spontaneous epidural hematoma from hepatocellular carcinoma metastasis to the skull. *Neurol Med Chir (Tokyo)*. 1992;32:300–2.
3. Nakao N, Kubo K, Moriwaki H. Croneal metastasis of hepatocellular carcinoma associated with chronic epidural hematoma. *Neurol Med Chir (Tokyo)*. 1992;32:100–3.
4. Hayashi K, Matsuo T, Kiruhara M, Daikoku M, Kitange G, Shibata S. Skull metastasis of hepatocellular carcinoma associated with acute epidural hematoma: a case report. *Surg Neurol*. 2000;53:379–82.
5. McIver JI, Scheithauer BW, Rydberg CH, Atkinson JLD. Metastatic hepatocellular carcinoma presenting as epidural hematoma: case report. *Neurosurgery*. 2001;49:447–9.
6. Kanai R, Kubota H, Terada T, Hata T, Tawarayama E, Fujii K. Spontaneous epidural hematoma due to skull metastasis of hepatocellular carcinoma. *J Clin Neurosci*. 2009;16:137–40.
7. Woo KM, Kim BC, Cho KT, Kim EJ. Spontaneous epidural hematoma from skull base metastasis of hepatocellular carcinoma. *J Korean Neurosurg Soc*. 2010;47:461–3.
8. Kim BG, Yoon SM, Bae HG, Yun IG. Spontaneous intracranial epidural hematoma originating from dural metastasis of hepatocellular carcinoma. *J Korean Neurosurg Soc*. 2010;48:166–9.
9. Kim YS, Moon KS, Lee KH, Jung TY, Jang WY, Kim IY, et al. Spontaneous acute epidural hematoma developed due to skull metastasis of hepatocellular carcinoma: a case report and review of the literature. *Oncol Lett*. 2016;11:741–4.

Ana Delgado Maroto*, María del Moral Martínez,
Carmelo Diéguez Castillo,
Francisco Javier Casado Caballero

*Unidad de Gestión Clínica de Digestivo, Hospital
Universitario San Cecilio, Granada, Spain*

*Corresponding author.

E-mail address: anadmgr@gmail.com (A. Delgado Maroto).
2444-3824/

© 2018 Elsevier España, S.L.U. All rights reserved.