

mild, and reverts with treatment, so liver biopsies are not routinely performed. The finding of vasculitis in liver tissue has been described in autopsies (in patients who died from this disease),⁶ and a case has been reported in which a liver biopsy revealed periportal inflammation with increased polymorphonuclear cells.⁷ With proper treatment, the liver symptoms return to normal. Treatment of KD is 2 g/kg non-specific gammaglobulin, with the possibility of administering a second dose after 24–72 h if the fever persists. About 15% of patients do not respond to this treatment,^{8,9} so intravenous corticosteroids and even infliximab are necessary in non-responders. The presence of hepatic dysfunction is associated with a poor response to gammaglobulin and the appearance of coronary aneurysms,^{3–5,10} as occurred in our patient. For this reason, the latest clinical guidelines published in Japan and the United Kingdom recommend the use of corticosteroids concomitantly with the gammaglobulin as a first option in these cases,¹¹ in order to avoid the appearance of coronary aneurysms, which is the major morbidity. It is important to know that KD can be the cause of febrile hepatic dysfunction of unclear aetiology, and is a prognostic factor of a poor responder to gammaglobulins.

References

1. Kontopoulou T, Kontopoulos DG, Vaidakis E, Mousoulis GP. Adult Kawasaki disease in a European patient: a case report and review of the literature. *J Med Case Rep.* 2015;9:1–7.
2. Singh R, Ward C, Walton M, Persad R. Atypical Kawasaki disease and gastrointestinal manifestations. *J Paediatr Child Health.* 2007;12:235–7.
3. Kobayashi T, Inoue Y, Takeuchi K, Okada Y, Tamura K, Tomomasa T, et al. Prediction of intravenous immunoglobulin unresponsiveness in patients with Kawasaki disease. *Circulation.* 2006;113:2606–12.
4. Egami K, Muta H, Ishii M, Suda K, Sugahara Y, Iemura M, et al. Prediction of resistance to intravenous immunoglobulin treatment in patients with Kawasaki disease. *J Pediatr.* 2006;149:237–40.
5. Sano T, Kurotobi S, Matsuzaki K, Yamamoto T, Maki I, Miki K, et al. Prediction of non-responsiveness to standard high-dose gamma-globulin therapy in patients with acute Kawasaki disease before starting initial treatment. *Eur J Pediatr.* 2007;166:131–7.
6. Amano S, Hozama F, Hamashima Y. Pathology of Kawasaki disease. II. Distribution and incidence of the vascular lesions. *Jpn Circ J.* 1979;43:741–8.
7. Edwards KM, Glick AD, Greene HI. Intrahepatic colangitis associated with mucocutaneous lymph node syndrome. *Pediatr Gastroenterol Nutr.* 1985;4:140–2.
8. Durongpositkul K, Soongswang J, Laohaprasitiporn D, Nana A, Prachuabmoh C, Kangkagate C. Immunoglobulin failure and retreatment in Kawasaki disease. *Pediatr Cardiol.* 2003;24:145–8.
9. Wallace CA, French JW, Kahn SJ, Sherry DD. Initial intravenous gammaglobulin treatment failure in Kawasaki disease. *Pediatrics.* 2000;105:e78.
10. Sleeper LA, Minich LL, McCrindle BM, Li JS, Mason W, Colan SD, et al. Evaluation of Kawasaki disease risk-scoring systems for intravenous immunoglobulin resistance. *J Pediatr.* 2011;158:831–5.
11. Research Committee of the Japanese Society of Pediatric Cardiology and Cardiac Surgery Committee for Development of Guidelines for Medical Treatment of Acute Kawasaki Disease. Guidelines for medical treatment of acute Kawasaki disease: Report of the Research Committee of the Japanese Society of Pediatric Cardiology and Cardiac Surgery (2012 revised version). *Pediatr Int.* 2014;56:135–58.

Rosmari Vázquez Gomis^{a,*}, Ignacio Izquierdo Fos^b,
Andrea López Yañez^c, Mabel Mendoza Durán^c,
María Isabel Serrano Robles^b, Consuelo Vázquez Gomis^c,
José Pastor Rosado^c

^a *Servicio de Digestivo Infantil, Hospital General Universitario de Elche, Elche, Alicante, Spain*

^b *Servicio de Cardiología Infantil, Hospital General Universitario de Elche, Elche, Alicante, Spain*

^c *Servicio de Pediatría, Hospital General Universitario de Elche, Elche, Alicante, Spain*

* Corresponding author.

E-mail address: rosvazquezgomis@yahoo.es
(R. Vázquez Gomis).

Sister Mary Joseph's nodule: Umbilical metastasis from gallbladder cancer[☆]



Nódulo de la hermana María José: metástasis umbilical de cáncer de vesícula

Dear Editor,

Sister Mary Joseph nodule (SMJN) is an umbilical metastasis of any primary tumour.^{1–4} It can be the first sign of an

undiagnosed neoplasm, or can appear as a recurrence or progression of an already known tumour.^{1,5} We present a new case caused by a gallbladder cancer, and review the topic.

A 76-year-old man presented with a 3-month history of right upper quadrant pain and dyspepsia, accompanied by acholia, choluria and pruritus in the previous 10 days. He reported that he noticed umbilical discomfort that he related with a previous herniorrhaphy. His medical history included atrial fibrillation and umbilical herniorrhaphy. Physical examination found right upper quadrant pain, a petrous tumour in the umbilical region and jaundice. Blood tests revealed gamma glutamyl transferase (GGT): 718 IU/L, alkaline phosphatase (ALP): 391 IU/L, total bilirubin: 9.1; carcinoembryonic antigen (CEA): 92.7 mg/dL and CA19.9: 206 IU/L. Abdominal ultrasound and computed tomography (CT) scans showed a large heterogeneous solid lesion with poorly defined borders in the perihilar region, emerging from

DOI of refers to article:

<http://dx.doi.org/10.1016/j.gastrohep.2015.05.010>

[☆] Please cite this article as: Ramia JM, de la Plaza R, López-Marcano A, Kuhnhardt A, David Gonzales J. Nódulo de la hermana María José: metástasis umbilical de cáncer de vesícula. *Gastroenterol Hepatol.* 2016;39:302–304.

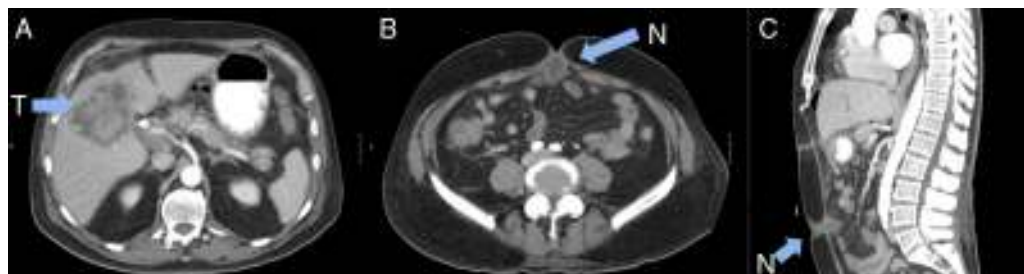


Figure 1 Computed tomography scan: (A) hepatic tumour. (B and C) Umbilical nodule (N).

the fundus of the gallbladder and causing bilateral dilatation of the intrahepatic bile duct; the walls of the gallbladder were thickened with increased uptake, and the patient also had numerous gallstones (Fig. 1A). There were multiple lymphadenopathies in the hepatic hilum, some measuring up to 30mm, and an implant in the umbilical region (Fig. 1B and C). Percutaneous transhepatic cholangiography and external–internal biliary drainage were performed, observing stenosis of the bile duct due to extrinsic compression. Biliary cytology was reported as carcinoma, and fine-needle aspiration of the lesion as poorly differentiated adenocarcinoma. A biliary stent was placed with resolution of the jaundice, but the patient developed uncontrollable vomiting and complete dietary intolerance. The CT scan was repeated, confirming marked gastric and oesophageal dilatation due to stenosis in the first duodenal portion due to compression of the tumour, which had advanced. Placement of a duodenal stent was attempted but was not possible, so palliative bypass surgery was carried out.

A supra-umbilical midline laparotomy was performed, identifying the following structures: a 5-cm implant that encompassed the umbilical region and greater omentum (Fig. 2); a mass that encompassed liver segments 4b, 5 and 8 and the gallbladder; and peritoneal implants in the pelvis and epiploic foramen. The umbilical implant was resected and two-layer gastrojejunostomy performed in the posterior wall of the stomach. Histological study showed an epithelial tumour composed of neoplastic cells with ample, slightly eosinophilic cytoplasm, an irregular, enlarged vesicular nucleus and a nucleolus, abundant mitoses, and no clear images of lymphovascular invasion. The immunohistochemical study was consistent with biliary adenocarcinoma. The patient died in the postoperative period due to respiratory failure.

Malignant umbilical lesions can be primary or metastatic.⁶ The first umbilical metastasis was described by Storer in 1864, but the best-known description was published by Dr. W. Mayo in 1928.¹ Later, in 1949, British surgeon H. Bailey named it SMJN, in honour of Sister Mary Joseph, nurse and surgical assistant of Dr. Mayo at St. Mary's Hospital in Rochester (MN, USA), as it was she who observed the presence of an umbilical nodule in some patients with advanced gastric cancers.^{1–10}

Although SMJN is said to occur in 1–3% of patients with pelvic and abdominal tumours, the number of cases described in the medical literature is much lower, and it appears to be more common in women.^{1,4,5,9} It is most often caused by stomach and colon tumours in men, and ovarian tumours in women.^{1,2} SMJNs have their primary origin in tumours of the gastrointestinal (35–65%) and genitourinary

tract (12–35%), unknown origin (15–30%) and other tumours (breast, lung, etc.) (3–6%).^{1,2,6,8,10} Only 9 cases of SMJN due to gallbladder cancer have been described in PubMed (1966–2015).^{1,7}

The aetiological mechanism of SMJN is not fully understood. In abdominal neoplasms, direct infiltration through the peritoneum—especially if there is peritoneal dissemination as in our case—is the most logical explanation, but this route is not feasible in other tumours. Other mechanisms have therefore been proposed (arterial, venous or lymphatic dissemination or via embryonic structures [urachus]).^{1,2,4,5,8,9} Liver metastases have been observed in most patients with SMJN, suggesting possible spread via the falciform ligament.^{1,4}

SMJN varies in colour, and can be white, purplish or brownish.^{1,9} The nodules are typically firm and irregular, located at dermal, subcutaneous or peritoneal level, and measuring 1–2 cm, although nodules of up to 10 cm have been described; they may be painful and occasionally itchy.

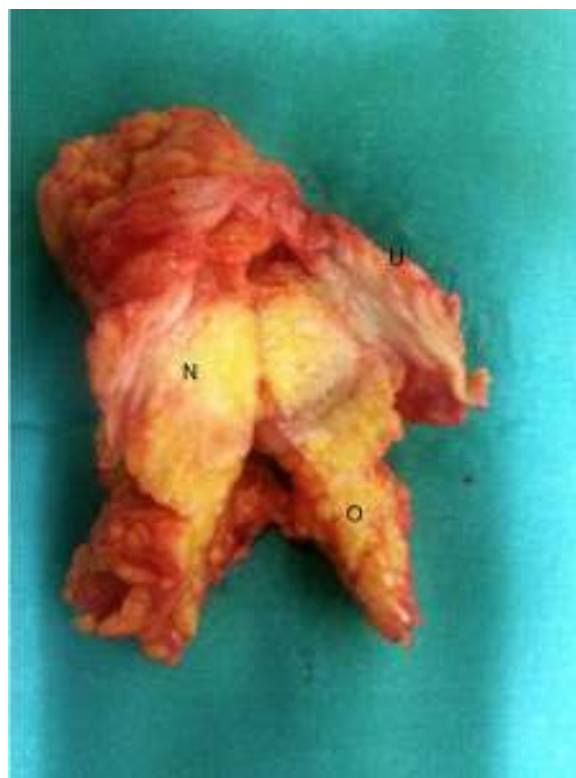

Figure 2 Surgical specimen. O, omentum; N, nodule; U, umbilicus.

They can sometimes ulcerate or fistulise, with a serous, purulent or bloody discharge. If there is an umbilical hernia, or in large lesions, they can infiltrate the gastrointestinal tract, causing bowel obstruction.⁵

Radiological diagnosis by abdominal ultrasound or CT can be complicated.^{4,8} The use of positron emission tomography (PET)-CT has been described in 1 patient, with good results.⁸ Fine-needle aspiration of SMJN is simple, and the cytological study usually obtains a diagnosis of malignancy that enables a correct diagnostic approach, although it may not always define the histological type.^{1,3} The differential diagnosis of SMJM includes: Paget disease, haemangioma, umbilical hernia, endometriosis, hypertrophic scar, granuloma, pilonidal sinus, dermoid cyst, mycosis, psoriasis, eczema, etc.^{1,3}

SMJN is an ominous sign of metastatic disease.^{1,3,5,9,10} Mean survival following diagnosis varies between 2 and 11 months, although this is further reduced if it appears as a recurrence after treatment of the primary tumour.^{1,5,10} Somewhat longer survivals (17–21 months) have been obtained with surgery and chemotherapy.^{1,4,5} Surgical excision is only recommended if it is a solitary metastasis or causes complications, and is pointless in cases of unresectable disseminated disease.¹ The prognosis is related with the primary tumour, with SMJN caused by ovarian cancer having better survival rates.^{1,4}

In conclusion, when a hard umbilical nodule is found, the diagnosis of SMJN should be borne in mind, even if the patient does not have a previous diagnosis of neoplasm. Prognosis is poor, since it appears in patients with disseminated disease. Resection is not generally indicated.

References

1. Palaniappan M, Jose WM, Mehta A, Kumar K, Pavithran K. Umbilical metastasis: a case series of our Sister Joseph

- nodules from four different visceral malignancies. *Current Oncol.* 2010;17:78–81.
2. Agrawal V, Garg PK, Jaswal V. Umbilical nodule in cholangiocarcinoma. *Saudi J Gastroenterol.* 2012;18:345–6.
3. Bai XL, Zhang Q, Masood W, Masood N, Tang Y, Cao CH, et al. Sister Mary Joseph's nodule as a first sign of pancreatic cancer. *World J Gastroenterol.* 2012;18:6686–9.
4. Gabriele R, Conte M, Egidi F, Borghese M. Umbilical metastasis: current viewpoint. *World J Surg Oncol.* 2005;3:313–5.
5. Ullery BW, Wachtel H, Raper SE. Sister Mary Joseph's nodule presenting as large bowel obstruction: a case report and brief review of the literature. *J Gastrointest Surg.* 2013;17:1832–5.
6. Larentzakis A, Theodorou L, Fili K, Manataki A, Bizimi V, Tibishrani M, et al. Sister Mary Joseph's nodule: three case reports. *Cases J.* 2008;1:182.
7. Balsarkar DJ, Jakhare S. Sister Mary Joseph nodule. *Indian J Gastroenterol.* 2012;31:38–9.
8. Tan MLM, Padhy AK. Umbilical metastatic deposit from recurrent cholangiocarcinoma: F18-FDG-PET-CT findings. *Singap Med J.* 2011;52:236–8.
9. Abu-Hilal M, Newman JS. Sister Mary Joseph and her nodule: historical and clinical perspective. *Am J Med Sci.* 2009;357:271–3.
10. Powell JL. Powell's pearls: eponyms in medical and surgical history. Sister Joseph's Nodule; Sister Mary Joseph (1856–1939). *J Surg Educ.* 2011;68:442–3.

Jose Manuel Ramia*, Roberto de la Plaza, Aylhin López-Marcano, Andree Kuhnhardt, Jhonny David Gonzales

Unidad de Cirugía Hepatobiliopancreática, Servicio de Cirugía General y Aparato Digestivo, Hospital Universitario de Guadalajara, Guadalajara, Spain

* Corresponding author.

E-mail address: jose.ramia@hotmail.com (J.M. Ramia).