



Enfermedades Infecciosas y Microbiología Clínica

www.elsevier.es/eimc



Diagnosis at first sight

Erythema induratum of Bazin—A cutaneous manifestation of tuberculosis

Eritema indurado de Bazin: una manifestación cutánea de la tuberculosis

Maria Ana Quadros Flores^{a,*}, Gustavo Almeida Silva^b, Paulo Filipe^{b,c}, Sérgio Eduardo Paulo^{a,d}

^a Infectious Diseases Department – Unidade Local de Saúde de Santa Maria, EPE/Hospital de Santa Maria, Lisboa, Portugal

^b Dermatology and Venereology Department – Unidade Local de Saúde de Santa Maria, EPE/Hospital de Santa Maria, Lisboa, Portugal

^c University Clinic of Dermatology – Faculdade de Medicina da Universidade de Lisboa, Lisboa, Portugal

^d Unidade Local do Programa de Prevenção e Controlo das Infecções e da Resistência aos Antimicrobianos – Unidade Local de Saúde de Santa Maria, EPE/Hospital de Santa Maria, Lisboa, Portugal

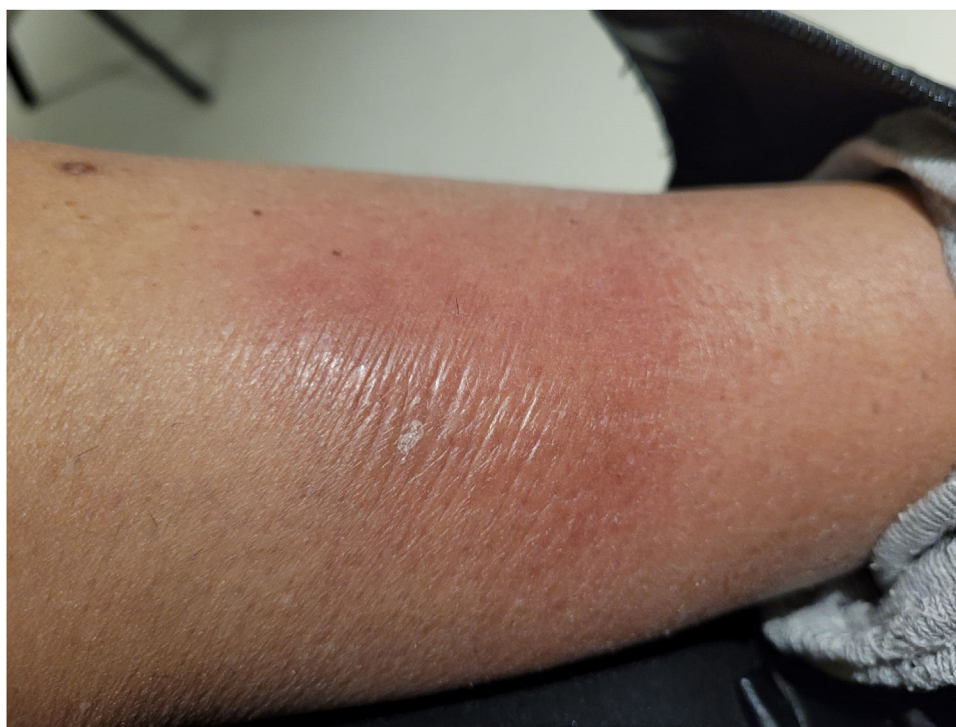

Fig. 1. Painful erythematous subcutaneous nodules on the patient's left leg.

We report the case of a 59-year-old retired woman with a medical history of coronary disease and spinal disk herniation, causing chronic pain, medicated with acetylsalicylic acid, rosuvastatin, pregabalin, and tapentadol. She sought healthcare services due to

the appearance of tender erythematous–violaceous subcutaneous nodules on her left leg, progressively growing, with no other complaints (Fig. 1). She had been experiencing these symptoms for eight months, which were initially interpreted as cellulitis, therefore, she underwent several courses of antibiotic therapy, with no clinical improvement. Due to suspicion of erythema nodosum, she also received non-steroidal anti-inflammatory treatment, without improvement.

* Corresponding author.
E-mail address: ma.naqfs@gmail.com (M.A. Quadros Flores).

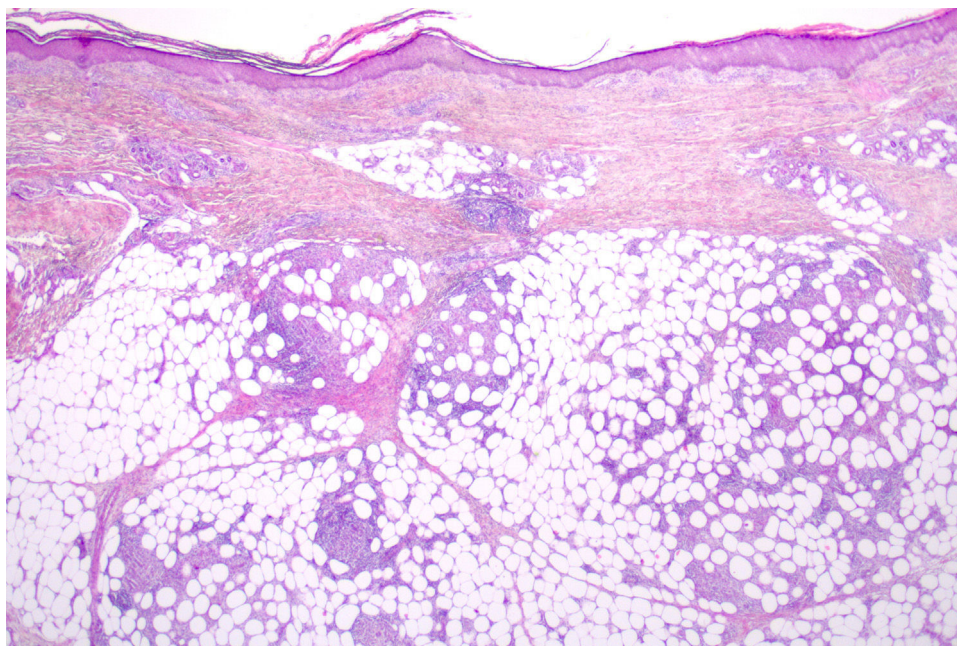


Fig. 2. A skin histological section demonstrates multiple epithelioid granulomas without necrosis within the hypodermis. The dermis and epidermis are unremarkable (H&E, 16×).

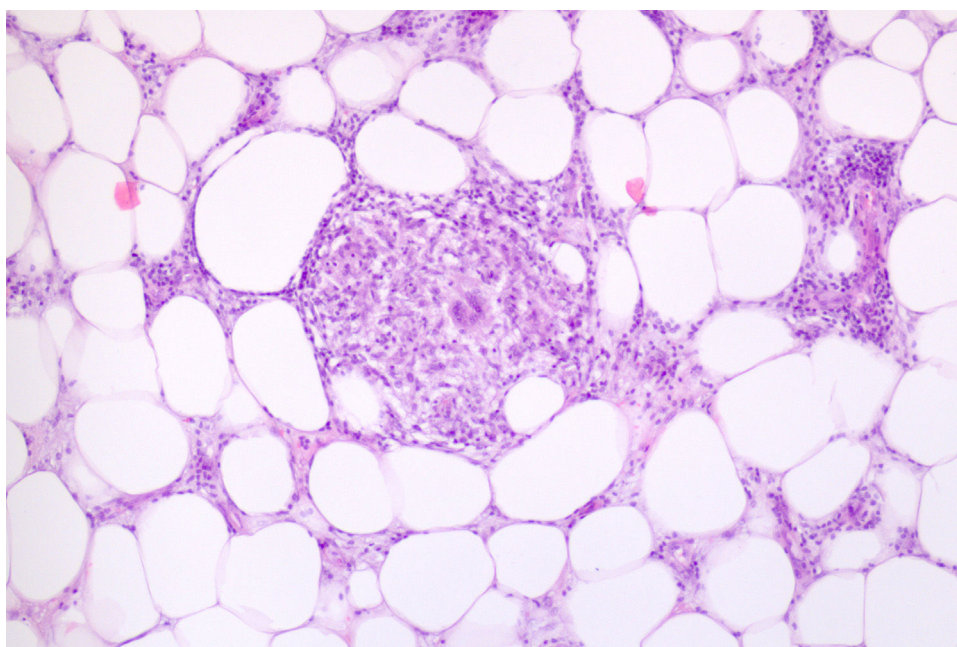


Fig. 3. A single epithelioid granuloma with surrounding lymphoid tissue is observed, centered by a Langhans giant cell (H&E, 100×).

Therefore, she was referred to Dermatology where an incisional biopsy was performed. RT-PCR revealed the presence of *Mycobacterium tuberculosis* DNA. Cutaneous histopathology showed granulomas of epithelioid cells, without necrosis but with a lymphocytic crown, scattered throughout the lobes of the adipose panniculus, with intact septa and no vasculitis (Figs. 2 and 3). No acid-fast bacilli were seen in the Ziehl–Neelsen stain. These findings are consistent with lobular granulomatous panniculitis, and the patient was referred to the Tuberculosis Treatment Reference Center for anti-tubercular therapy.

Tuberculosis (TB) is a mycobacterial infection caused by *M. tuberculosis* that usually affects the lungs but can potentially affect almost every organ. Cutaneous involvement is a relatively

uncommon manifestation with various clinical findings that include tuberculids, which are a group of dermatoses with tuberculoid histology and the absence of tubercle bacilli. They are considered cutaneous hypersensitivity eruptions to *M. tuberculosis*. One of the three main tuberculid disorders is erythema induratum of Bazin (EIB), also known as “nodular vasculitis” which is a granulomatous, lobular panniculitis of the lower extremities. Although usually showing small and medium vessel vasculitis in histopathology, this is not a *sine qua non* condition for the diagnosis. Several other conditions have been associated with EIB, both infectious and non-infectious, although tuberculosis remains the most common one. The diagnosis of TB-associated EIB is made by the combination of clinical features, histopathologic findings, and evidence for *M. tuberculosis*.

Originality

The authors state that this article is not under consideration for publication elsewhere, that its publication is approved by all authors, and that, if accepted, it will not be published elsewhere in the same form, in English or in any other language, including electronically without the written consent of the copyright-holder.

Funding

This article received no specific grant from any funding agency in the public, commercial, or not-for-profit sectors.

Conflict of interest

None.

Acknowledgments

We are grateful to the patient for providing permission to publish the case.