



# Enfermedades Infecciosas y Microbiología Clínica

www.elsevier.es/eimc



Diagnosis at first sight

Patient from India with fever and uncommon findings

Paciente de la India con fiebre y hallazgos inusuales

Andrea Vergara<sup>a,b,\*</sup>, Mariana José Fernandez-Pittol<sup>a,1</sup>, Cristina Gutierrez-Fornes<sup>c</sup>,  
Miriam José Álvarez-Martínez<sup>a,b</sup>

<sup>a</sup> Microbiology Department, Hospital Clínic, CDB – Universitat de Barcelona, Barcelona, Spain

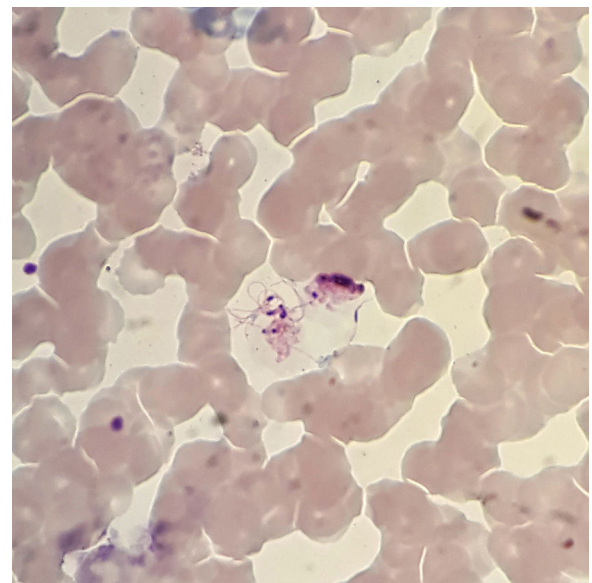
<sup>b</sup> Institute for Global Health (ISGlobal), Barcelona, Spain

<sup>c</sup> Laboratori Clínic ICS Camp de Tarragona – Terres de l'Ebre, Hospital Universitari de Tarragona Joan XXIII (C. Gutierrez-Fornes), Spain

A 28-years-old male patient from India that had not travelled to his country in the last nine months presented to the emergency room with general discomfort, dysthermia feeling, sweating, chills, and shivering. In the physical examination, temperature was quantified in 40.5 °C. No neurological deficit or peripheral lymphadenopathy was found. Blood was taken and sent to the local laboratory for examination and then sent to our hospital in order to confirm the diagnosis. This sample was stored for almost 3 days at room temperature.

Giemsa stain showed some strange forms, but the morphology of parasite was compatible with *Plasmodium vivax*. These forms were described like a structure smaller than a blood cell with peripheral flagella, a dark nucleus and mobile filament forms compatible with exflagellating microgametocytes (Fig. 1). The patient was treated with primaquine for two weeks and the infection was finally confirmed with PCR.

In the natural life cycle of the malarial parasites, exflagellation of the microgametocyte, fertilization, and ookinetes production occur in the mosquito gut. The usual plasmodium forms seen in human peripheral blood smears include trophozoites, schizonts, macro, and microgametocytes. However, it has been demonstrated that exflagellation can occur *ex vivo*. Here a case of exflagellation in human blood is described. Exflagellation *ex vivo* is very uncommon but since 1880, Laveran had already noticed, while examining microscopically the blood of a patient suffering from malaria, “a body with mobile peripheral filaments” and “mobile filament freed for the body”.<sup>1</sup> Exflagellation process was first described in 1884.<sup>2</sup> Five years later, Golgi et al. saw few flagellate forms corresponding to those described by Laveran.<sup>3</sup> In 1891, Romanowsky contributed with a staining method based on eosin and methylene blue that allowed seeing better these structures.<sup>4</sup> Marchiafava et al. in 1892 also described “a form with flagella”.<sup>5</sup> However, it was not until 1898 that Manson and Ross published that malaria organism



**Fig. 1.** Image from the thin blood film (Giemsa stain, 100x). It shows a mobile form with peripheral flagella and a dark nucleus compatible with exflagellating microgametocyte.

had a second life, outside and independent of the human body.<sup>6</sup> Nowadays, it is known that exflagellation of the microgametocyte occurs in the gut of mosquitoes, but if malaria blood is observed some time after it has been withdrawn from the blood vessels another form is seen, “the flagellated body”. By 1897, MacCallum discovered exflagellation and recognized its significance in the life cycle of malaria parasite. He described the fertilization process and recognized the flagellum as the male gamete.<sup>7</sup> After that, there are several references to this phenomenon.<sup>8</sup>

According to some authors, exflagellation can be induced *in vitro* by dropping the temperature of cultured gametes from 37 °C to 28 °C, thus simulating the change from host to

\* Corresponding author.

E-mail address: vergara@clinic.cat (A. Vergara).

<sup>1</sup> These authors contributed equally to this article.

vector temperatures, by either increasing the pH from 7.5 to 8.2 or by the addition of a gametocyte-activating factor (GAF), the oxanthurenic acid. This compound has been isolated from the mosquito gut and is supposed to be implicated in the maturation of the microgametocytes.<sup>9</sup> In this case, probably a delay in sample processing and a dropping of the temperature could be the cause of exflagellation process. Fertilization has been shown to take place, at least *in vitro* conditions, almost immediately following exflagellation within 10 to 20 min after the initiation of gametogenesis.<sup>10</sup>

The experimental *in vitro* phenomenon of exflagellation is very common, but it is rarely described in the clinical setting of malaria. Nevertheless, it is important to consider it when atypical structures are found in the blood from a patient with suspected malaria to avoid mistake in the diagnosis.

## Fundings

None.

## Conflict of interest

The authors declare no conflict of interest.

## References

1. Laveran CLA. A newly discovered parasite in the blood of patients suffering from malaria. Parasitic etiology of attacks of malaria. *Rev Infect Dis.* 1982;4:908–11, <http://dx.doi.org/10.1093/4.4.908>
2. Hewitt R. Bird malaria [monograph]. *Am J Hyg Monogr.* 1940:15.
3. Golgi C. On the cycle of development of malarial parasites in tertian fever: differential diagnosis between the intracellular malarial parasites of tertian and quartan fever. In: Kean BH, Mott KE, Russell AJ, editors. *Tropical medicine and parasitology: classic investigations.* New York: Cornell University Press; 1978. p. 26–35.
4. Garnham PCC. *Malaria parasites and other Haemosporidia.* Oxford: Blackwell Scientific Publications; 1966.
5. Marchiafava E, Bignami A. On summer–autumn malarial fevers. London: New Sydenham Society; 1894.
6. Manson P. Surgeon-Major Ronald Ross's recent investigations on the mosquito-malaria theory. *Br Med J.* 1898;1:1575–7, <http://dx.doi.org/10.1136/bmj.1.1955.1575>
7. MacCallum WG. On the haematozoan infections of birds. *J Exp Med.* 1898;3:117–36.
8. Tembhare P, Shirke S, Subramanian PG, Sehgal K, Gujral S. Exflagellated microgametes of *Plasmodium vivax* in human peripheral blood: a case report and review of the literature. *Indian J Pathol Microbiol.* 2009;52:252–4.
9. Billker O, Shaw MK, Margos G, Sinden RE. The roles temperature, pH and mosquito factors as triggers of male and female gametogenesis of *Plasmodium berghei* *in vitro*. *Parasitology.* 1997;114:1–7.
10. Carter R, Nijhout MM. Control of gamete formation (exflagellation) in malaria parasites. *Science.* 1977;195:407–9.