




Enfermedades Infecciosas y Microbiología Clínica

www.elsevier.es/eimc



Scientific letter

Importance of the treatment of rectal *Mycoplasma genitalium* in men who have sex with men[☆]



Relevancia del tratamiento de portadores rectales asintomáticos de *Mycoplasma genitalium* en hombres que tienen sexo con hombres

Dear Editor,

Mycoplasma genitalium (MG) is responsible for 10–25% of cases of non-gonococcal urethritis (NGU) in Europe.¹ The rate of macrolide resistance in men who have sex with men (MSM) is currently estimated to be up to 35%,² probably due to long-term use of azithromycin for empirical treatment of NGU. MG infection can cause various complications in both genders and can facilitate the transmission of human immunodeficiency virus (HIV).³ Targeted therapy and a careful study of sexual contact in cases of NGU is required to control this infection. The purpose of the following case report is to determine the best treatment for MG urethritis.

A 31-year-old male patient presented with HIV infection, which was adequately controlled with antiretroviral therapy. He reported experiencing symptoms of urethral discharge and dysuria for several weeks. He disclosed having had unprotected sex with his permanent partner within the last 3 months. Once urethral

samples had been taken for culture of *Neisseria gonorrhoeae* (NG) and nucleic acid amplification testing (NAAT) for NG and *Chlamydia trachomatis* (CT) (Anyplex[®] CT/NG Real-time Detection kit [Seegene]), empirical treatment with ceftriaxone 1 g IM and oral azithromycin 1 g was prescribed for both the patient and his partner. It was recommended that unprotected sex be avoided until the results came back. *Haemophilus parainfluenzae* that was susceptible to the prescribed treatment was isolated from the microbiological culture, but all other tests were negative. Nevertheless, the patient continued to have discharge after 10 days and therefore the culture and dual NAAT were repeated, which were negative. NAAT for MG (RealCyler[®] Monotest MGTVUS [Progenie Molecular]) in urine was then requested, which gave a positive result. Given that a dose of 1 g azithromycin may not have been enough to control the infection, a dose of 500 mg oral azithromycin followed by 250 mg/day for 4 days was prescribed, with no clinical improvement observed. Check-up NAAT showed that MG was still present in the urethra. Since macrolide-resistant MG infection was suspected, empirical treatment with moxifloxacin 400 mg/day for 10 days was prescribed for both the patient and his partner. NAATs for pharyngeal, urethral and rectal MG were also conducted, with the latter proving positive. After completing treatment, the patient was asymptomatic and a test-of-cure performed at 3 weeks was negative for both. Fig. 1 shows the progress of the patient and his partner over time.

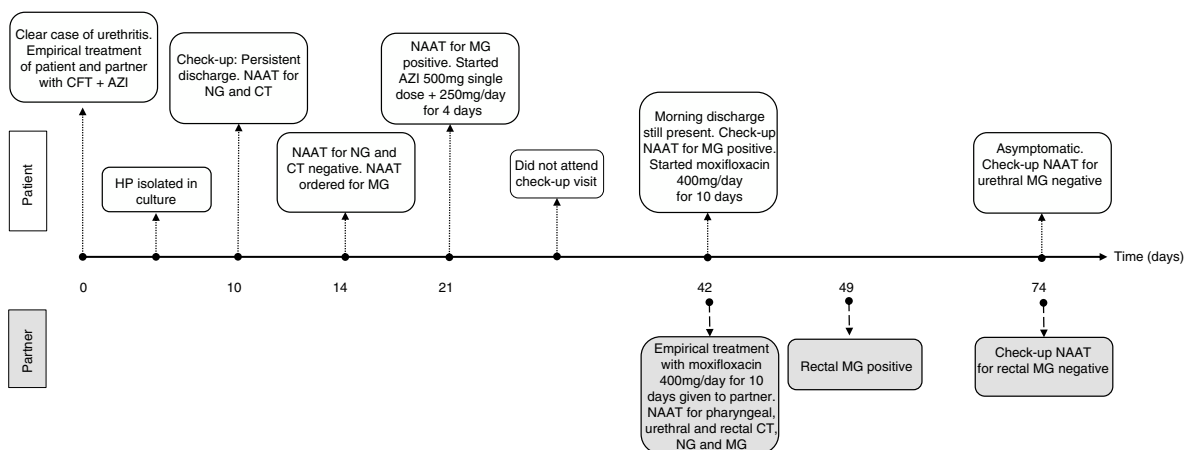


Fig. 1. Progress of the case over time.

AZI: azithromycin; CFT: ceftriaxone; CT: *Chlamydia trachomatis*; HP: *Haemophilus parainfluenzae*; MG: *Mycoplasma genitalium*; NAAT: nucleic acid amplification testing; NG: *Neisseria gonorrhoeae*.

DOI of original article: <https://doi.org/10.1016/j.eimc.2018.07.003>

[☆] Please cite this article as: Riera-Monroig J, Fuertes I, Alsina M, Blanco JL. Relevancia del tratamiento de portadores rectales asintomáticos de *Mycoplasma genitalium* en hombres que tienen sexo con hombres. Enferm Infecc Microbiol Clin. 2019;37:544–545.

The European guideline on the management of NGU recommends performing NAAT for MG and for screening for macrolide resistance,^{4,5} despite the fact that these techniques are not available at many sites. At our unit, we test patients with NGU who do not respond to treatment and who have negative NG-CT NAAT results for MG, but we do not screen for macrolide resistance. The high rate of resistance of MG to this antibiotic group has resulted in single-dose azithromycin no longer being recommended for the empirical treatment of NGU in Europe.⁴ In patients who show no clinical or microbiological response to a 1 g single dose of oral azithromycin, the guideline recommends assuming that the patient has a macrolide-resistant strain and the recommended regimen would be to treat directly with moxifloxacin,⁴ as shown in this case report.

The role of rectal MG as a reservoir and the need to treat asymptomatic rectal MG carriers have been controversial.⁶ A recent study in MSM with MG urethritis showed that up to 40% of sexual contacts undergoing a rectal exam were positive for MG.⁷ The presence of rectal MG is often asymptomatic and rectal MG load is higher among patients with symptomatic proctitis than among asymptomatic rectal MG carriers.⁸ However, the prevalence of oropharyngeal MG is very low and does not appear to constitute a major reservoir.⁹

The European guideline on the management of MG infections recommends examining the sexual contacts of those infected with MG and treating them in the case of positive test results.^{4,5} There are no cost-effectiveness studies on the treatment of the sexual contacts of patients with MG infection, although this does seem to be an effective tool for reducing incidence rate. There is also no evidence of aspects such as the natural history of the infection or preventable morbidity with treatment, and therefore screening asymptomatic patients for MG is not currently recommended.¹⁰ In high-risk populations, such as HIV-positive MSM with higher rates of asymptomatic rectal MG carriers,⁶ targeted screening could be more cost-effective.

To conclude, cases such as the one observed in our case report support the need for and the importance of screening the sexual partners of patients with MG infection and for treating rectal MG carriers in order to reduce the incidence of MG infections. Furthermore, macrolide resistance testing using molecular test methods at the same as screening would allow targeted treatment.

References

1. Taylor-Robinson D, Jensen JS. *Mycoplasma genitalium*: from chrysalis to multi-colored butterfly. *Clin Microbiol Rev.* 2011;**24**:498–514.
2. Barberá MJ, Fernández-Huerta M, Jensen JS, Caballero E, Andreu A. *Mycoplasma genitalium* macrolide and fluoroquinolone resistance: prevalence and risk factors among a 2013–2014 cohort of patients in Barcelona, Spain. *Sex Transm Dis.* 2017;**44**:457–62.
3. Vandepitte J, Weiss HA, Bukkenya J, Kyakuwa N, Muller E, Buvé A, et al. Association between *Mycoplasma genitalium* infection and HIV acquisition among female sex workers in Uganda: evidence from a nested case-control study. *Sex Transm Infect.* 2014;**90**:545–9.
4. Horner PJ, Blee K, Falk L, van der Meijden W, Moi H. 2016 European guideline on the management of non-gonococcal urethritis. *Int J STD AIDS.* 2016;**27**:928–37.
5. Jensen JS, Cusini M, Gomberg M, Moi H. 2016 European guideline on *Mycoplasma genitalium* infections. *J Eur Acad Dermatol Venerol.* 2016;**30**:1650–6.
6. Soni S, Alexander S, Verlander N, Saunders P, Richardson D, Fisher M, et al. The prevalence of urethral and rectal *Mycoplasma genitalium* and its associations in men who have sex with men attending a genitourinary medicine clinic. *Sex Transm Infect.* 2010;**86**:21–4.
7. Slifirski JB, Vodstrcil LA, Fairley CK, Ong JJ, Chow EPF, Chen MY, et al. *Mycoplasma genitalium* infection in adults reporting sexual contact with infected partners, Australia, 2008–2016. *Emerg Infect Dis.* 2017;**23**:1826–33.
8. Bissessor M, Tabrizi SN, Bradshaw CS, Fairley CK, Hocking JS, Garland SM, et al. The contribution of *Mycoplasma genitalium* to the aetiology of sexually acquired infectious proctitis in men who have sex with men. *Clin Microbiol Infect.* 2016;**22**:260–5.
9. Hakre S, Casimier RO, Danboise BA, Peel SA, Michael NL, Scott PT, et al. Enhanced sexually transmitted infection screening for *Mycoplasma genitalium* in human immunodeficiency virus-infected US Air Force Personnel. *Clin Infect Dis.* 2017;**65**:1585–8.
10. Golden MR, Workowski KA, Bolan G. Developing a public health response to *Mycoplasma genitalium*. *J Infect Dis.* 2017;**216**:S420–6.

José Riera-Monroig^a, Irene Fuertes^{a,*}, Mercè Alsina^a,
José Luis Blanco^b

^a Servicio de Dermatología, Hospital Clínic de Barcelona, Universitat de Barcelona, Barcelona, Spain

^b Servicio de Enfermedades Infecciosas, Hospital Clínic de Barcelona, Universitat de Barcelona, Barcelona, Spain

* Corresponding author.

E-mail address: ifuertes@clinic.cat (I. Fuertes).

<https://doi.org/10.1016/j.eimce.2019.04.007>
2529-993X/

© 2018 Elsevier España, S.L.U. and Sociedad Española de Enfermedades Infecciosas y Microbiología Clínica. All rights reserved.

Infección parotídea por *Mycobacterium malmoense*



Mycobacterium malmoense parotid gland infection

Case report

A 2-year old girl visited the clinic with a right preauricular mass. Prior to this, she was healthy, with no medical history of interest and had received all her immunisations. Her parents are from Ecuador and her father had tuberculosis which was treated correctly 10 years ago. Examination revealed a soft, tender mass in the parotid gland measuring 0.5 cm in diameter and high fever at

the onset of symptoms. Viral parotitis was suspected and therefore blood tests were ordered, which were negative. Anti-inflammatory drugs were prescribed for one week. Twenty days after onset, the lesion had increased in size with signs of inflammation. Ultrasound images showed a multilocular lesion measuring 25 mm in diameter in the right parotid gland and lateral cervical and mastoid adenopathies suggestive of an inflammatory process with abscess. Antibiotic therapy with amoxicillin/clavulanic acid was commenced, with no response after 7 days. A broader study was therefore recommended. The Mantoux test was positive (12 mm) at 48 h. A QuantiFERON test was performed, which was negative. An ultrasound-guided fine-needle aspiration (FNA) biopsy was performed and the specimen culture was positive for *Mycobacterium malmoense*. Treatment with isoniazid, rifampicin, ethambutol and clarithromycin was started.

The lesion was confirmed by MR imaging (Figs. 1 and 2). The lesion was drained and its size decreased to 0.3 cm in diameter after three months of treatment. After 9 months of treatment, the lesion was stable and was surgically removed (Figs. 3 and 4).

☆ Please cite this article as: Juzga-Corrales DC, Moliner-Calderón E, Coll-Figa P, Leon-Vinó X. Infección parotídea por *Mycobacterium malmoense*. *Enferm Infecc Microbiol Clin.* 2019;**37**:545–547.