

ORIGINAL ARTICLE

Otoplasty Without Cartilage Section Using the Mustardé Technique. Presentation of Our Experience[☆]

Luis Mompó^{*}, Gracia Pastor, Marina Carrasco, M.^a Teresa Cuesta, José Dalmau

Servicio de Otorrinolaringología, Hospital Universitario Doctor Peset, Valencia, Spain

Received 12 February 2010; accepted 10 November 2010

KEYWORDS

Otoplasty;
Loop ears;
Antihelix
reconstruction

Abstract

Background: Some loop ear surgical procedures include cartilage section or abrasion, while others involve antihelix folding by simple suture.

Methods: Our results with the Mustardé technique are presented. This procedure avoids an aggressive action on the ear cartilage and makes antihelix folding easier.

Results: Good aesthetic results were obtained in all our patients, with a low complication rate.

Conclusions: We conclude this cartilage technical procedure has an advantage over the aggressive ones, with a low complication rate.

© 2010 Elsevier España, S.L. All rights reserved.

PALABRAS CLAVE

Otoplastia;
Orejas en asa;
Reconstrucción del
antehélix

Otoplastia sin sección cartilaginosa mediante la técnica de Mustardé. Presentación de nuestros resultados

Resumen

Introducción: Entre las técnicas quirúrgicas para el tratamiento de las orejas en asa podemos distinguir entre las que conllevan una sección ó abrasión del cartílago y las que únicamente se basan en la sutura del mismo.

Métodos: Presentamos nuestros resultados mediante la técnica de Mustardé, con la que evitamos realizar una acción agresiva sobre el cartílago, facilitando la formación del pliegue del antehélix.

Resultados: En nuestra serie hemos obtenido un buen resultado estético, con bajo porcentaje de complicaciones.

Conclusiones: Pensamos que esta técnica aporta una ventaja sobre las que son agresivas con el cartílago, presentando un bajo porcentaje de complicaciones.

© 2010 Elsevier España, S.L. Todos los derechos reservados.

[☆] Please cite this article as: Mompó L, et al. Otoplastia sin sección cartilaginosa mediante la técnica de Mustardé. Presentación de nuestros resultados. Acta Otorrinolaringol Esp. 2011;62:181–7.

^{*} Corresponding author.

E-mail address: mompo.lui@gva.es (L. Mompó).

Introduction

The auricular pavilion is formed by a thin sheet of elastic cartilage lined by epithelium, forming a series of anatomical contours. The lobe is formed by fibrous-fatty tissue (Fig. 1).

The ears are at the sides of the head, in front of the mastoid process and behind the temporomandibular joint, roughly equidistant between the outer angle of the eye and the external occipital protuberance. They are generally located between 2 horizontal lines, the top one marked by the edge of the eyebrows and the bottom one passing just below the subseptum. Their average height is 60–65 mm and their width, 25–35 mm.

The angle that they form with the head (known as the auriculocephalic angle) measures 20–30° on average. However, there are some amplitude variations, which range up to 90°.

In the post-auricular region, there are 2 important angles, one between the skull and the concha (cephaloconchal angle) and one between the scapha and the concha (scaphoconchal angle); both have an average value of 90°.

The antihelix fold and adequate conchal development give the ear its characteristic shape.

The arterial supply to the ear stems from the temporal and superficial branches of the external carotid artery in its anterior section, whereas for the posterior section, it is the occipital branch joined to the post-auricular branches of the external carotid.

Innervation originates from the auricular branch of the cervical plexus and the auriculotemporal branch of the inferior maxillary nerve.

The auricular pavilion deformity known as loop ears or protruding ears is due to one or both of the following deformities: a lack of antihelix fold or a hypertrophy of the concha cartilage. In many cases, both deformities coincide to a greater or lesser degree.

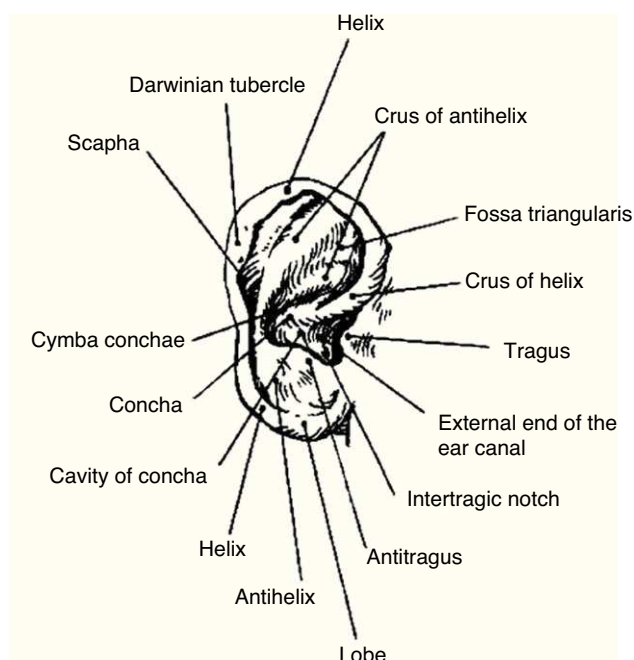


Figure 1 Diagram of the ear.

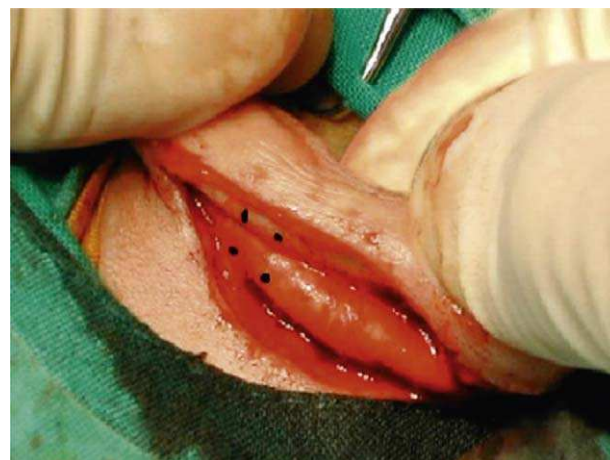

Figure 2 Otoplasty. Marking "U" suture points with a marker pen.

There are several techniques to help create an antihelix fold. Some of them involve conducting various types of sections in the ear cartilage, some by an anterior approach (such as that by Stenström^{1,2}) or by a posterior approach (such as those by Becker^{3,4} or Converse⁵), while others are more conservative with the cartilage, such as the technique by Mustardé.⁶

Surgical Technique

Once the patient is intubated, we carry out anaesthetic infiltration on the posterior side of the ear pavilion using 2% mepivacaine with adrenaline. A prophylactic antibiotic protocol is used, which includes a dose of cefazolin 30 min prior to surgery and a second dose 4–6 h after surgery.

Cutaneous excision is performed using a posterior approach, in a spindle shape. We form the antihelix fold by holding the pavilion with the fingers in an anterior position. Meanwhile, the posterior side should show the prominences formed by the cartilage located between the helix and the antihelix, as well as that between the antihelix and the concha, which should be sutured. In this way, we can easily determine the location of the points where the stitches are to be placed; this avoids the use of needles that pierce the cartilage and consequently avoids trauma to it (Fig. 2).

A sterile marker should be used to mark the 4 points through which the suture will pass to create a "U" suture. This should be done with non-absorbable material. In our series, we used Gore Tex® thread or nylon suture.

We start at the top of the pavilion, then descend and take 2 or 3 stitches as necessary.

The needle must pass through the width of the cartilage without penetrating to the anterior side. Once both prominences have been sutured, we gradually tighten it until the fold acquires the desired shape. Next, we suture downwards, adding 1 or 2 more as needed (Figs. 3–5).

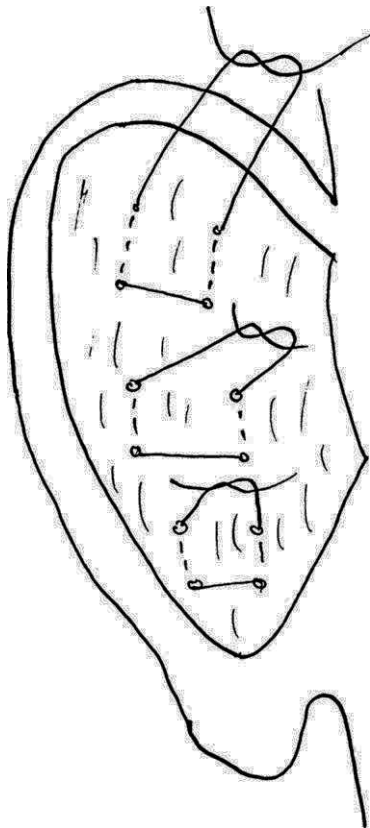


Figure 3 Schematic of cartilage suture to create the new fold.

The remaining skin is sutured and the usual dressing in this type of surgery is then applied.

The patient can be discharged the day after surgery, after a review of the surgical wound to rule out the presence of complications (mainly haematomas and chondritis).

The bandage should be removed 7 days after surgery. At this point, the patient should be advised to sleep with a rubber band holding both pavilions for 1 month.

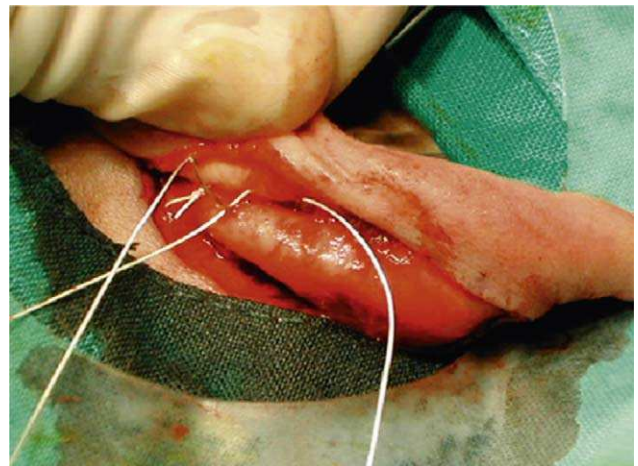


Figure 5 Otoplasty. Cartilage suture in "U" shape.

We took pictures of patients during the reviews, which took place 1 month and 9 months after surgery.

Results

We present 14 patients intervened at our hospital with this technique, between June 2003 and October 2008. In total, 3 patients were male and 11 female, with a mean age of 16.5 years (range, 6–35 years). All patients were operated on under general anaesthesia.

The result of the surgery was satisfactory in 12 of the 14 cases to date. One patient required a further operation due to recurrence of the deformity, caused by a release of the suture. In another patient, the suture protruded through the skin, so we proceeded to resect that stitch, with a satisfactory cosmetic result.

Figs. 6–9 show some examples of patients before and after surgery.

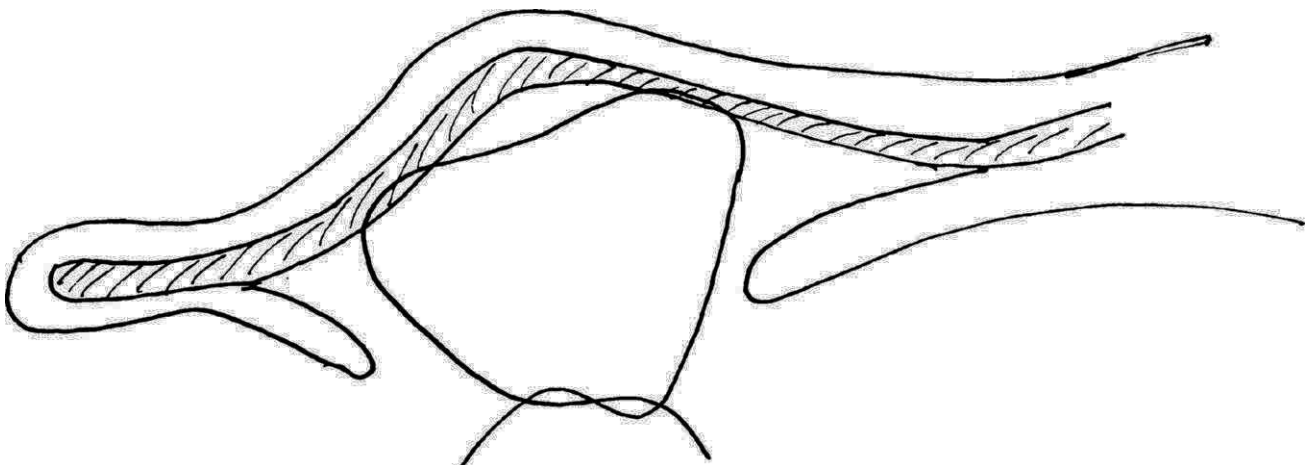


Figure 4 Schematic of cartilage suture to create the new fold.

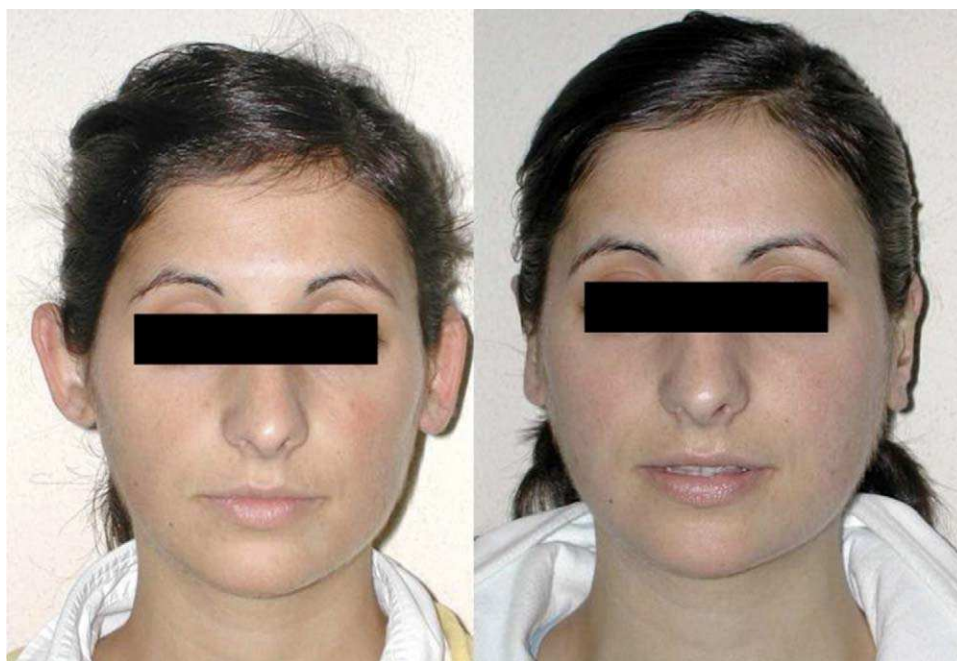

Figure 6 Case 1. Frontal view at 6 months after surgery.

Discussion

Surgical resolution of prominent or loop ears can be accomplished by numerous techniques. The majority are divided between those that carry out an invasive procedure on

the cartilage⁷ (scraping, section and repositioning) and those attempting to be more conservative to avoid most complications.⁸

Techniques such as that by Converse, which weakens the cartilage by abrasion through milling, or that by Chongchet,⁹

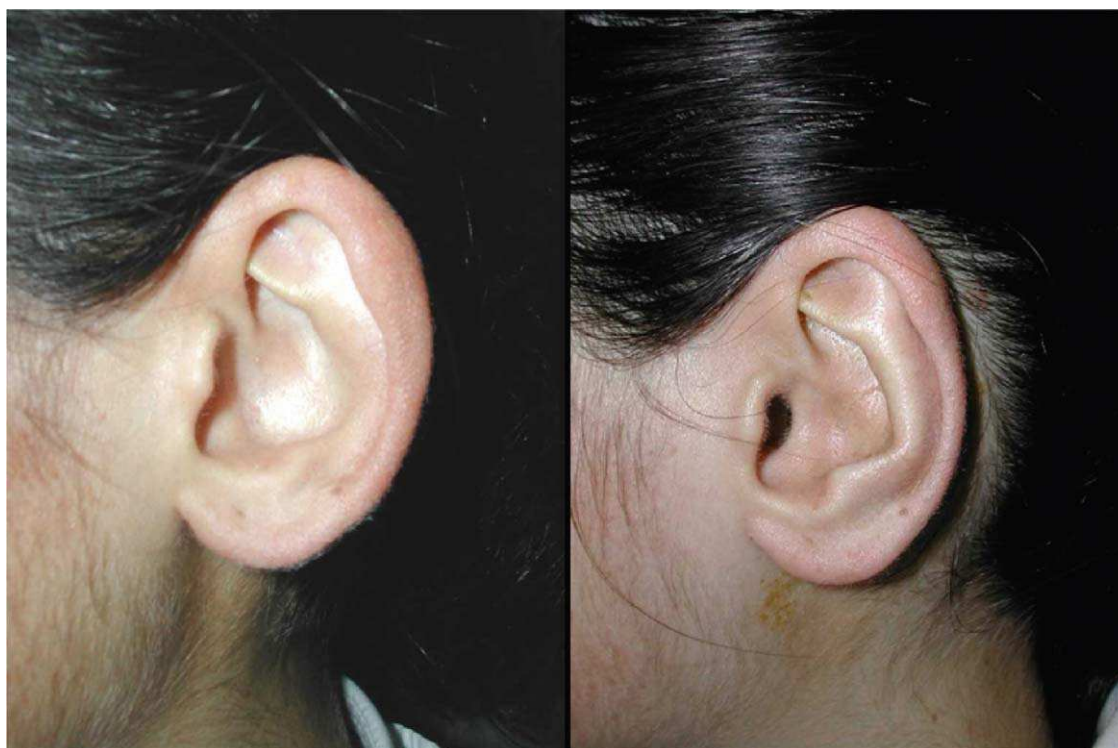

Figure 7 Case 1. Lateral view.

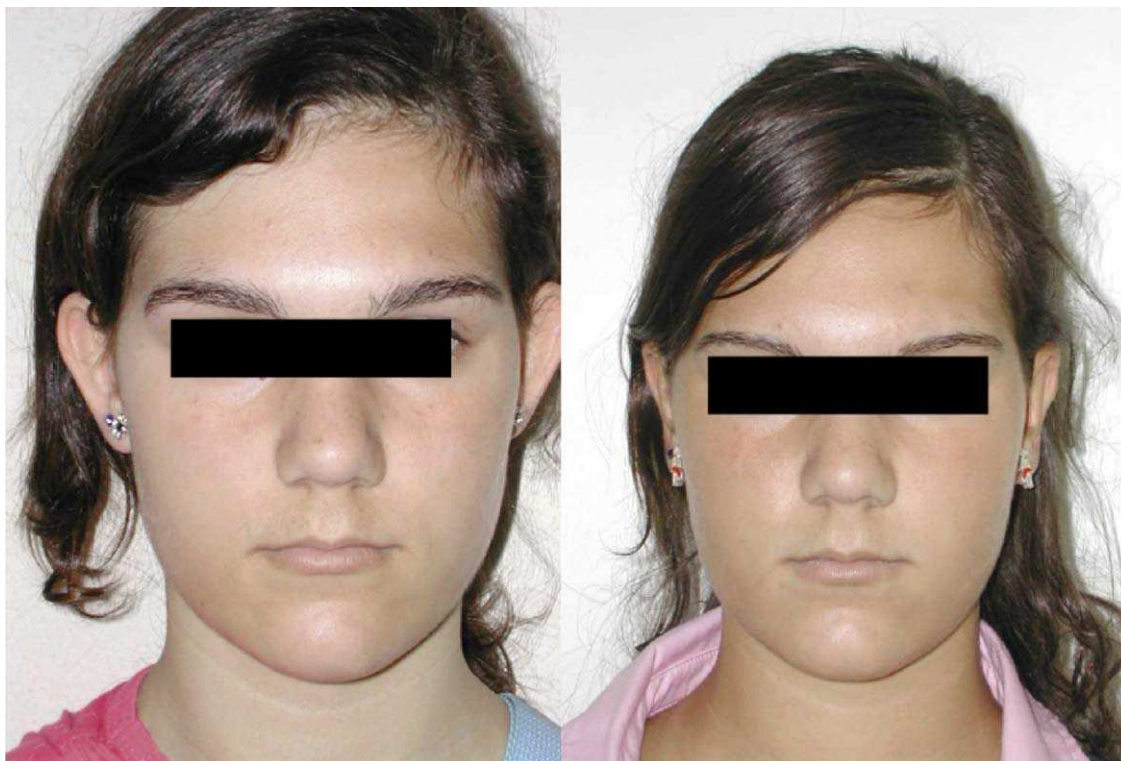

Figure 8 Case 2. Frontal view at 6 months after surgery.

which creates incisions in the cartilage to facilitate folding, or that by Pitanguy,¹⁰ with a cartilage island, are widely distributed and accepted.

Other more conservative techniques are derived from the technique devised by Mustardé, which creates a new antihe-

lix fold using non-absorbable suture material after piercing the cartilage with insulin needles to mark suture fold zones or using provisional transfixing stitches that give shape to the cartilage before carrying out the final suture. These procedures involve less traumatism for the cartilage.

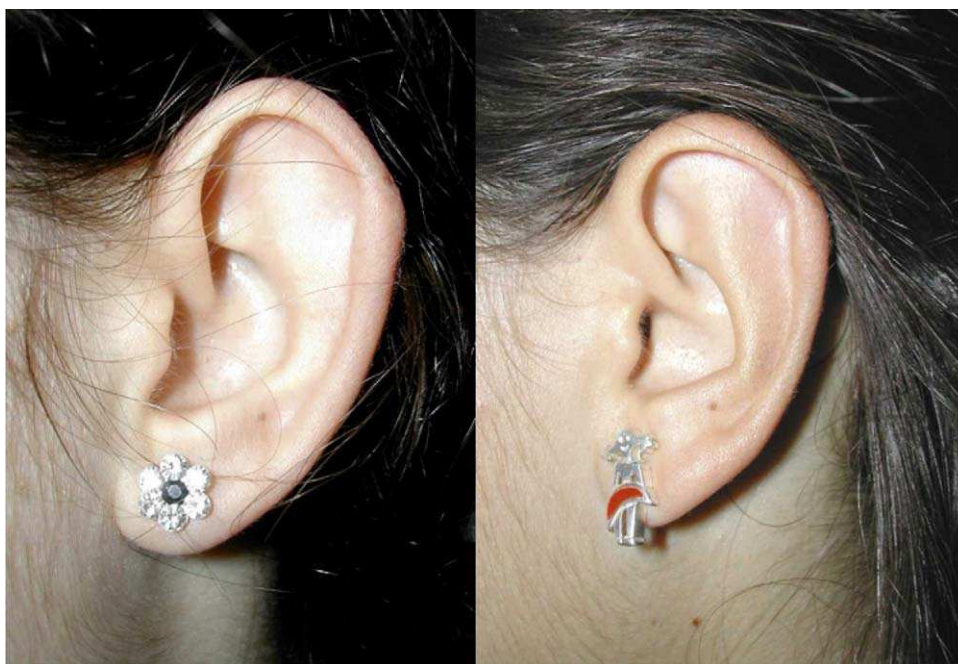

Figure 9 Case 2. Lateral view.

Both techniques have supporters and there are numerous studies that show the results with both techniques and that provide combinations and modifications thereof, obtaining acceptable results in most cases.

In our experience, the cartilaginous section involves more traumatism to the ear cartilage. In addition, the sectioned cartilage edge may be left marked on the anterior side of the pavilion, giving a worse cosmetic result.

The reason for using the Mustardé technique without using insulin needles to mark the stitches is based on an intention to avoid trauma to the cartilage as far as possible, to minimise complications and facilitate the location of the points where the suture must be placed to form the antihelix fold, while shortening the operating time. It is consequently not necessary to section or weaken or cross the cartilage previously, because cartilage suture is sufficient to obtain very acceptable results, as in our series.

Using a division method, Balogh¹¹ reported a recurrence rate of 3.95%. However, Mahler¹² reported a recurrence rate of 20% with a combined approach, and Tan¹³ compared both techniques and obtained a much lower recurrence rate using the technique of anterior striation.

Using the Mustardé technique in 127 patients, Aguilar et al.¹⁴ reported a recurrence rate of 4.72%. Colpaert and Missoten¹⁵ used a personal technique derived from a Chongchet modification and reported a recurrence rate of 0%.

Schlegel-Wagner et al.¹⁶ conducted a retrospective study of 420 patients who underwent otoplasty with a technique including anterior weakening of the cartilage combined with post-auricular fixation sutures. They found satisfactory, long-lasting results in 91% of cases, with a recurrence of the defect in 2.3% of cases and partial in 8.6%.

Schaverien et al.¹⁷ published the results of a study including 112 prominent ears intervened using posterior sutures and covered with post-auricular facial flap. The clinical recurrence was 4.5%.

Olivier et al.¹⁸ published a review of long-term results and complication rate of otoplasties performed in 104 patients with a cartilage-conserving technique (a modification of the Mustardé technique), which obtained a satisfaction rate of 95%, with a rate of early complications of 6% (bleeding, asymmetry). Late complications (9%) included extrusion of stitches as well as keloid and hypertrophic scarring. Only 3 cases of the total required a second operation.

Mandal et al. conducted a study comparing 3 otoplasty techniques (Group A, anterior cartilage weakening technique; Group B, cartilage-conserving technique; and Group C, cartilage sutures with posterior facial reinforcement technique) in 203 patients. They concluded that cartilage-conserving techniques with posterior facial reinforcement had the lowest number of complications, obtaining a better cosmetic result.¹⁹

Richards et al.²⁰ (in their published article "Otoplasty a review of surgical techniques") and Panettiére et al.²¹ (in their article titled "Otoplasty: a comparison of techniques for the treatment of antihelix defects") found no statistically-significant differences between the results of the techniques, although the latter noted that the tech-

niques aimed at preserving the cartilage produced a more natural and aesthetic curvature of the ear.

Conclusions

Numerous techniques have been described for the resolution of prominent ears and all have advantages and disadvantages. In our experience, minimising trauma to the cartilage structure leads to good cosmetic results and fewer complications.

Even without using insulin needles, we can locate the suture points, minimising trauma to the cartilage, reducing the number of complications and shortening the surgical time.

The theoretical drawback of the techniques that do not carry out cartilage sectioning is a higher percentage of recurrence of the deformity. The low percentage (7%) of recurrences in our series suggests that this technique is valid for the treatment of lack of antihelix fold.

Conflict of Interests

The authors have no conflicts of interest to declare.

References

1. Converse JM, Nigro A, Wilson JA, Johnson N. A technique for surgical correction of the loop ears. *Plast Reconstr Surg.* 1955;15:411-8.
2. Becker OJ. Surgical correction of the abnormally protruding ear. *Arch Otolaryngol.* 1949;50:541-60.
3. Mustardé JC. The correction of prominent ears using simple mattress sutures. *Br J Plast Surg.* 1963;16:170-6.
4. Stark H. Otoplastik mit dem CO₂ laser. *Laryngol Rhino-Otologie.* 1991;70:652.
5. Stenström S. A «natural» for correction of congenitally prominent ears. *Plast Reconstr Surg.* 1963;32:508-18.
6. Stenström S. The Stenström otoplasty. *Clin Plast Surg.* 1978;5:465-8.
7. Corzo A, Castañeda A, Grajeda P. Otoplastia directa: colgajo pericondrio-cutáneo. *Cir Plast.* 2000;10:16-25.
8. Schultz S, Christian M. Reconstrucción auricular. *Cuad Cir (Valdivia).* 2003;17:75-85.
9. Chongchet V. A method of antihelix reconstruction. *Br J Plast Surg.* 1963;16:268-72.
10. Pitanguy I. The treatment of prominent ears: a 25 year survey of the island technique. *Aesthetic Plast Surg.* 1987;11:87.
11. Balogh B. Are growth alterations a consequence of surgery for prominent ears? *Plast Reconstr Surg.* 1992;89:623.
12. Mahler D. The correction of the prominent ear. *Aesthetic Plast Surg.* 1986;10:29.
13. Tan KH. Long-term survey of prominent ear surgery, a comparison of two methods. *Br J Plast Surg.* 1986;39:270.
14. Aguilar R, Soto C, Barrena S, Diaz M, López J, Ros Z, et al. Estudio de la evolución de 238 otoplastias mediante encuesta de satisfacción. *Cir Pediatr.* 2008;21:104-6.
15. Colpaert S, Missoten F. Otoplasty for prominent ears: personal technique and review of 150 consecutive cases. *Eur J Plast Surg.* 2005;28:179-85.
16. Schlegel-Wagner C, Pabst G, Müller W, Linder T. Otoplasty using a modified anterior scoring technique: standardized measurements of long-term results. *Arch Facial Plast Surg.* 2010;12:143-8.

17. Schaverien MV, Al-Busaidi S, Stewart KJ. Long-term results of posterior suturing with postauricular fascial flap otoplasty. *J Plast Reconstr Aesthet Surg.* 2010;63:1447–51.
18. Olivier B, Mohammad H, Christian A, Akram R. Retrospective study of the long-term results of otoplasty using a modified Mustardé (cartilage-sparing) technique. *J Otolaryngol Head Neck Surg.* 2009;38:340–7.
19. Mandal A, Bahia H, Ahmad T, Stewart KJ. Comparison of cartilage scoring and cartilage sparing otoplasty. A study of 203 cases. *J Plast Reconstr Aesthet Surg.* 2006;59:1170–6.
20. Richards SD, Jebreel A, Capper R. Otoplasty: a review of the surgical techniques. *Clin Otolaryngol.* 2005;30:2–8.
21. Panettiè P, Marchetti L, Accorsi D, del Gaudio GA. Otoplasty: a comparison of techniques for antihelical defects treatment. *Aesthetic Plast Surg.* 2003;27:462–5.