

ORIGINAL ARTICLE

Otoplasty: Results After Anterior Versus Posterior Approach[☆]

Rosa Echarri San Martín*, Mónica Hernando Cuñado, José Montojo Woodeson, Guillermo Plaza Mayor

Servicio de Otorrinolaringología, Hospital de Fuenlabrada, Madrid, Spain

Received 9 August 2010; accepted 5 November 2010

KEYWORDS

Otoplasty;
Anterior approach;
Retroauricular
approach;
Suture extrusion

Abstract

Introduction and objective: In otoplasty, an anterior approach with sutures is commonly used, because it is not aggressive with cartilage. The aim of this study on otoplasty was to evaluate the usefulness of the anterior approach, comparing it to the results obtained after the posterior approach.

Material and methods: Retrospective study on 25 otoplasties performed at a University Hospital during the period 2004–2008. Clinical records from 13 patients (25 otoplasties), between 7 and 41 years of age, were reviewed. In the anterior approach, the anterior surface of the auricular cartilage is scratched with a rasp. The antihelix shape is obtained and mattress sutures are placed through the anterior surface of the ear.

Results: Out of 25 otoplasties, 92% were bilateral and 8%, unilateral; 54% of the patients were children and 46%, adults; anaesthesia was local in 20% and general in 80%. We performed 11 anterior and 14 posterior approach otoplasties. After an anterior approach, complications were suture extrusion in 82%, foreign body reaction in 9%, and revision surgery was needed in 28% of 11 otoplasties performed. After a posterior approach, complications were suture extrusion in 21%, foreign body reaction in 7%, and revision surgery was needed in 7% of 14 otoplasties performed. A good aesthetic result was obtained in almost all the cases (85%). Extrusion rate was statistically more common after the anterior approach.

Conclusions: In our opinion, otoplasty is a simple technique for treatment of prominent ears, with good aesthetic results. The most common complication is suture extrusion, more frequent after an anterior approach.

© 2010 Elsevier España, S.L. All rights reserved.

[☆] Please cite this article as: Echarri San Martín R, et al. Otoplastia: resultados del abordaje anterior frente al posterior. Acta Otorrinolaringol Esp. 2011;62:188–93.

* Corresponding author.

E-mail address: recharrri.hflr@salud.madrid.org (R. Echarri San Martín).

PALABRAS CLAVE

Otoplastia;
Abordaje anterior;
Abordaje posterior;
Extrusión

Otoplastia: resultados del abordaje anterior frente al posterior**Resumen**

Introducción y objetivo: En la otoplastia, el abordaje anterior combinado con suturas se utiliza cada día más, dado que es una técnica muy poco agresiva con el cartilago. El objetivo de este estudio es comprobar la utilidad del abordaje anterior, comparándola con el abordaje retroauricular.

Material y métodos: Estudio retrospectivo sobre 25 otoplastias intervenidas en el periodo 2004–2008. Se revisa la historia de 13 pacientes (25 otoplastias), con un rango de edad de 7 a 41 años. En el abordaje anterior, el cartilago auricular se adelgaza mediante limado y se modela el pliegue del antihélix mediante suturas.

Resultados: De las 25 otoplastias, el 92% fueron bilaterales, con un 54% de niños y un 46% adultos; la anestesia fue local en 20% y general en 80%. El abordaje fue anterior en el 44% y retroauricular en el 56%. Respecto a las complicaciones, en el abordaje anterior hubo extrusiones de puntos en 82%, reacción a cuerpo extraño en 9%, y fue necesaria una cirugía de revisión en el 28% de las 11 otoplastias operadas. En el abordaje posterior, hubo extrusiones de puntos en 21%, reacción a cuerpo extraño en 7%, ulceración de la piel en 7%, siendo necesaria la cirugía de revisión en 7% de las 14 orejas intervenidas. Globalmente, el 85% de los pacientes están satisfechos con el resultado estético de la cirugía. La extrusión de puntos fue estadísticamente más frecuente tras abordaje anterior.

Conclusiones: La otoplastia permite obtener buenos resultados estéticos para el tratamiento de las orejas en asa. La complicación más común es la extrusión de puntos de sutura, siendo más frecuente cuando el abordaje es anterior.

© 2010 Elsevier España, S.L. Todos los derechos reservados.

Introduction

Prominent ear (lop ear) is a common birth defect, occurring in 5% of the white population.¹ This malformation is inherited in an autosomal dominant pattern with variable penetrance.² In most patients, 2 deformities coexist, determining the greatest separation of the ears: an inadequate development of the antihelix fold and an overdevelopment of the concha.³

More than 200 surgical techniques have been described for its correction, indicating the lack of an ideal technique.⁴ These can be classified into 2 categories: with conservation of cartilage or with cartilage section. Section methods attempt to eliminate the inherent memory of the cartilage so that the shape of the ear can be modified. These techniques may leave significant asymmetries. In contrast, methods, which shape the cartilage are based on the Mustardé technique, which consists of placing 3 or 4 horizontal mattress sutures with permanent suture material along the ridge of the helix, to create an antihelix fold. These techniques have higher rates of relapse and require surgical revisions more frequently due to failure of correction, compared with section techniques.⁵

Moreover, it is still unclear which the best approach is. The posterior or retroauricular approach was described initially,^{1,4,5} but subsequently, anterior^{6–9} or combined approaches were recommended, or even those without any incision whatsoever.¹⁰

The aim of this study was to test the usefulness of the anterior approach, in comparison with the retroauricular approach, in a consecutive series of suture-based otoplasties, without cartilage section.

Material and Method

We present a retrospective series of all surgeries performed for prominent ears at our hospital during the time period between January 2004 and December 2008. In compliance with this criterion, we reviewed the medical records of 13 patients who underwent 25 otoplasties, with a minimum follow-up of 12 months.

Data were collected regarding patient age, gender, side operated, local or regional anaesthesia, and type of surgical approach (anterior versus posterior).

Regarding the surgical technique, the anterior approach begins with infiltration of lidocaine at 1%+epinephrine 1:100 000 on both sides of the auricular pavilion. An incision of 1–2 cm is made, following the ridge of the helix, to prevent it being seen later. Using a peeler, the skin is separated from the anterior cartilage and the area is then scraped with a file (Fig. 1) to remove the anterior perichondrium. Three hypodermic needles are passed through the anterior skin and cartilage to serve as a guide for the creation of the new antihelix. Small incisions are made in the skin in the entry and exit areas of the needles. Non-absorbable, ivory-coloured suture stitches (Lorca-Marin®, Supramid, ref 65343, white polyamide, Tb-15, 3/0), are passed through these incisions and back through the posterior auricular part to create the new antihelix fold (Fig. 1b). In case of prolapsed concha, one ellipse of skin and cartilage is removed in the area where the concha joins the antihelix, below the anti-tragus. This is completed with 4/0 silk suture of the incisions, which is removed after 7 days. Compression is done with cotton soaked in soap solution on the concha and antihelix–helix fold, covered with loose gauze and bandage for one week.

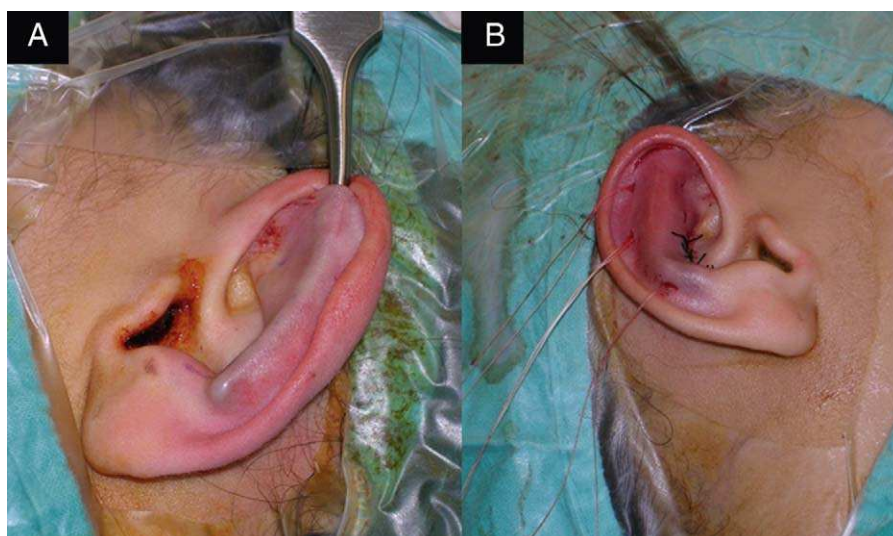


Fig. 1 Otoplasty by anterior approach. (A) Filing of the anterior perichondrium. (B) Non-absorbable, ivory-coloured stitches, through the incisions and passing through the posterior part of the auricular pavilion, to create the new antihelix fold.

Regarding the surgical technique, the posterior approach also begins with infiltration with lidocaine at 1%+adrenalin 1:100 000 on both sides of the auricular pavilion. A posterior skin incision is carried out in an elliptical shape, approximately 1 cm from the edge of the helix and the skin is resected to the level of the perichondrium (Fig. 2). Dissection is performed up to the proximity of the retroauricular sulcus, and in a cranial direction it should reach the proximity of the edge of the helix. Using the peeler, the skin is separated from the anterior cartilage and a file (Fig. 2b) is then used to remove the anterior perichondrium. If it is necessary to reduce the height of the concha, a half-moon of cartilage of approximately 6 mm is resected at the junction of the antihelix and the root. Hypodermic needles are placed through the anterior skin and cartilage to serve as a guide for the creation of a new antihelix. Subsequently, pulling the pavilion forward, successive incisions are made

along the lines marked by the needles, which ideally should not cut the anterior perichondrium, to prevent irregularities. Mattress sutures are applied, passing above and below the fold created through the anterior cartilage and perichondrium but not the skin, with 3 or 4 non-absorbable ivory-coloured suture stitches (identical to those used in the anterior approach). In adults with tough cartilage, before suturing it is necessary to detach the anterior skin and file the cartilage to facilitate the creation of the new fold. In patients with highly prolapsing conchas, a point of the concha has to be associated to the mastoid periosteum, to approximate the concha to it. Lastly, the retroauricular skin is sutured with 4/0 silk. Swabs soaked in soap are used to model the new auricular shape and dressing is maintained for 4–5 days.

Both the objective results (reduction of the prominent loop in preoperative and postoperative photographs)

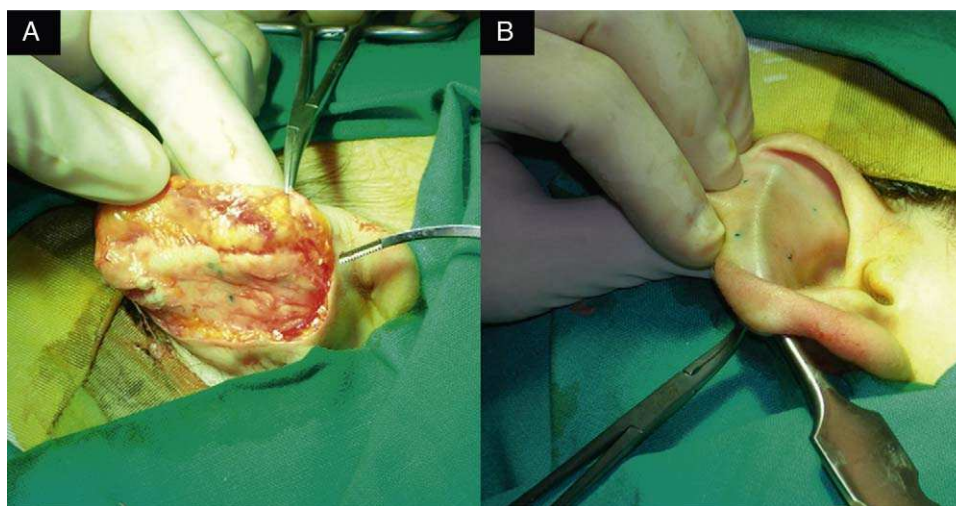


Fig. 2 Otoplasty by posterior approach. (A) Posterior, elliptical skin incision, resection of a strip of skin to the level of the perichondrium. (B) Filing from the retroauricular incision.

and subjective results (satisfaction survey at 6 months after surgery)¹¹ were evaluated, as was the presence of complications:

- Early (<15 postoperative days) bleeding or haematoma, infection or perichondritis, wound dehiscence, skin necrosis.
- Delayed (>15 postoperative days): extrusion of stitches and time of onset of extrusion, aberrant scarring and asymmetry.

Data collection and statistical analysis were performed using the statistical package SPSS 12.0. The magnitude of the statistical effect was calculated using the difference of medians for quantitative variables and the χ^2 for qualitative variables. We calculated the confidence interval for the result obtained, with a statistical significance level of $P < .05$.

Results

In the period between April 2004 and December 2008, we performed 25 otoplasties on 13 patients. Of these otoplasties, 12 (92%) were bilateral surgeries; of the 13 patients, 7 were children under 14 years of age (54%) and 6 were adults (46%). With regard to the 25 surgeries performed, 13 were on the right side (52%) and 12 on the left (48%).

As for anaesthesia, 5 adult otoplasties were performed under local anaesthesia (20%), and 20 otoplasties (including all those carried out in children) were performed under general anaesthesia. Regarding monitoring, there was one case lost after 3 months of surgery (posterior approach); in the remaining 23 otoplasties, the minimum follow-up period was 12 months, with a mean of 27 months and a median of 25 months.

As for the approach, we used the anterior approach in 11 otoplasties (44%), and the surgery was retroauricular in 14 cases (56%). In terms of complications, the anterior approach group (11 ears) showed the following complications: one case of foreign body reaction to the stitches associated with perichondritis, which evolved correctly after medical treatment; and extrusions of stitches in 9 operated ears (82%), of which 5 cases were observed during the control after the first month, 2 after 2–4 months, and 2 were observed belatedly, at 15 and 23 months, respectively. In 3 cases, this extrusion resulted in an asymmetry and revision surgeries were consequently carried out. These revisions were also conducted through an anterior approach under local anaesthesia.

In the posterior group (14 ears), we found the following complications: one case of foreign body reaction to the stitches, no cases of perichondritis, one case of ulceration of the skin (which evolved favourably with medical treatment and cures), and extrusions of the stitches in 3 operated ears (21%), which were evident at 3, 6 and 9 months, respectively. These extrusions prompted revision surgery due to asymmetry in one ear, which was performed using a posterior approach under general anaesthesia.

Extrusions of stitches were more frequent in the anterior approach (82%) than in the posterior (21%), with a statistically significant difference ($P < .05$).

In terms of subjective results (Fig. 3), 85% (11/13) of patients reported being satisfied with the cosmetic result of their surgery, one patient was not satisfied, but did not want to undergo a revision surgery and another patient was lost and there was no follow-up after one year).

From the objective point of view, of the 12 patients with preoperative and postoperative photographs after one year, all achieved a symmetrical reduction of prominent ears. However, to obtain this result, the anterior approach required revision surgery in 3 cases (28%), while the posterior approach required it only in one case (7%), with a statistically significant difference ($P < .05$).

Discussion

The prominent ear deformity is very common. There are studies that show that these anatomical changes cause psychological disorders in children and surgical correction is the therapy of choice.¹² The motivation of children requiring surgery arise from multiple factors, including bullying, aesthetic dissatisfaction and lack of self confidence.¹³ In our cases, the majority requested surgery for cosmetic reasons and due to harassment at school; in one case, the concern of parents was the cause, given the young age of the child.

The ideal age to consider the surgery is around 6 years, when the cartilage is fully developed. Moreover, in preschool age, children do not notice the deformity and do not suffer psychological trauma. However, this situation changes when the child begins to attend school.^{14,15}

The goal of surgery in the treatment of prominent ears is to obtain symmetrical and natural ears, with no signs of being operated.¹⁶ The variants of otoplasty can be classified into techniques which remodel the cartilage, as advocated by Mustardé,¹⁷ Furnas^{18,19} and Farrior and co-workers,²⁰ techniques which weaken it, as advocated by Stenstrom and Heftner,^{21,22} and techniques which section it, as advocated by Chongchet²³ and Conversen et al.²⁴ Some of these techniques also include the excision of an ellipse of retroauricular skin, and other fixation of the shell to the mastoid.

In any case, obtaining a good antihelix fold is crucial,²⁵ and this can be attempted with a multitude of surgical techniques such as horizontal sutures which fold the cartilage backwards, through the weakening of the anterior side of the cartilage by filing, by multiple incisions in the back of antihelix to make the cartilage more flexible, etc.

Our technique includes a combination of these techniques, through filing of the anterior side of the antihelix to obtain an antihelix fold which is harmonious and natural, as described by other authors.^{26,27} Moreover, in order to obtain stability it is necessary to position the internal, Mustardé-type sutures correctly.^{28,29} In our series, the cosmetic results and patient satisfaction were good when using these techniques.

Regarding the approach, both the anterior and the posterior allow filing to model the antihelix fold, without the need to make cuts in it. However, the use of sutures is linked to the most common complication in our series, which was extrusion of the stitches. This occurred primarily when using an anterior approach (4 times more frequently than in the posterior). It has been described by other authors in 10% of patients,³⁰ although it may be more frequent with some

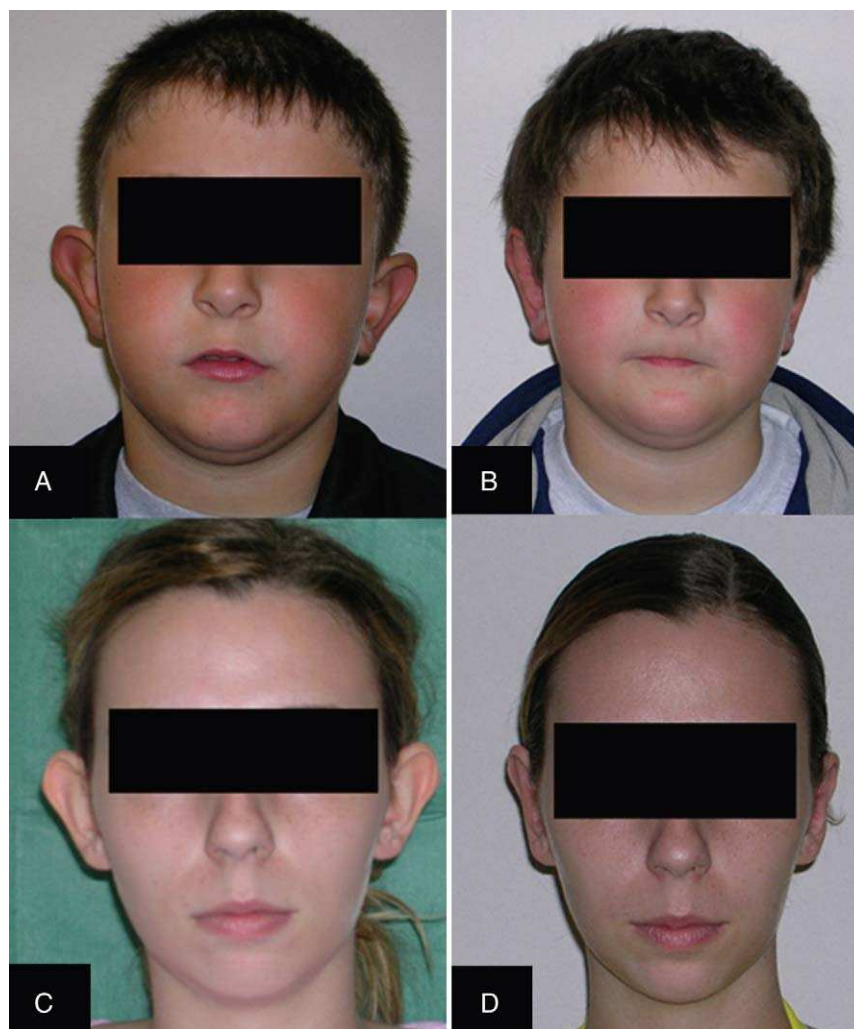

Fig. 3 Results after otoplasty. Anterior approach (A) preoperative image and (B) control at 12 months. Posterior approach (C) preoperative image and (D) control at 12 months.

sutures that with others.³¹ When suture extrusion appears, it is sometimes manifested as a continuous discharge at a particular point of the skin, before the suture is exposed. Its early detection is important to avoid the possibility of triggering chondritis and because the remedial effect of the stitches may disappear, favouring the recurrence of detachment of the operated ear. In fact, in our series, this was the main cause of secondary operations, which were also more frequent in the anterior approach than in the posterior (28% versus 7%).

The remaining complications described^{32–34} were less frequent; they did not represent major problems in our series. There may be infection of the skin, cartilage, or both. The importance of sequelae varies, with chondritis being one of the worst because it can make the pavilion disappear.³⁵ Treatment is carried out with broad spectrum antibiotics to cover *Staphylococcus* and *Pseudomonas*, along with drainage of any collections that may appear.

Another important complication is haematomas. It is very important to monitor the possible formation of haematomas in the immediate postoperative period. Early symptoms include skin tightness, pain and sensation of fullness.

Patients should learn to recognise this rare complication, which has been described in 2% of cases.^{36,37}

As for aesthetic results, there is sometimes relapse in which the pavilions become unstuck after being operated on, which takes place in 2%–13% of cases¹³ according to the series, depending on the technique.³⁸ In our series, we observed more relapses with the anterior approach, probably due to the increased extrusion of sutures.

Conclusions

Otoplasty allows for good cosmetic results in the treatment of protruding ears. The most common complication is the extrusion of stitches, being more frequent with the anterior approach.

Conflict of Interests

The authors have no conflicts of interest to declare.

References

- Mang WL. Otoplasty. In: Wang WL, editor. *Manual of aesthetic surgery* (vol. 1): rhinoplasty, rhytidectomy, lid surgery, otoplasty, adjuvant therapies including laser surgery. Heidelberg: Georg Thieme Verlag; 2002. p. 191–223.
- Werdaa H. Classification and surgery of auricular defects. In: Werdaa H, editor. *Surgery of the auricle*. Stuttgart: Georg Thieme Verlag; 2007. p. 43–233.
- Tomas M, Til G. Orejas en asa. In: Tomas Barberan M, Bernal Sprekelsen M, editors. *Tratado de Otorrinolaringología pediátrica*. Ponencia Oficial del Congreso Nacional de la SEORL. 2000. p. 151–6.
- Adamson PA, Litner JA. Otoplasty technique. *Otolaryngol Clin North Am*. 2007;40:305–18.
- Mandal A, Bahia H, Ahmad T, Stewart KJ. Comparison of cartilage scoring and cartilage sparing otoplasty – a study of 203 cases. *J Plast Reconstr Aesthet Surg*. 2006;59:1170–6.
- Bassot DJ. The anterior approach to otoplasty. *Plast Reconstr Surg*. 2001;108:1823.
- Burres S. The anterior–posterior otoplasty. *Arch Otolaryngol Head Neck Surg*. 1998;124:181–5.
- Zambudio G, Ruiz JI, Guirao MJ, Sánchez JM, Girón O, Gutiérrez MA. Otoplastia por vía anterior para el tratamiento de las orejas prominentes. Una técnica mínimamente invasiva. *Cir Pediatr*. 2007;20:119–21.
- Erol OO. New modification in otoplasty: anterior approach. *Plast Reconstr Surg*. 2001;107:193–203.
- Fritsch MH. Incisionless otoplasty. *Otolaryngol Clin North Am*. 2009;42:1199–208.
- Aguilar R, Soto C, Barrena S, Díaz M, López JC, Ros Z, et al. Estudio de la evolución de 238 otoplastias mediante encuesta de satisfacción. *Cir Pediatr*. 2008;21:104–6.
- Lourenço Gasques JA, Pereira de Godoy JM, Navarro Cruz EMT. Psychosocial effects of otoplasty in children with prominent ears. *Aesthet Plast Surg*. 2008;32:910–4.
- Cooper-Hobson G, Jaffe W. The benefits of otoplasty for children: further evidence to satisfy the modern NHS. *J Plast Reconstr Aesthet Surg*. 2009;62:190–4.
- Spielmann PM, Harpur RH, Stewart KJ. Timing of otoplasty in children: what age? *Eur Arch Otorhinolaryngol*. 2009;266:941–2.
- Gasques JA, Pereira de Godoy JM, Cruz EM. Psychosocial effects of otoplasty in children with prominent ears. *Aesthetic Plast Surg*. 2008;32:910–4.
- Petersson RS, Friedman O. Current trends in otoplasty. *Curr Opin Otolaryngol Head Neck Surg*. 2008;16:352–8.
- Mustarde JC. The correction of prominent ears using simple mattress sutures. *Br J Plast Surg*. 1963;16:170–6.
- Furnas DW. Correction of prominent ears by concha-mastoid sutures. *Plast Reconstr Surg*. 1968;42:189–93.
- Janz BA, Cole P, Hollier Jr LH, Stal S. Treatment of prominent and constricted ear anomalies. *Plast Reconstr Surg*. 2009;124:e27–37.
- Scharer SA, Farrior EH, Farrior RT. Retrospective analysis of the Farrior technique for otoplasty. *Arch Facial Plast Surg*. 2007;9:167–73.
- Stenstrom SJ. A natural technique for correction of congenitally prominent ears. *Plast Reconstr Surg*. 1963;32:509–18.
- Stenstrom SJ, Heftner J. The Stenstrom otoplasty. *Clin Plast Surg*. 1978;5:465–70.
- Chongchet V. A method of antihelix reconstruction. *Br J Plast Surg*. 1963;16:268–72.
- Conversen JM, Nigro A, Wilson FA, Johnson N. A technique for surgical correction of lop ears. *Plast Reconstr Surg*. 1955;15:411–8.
- Becker DG, Lai SS, Wise JB, Steiger JD. Analysis in otoplasty. *Facial Plast Surg Clin North Am*. 2006;14:63–71.
- Salgarello M, Gasperoni C, Montagnese A, Farallo E. Otoplasty for prominent ears: a versatile combined technique to master the shape of the ear. *Otolaryngol Head Neck Surg*. 2007;137:224–7.
- Nolst Trenité GJ. Otoplasty: a modified anterior scoring technique. *Facial Plast Surg*. 2004;20:277–85.
- Olivier B, Mohammad H, Christian A, Akram R. Retrospective study of the long-term results of otoplasty using a modified Mustardé (cartilage-sparing) technique. *J Otolaryngol Head Neck Surg*. 2009;38:340–7.
- Yugueros P, Friedland JA. Otoplasty: the experience of 100 consecutive patients. *Plast Reconstr Surg*. 2001;108:1045–53.
- Tomas Barberán M. Complicaciones en la otoplastia. In: Bernal Sprekelsen M, et al., editors. *Riesgos y complicaciones en la cirugía ORL y de cabeza y cuello: prevención y tratamiento*. Tarragona: Ponencia Oficial del Congreso Nacional de la SEORL; 2008. p. 237–44.
- Maslauskas K, Astrauskas T, Viksraitis S, Samsanavidius D. Comparison of otoplasty outcomes using different types of suture materials. *Int Surg*. 2010;95:88–93.
- Limandjaja GC, Breugem CC, Mink van der Molen AB, Kon M. Complications of otoplasty: a literature review. *J Plast Reconstr Aesthet Surg*. 2009;62:19–27.
- Owsley TG, Biggerstaff TG. Otoplasty complications. *Oral Maxillofac Surg Clin North Am*. 2009;21:105–18.
- Bermúdez Polonio R. Acerca de ciertos fracasos estéticos menores en las otoplastias de las orejas en asa. *An Otorrinolaringol Ibero Am*. 1982;9:5–40.
- Firmin F, Sanger C, O'Toole G. Ear reconstruction following severe complications of otoplasty. *J Plast Reconstr Aesthet Surg*. 2008;61:513–20.
- Caouette-Laberge L, Guay N, Bortoluzzi P, Belleville C. Otoplasty: anterior scoring technique and results in 500 cases. *Plast Reconstr Surg*. 2000;105:504–15.
- Messner AH, Crysdale WS. Otoplasty: clinical protocol and long-term results. *Arch Otolaryngol Head Neck Surg*. 1996;122:773–7.
- Schlegel-Wagner C, Pabst G, Müller W, Linder T. Otoplasty using a modified anterior scoring technique: standardized measurements of long-term results. *Arch Facial Plast Surg*. 2010;12:143–8.