

EXIT Procedure in the Management of Severe Foetal Airway Obstruction. The Paediatric Otolaryngologist's Perspective

Marc Pellicer,^a Félix Pumarola,^a José Luis Peiró,^b Vicente Martínez Ibáñez,^b Juan Antonio García Vaquero,^b Elena Carreras,^c Susana Manrique,^d Joan Vinzo,^e and Enrique Perelló^f

^aSección de Otorrinolaringología Pediátrica, Hospital Universitario Vall d'Hebron, Barcelona, Spain

^bServicio de Cirugía Pediátrica, Hospital Universitario Vall d'Hebron, Barcelona, Spain

^cServicio de Obstetricia, Hospital Universitario Vall d'Hebron, Barcelona, Spain

^dServicio de Anestesiología, Hospital Universitario Vall d'Hebron, Barcelona, Spain

^eServicio de Neonatología, Hospital Universitario Vall d'Hebron, Barcelona, Spain

^fServicio de Otorrinolaringología, Hospital Universitario Vall d'Hebron, Barcelona, Spain

The ex-utero intrapartum treatment (EXIT) procedure is a technique designed to allow partial foetal delivery via caesarean section with establishment of a safe foetal airway by either intubation, bronchoscopy, or tracheostomy while foetal oxygenation is maintained through utero-placental circulation. The most common indication for the EXIT procedure is the presence of foetal airway obstruction, which is usually caused by a prenatal diagnosed neck mass. We report 3 cases of head and neck tumours with airway obstruction treated by means of EXIT and with different solutions in the management of the airway. With the involvement of Paediatric Otolaryngologists in EXIT, new indications and select variations from the standard EXIT protocol should be considered.

Key words: Ex-utero intrapartum treatment (EXIT). Cervical teratoma. Epignathus. Cervical lymphangioma. Foetal surgery.

Procedimiento EXIT en el manejo de fetos con severo compromiso respiratorio. La perspectiva del otorrinolaringólogo pediátrico

El ex-utero intrapartum treatment (EXIT) es una técnica diseñada para permitir un parto fetal parcial a través de una cesárea y el establecimiento de una vía aérea fetal segura a través de intubación, broncoscopia o traqueotomía mientras la oxigenación fetal se mantiene a través de la circulación uteroplacentaria. La indicación más frecuente de EXIT es la obstrucción de la vía aérea fetal, habitualmente causada por una masa cervical diagnosticada prenatalmente. Presentamos 3 casos de tumoraciones de cabeza y cuello con compromiso de la vía aérea tratados mediante EXIT y con diferentes soluciones en el manejo de la vía aérea. Con la implicación de los otorrinolaringólogos pediátricos en el EXIT, aparecerán nuevas indicaciones y podrán valorarse variaciones del protocolo básico.

Palabras clave: Tratamiento ex utero intrapartum (EXIT). Teratoma cervical. Epignatus. Linfangioma cervical. Cirugía fetal.

CASE 1

This is an oronasopharyngeal teratoma or epignathus with a prenatal diagnosis at 18 weeks gestation, with considerable polyhydramnios, during the patient's second

pregnancy. In trying to prevent airway intubation problems that may be potentially lethal, an EXIT procedure was scheduled at 35 weeks gestation. During the EXIT procedure a caesarean section with partial exposure of the foetus was performed. Given the impossibility of performing intubation or bronchoscopy, a tracheostomy was done while foetal oxygenation was maintained through utero-placental circulation (total time was 7 minutes). Complications arose in management of the mother due to early detachment of the placenta (abruptio placentae). The newborn was then taken to the neonatal intensive care unit. Four days later tumour exeresis (epignathus) and closure of the tracheostomy were performed together with post-operative elective intubation during a 24-hour period. The next day extubation and direct laryngotracheoscopy were performed. The patient

The authors have not indicated any conflict of interest.

Correspondence: Dr. M. Pellicer.
Sección de Otorrinolaringología Pediátrica. Hospital Universitari Vall d'Hebron.

Pg. Vall d'Hebron, 119-129. 08035 Barcelona. España.
E-mail: mpellicer@vhebron.net

Received July 27, 2006.

Accepted for publication November 7, 2006.

Figure 1.
Tracheostomy during
the EXIT procedure on
a patient with
epignathus.

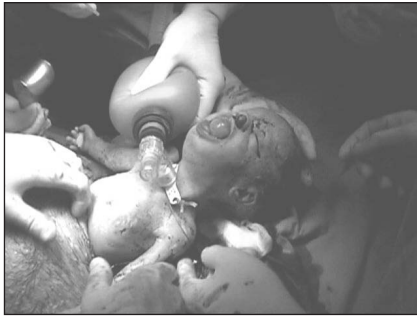

Figure 2. Intubation
following
decompression of the
larynx and trachea by
cervical excision
surgery.

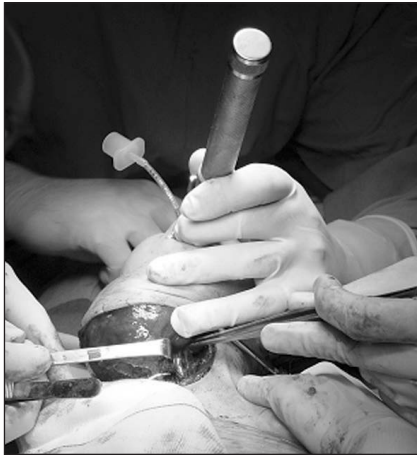
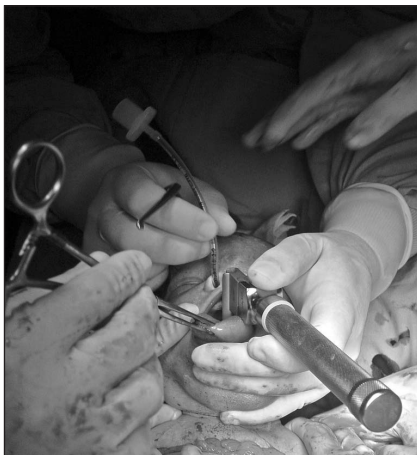
Figure 3. Orotracheal
intubation on the first
attempt.



was released from the hospital 20 days after the EXIT procedure and follow-up has continued for 24 months, with no airway problems present (Figure 1).

CASE 2

A male foetus of a pregnant 30-year-old woman was diagnosed with a cervical tumour at 18 weeks gestation, detected during a routine ultrasound scan. The subsequent foetal MRI scan showed that the tumour was compatible

with a cervical teratoma. During the EXIT procedure, intubation was impossible due to the large degree of laryngotracheal distortion produced by the tumour; tracheostomy was also impossible due to the presence of the tumour at the mid-cervical level. Therefore, it was decided to perform a cervical excision of the tumour to decompress the larynx and trachea, while the patient remained with utero-placental circulation and then orotracheal intubation.

Once the patient was ventilated through the endotracheal tube and the umbilical cord was cut, excision and complete exeresis of the tumour were performed separately, while the obstetric team continued taking care of the mother. The patient was released 7 days later and follow-up during 6 months has not shown any problems (Figure 2).

CASE 3

A male foetus was diagnosed with an oropharyngeal and cervical tumour after his 27-year-old mother had a routine ultrasound scan at 32 weeks gestation. The cystic and multilobulated nature of the mass indicated a lymphatic malformation. Given the size of the mass, its oropharyngeal component and the tracheal compression it produced, an EXIT procedure was scheduled. The obstetric team performed the caesarean section and partial exposure of the foetus where a large, depressible glossocervical mass was seen. Orotracheal intubation was successful on the first attempt and the patient was taken to the neonatal intensive care unit. The next day, a standard tracheostomy was performed in order to manage the patient and avoid accidental extubation. The patient has undergone aspiration treatment of the cysts along with OK432 injections, as well as radiofrequency. Two months following the EXIT procedure, however, it is still not possible to remove the cannula (Figure 3).

DISCUSSION

In this series of cases, 3 different types of airway management are shown in 3 separate cases of head and neck tumours compromising the airway.

Naturally, EXIT procedures are a multidisciplinary approach (within a true foetal surgery programme)^{1,2} requiring meticulous pre-operative planning that involves the departments of neonatology, obstetrics, paediatric surgery, paediatric radiology, paediatric and maternal anaesthesia, and maxillofacial surgery. Each team member has a specific role during the procedure.

The paediatric otorhinolaryngologist has to establish an airway, preferably while the foetus is still on placental circulation. The algorithm established for the procedure is shown in Figure 4, which will probably be adapted as more experience is acquired.

EXIT procedure indications have greatly increased. Initially, an EXIT procedure was planned in order to extract endotracheal plugs placed in the foetal trachea by obstetricians

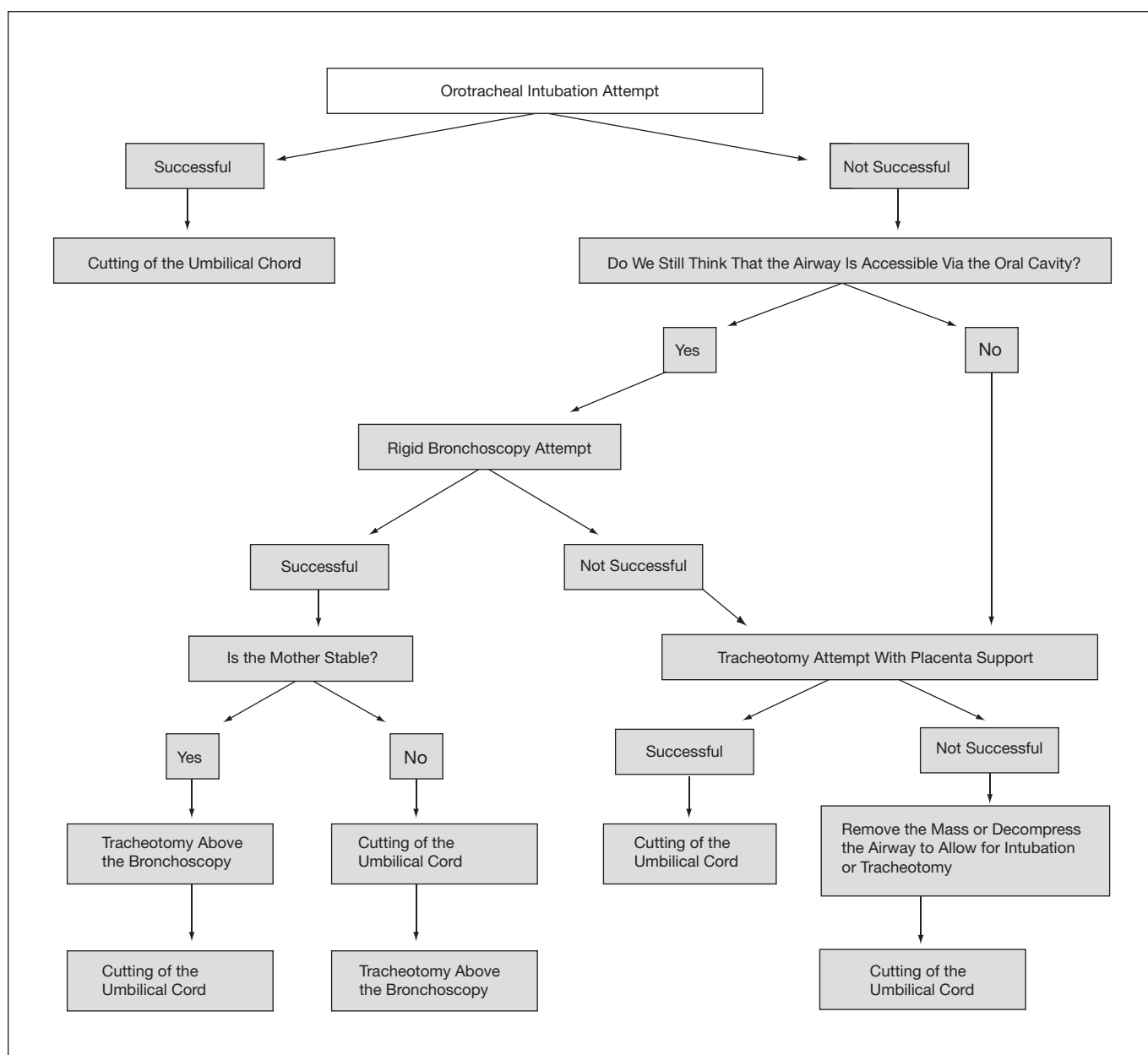


Figure 4. Algorithm of the decision making process.

or paediatric surgeons to treat a foetus's congenital diaphragmatic hernias.³ Little by little, EXIT procedure indications have shifted to include head and neck tumours with airway obstruction and CHAOS (congenital high airway obstruction syndrome, associated with forms of laryngeal atresia)^{4,5} or forms of severe mandibular hypoplasia.⁶ Therefore, paediatric otorhinolaryngologists, with their vast general experience regarding the airways, are expected to be called on more and more often by their obstetric colleagues. This trend may explain the increase in EXIT procedures found in otorhinolaryngology literature.^{7,8} We believe the involvement of paediatric otorhinolaryngologists in this technique will lead to it being indicated in more cases.

Paediatric otorhinolaryngologists must be consulted and they should know the basic lines of action so that variations may be considered whenever unusual situations arise or immediate action is required, all the while maintaining thorough pre-operative planning even in the most difficult cases.

REFERENCES

1. Bouchard S, Johnson MP, Flake AW, et al. The EXIT procedure: experience and outcome in 31 cases. *J Pediatr Surg.* 2002;37:418-26.
2. Mycaliska GB, Bealer JF, Graf JL, Rosen MA, Adzick NS, Harrison MR. Operating on placental support: The ex-utero intrapartum treatment procedure. *J Pediatr Surg.* 1997;32:227-30.

3. Harrison MR, Adzick NS, Flake AW, et al. Correction of congenital diaphragmatic hernia in utero VIII: response of the hypoplastic lung to tracheal occlusion. *J Pediatr Surg.* 1996;31:1339-48.
4. Bui TH, Grunewald C, Frenckner B, et al. Successful EXIT (ex utero intrapartum treatment) procedure in a fetus diagnosed prenatally with congenital high airway obstruction syndrome due to laryngeal atresia. *Eur J Pediatr Surg.* 2000;10:328-33.
5. de Cou JM, Jones DC, Jacobs HD, Touloukian RJ. Successful ex utero intrapartum treatment (EXIT) procedure for congenital high airway obstruction syndrome (CHAOS) owing to laryngeal atresia. *J Pediatr Surg.* 1998;33:1563-5.
6. Otteson TD, Hackam DJ, Mandell DL. The ex utero intrapartum treatment (EXIT) procedure: New challenges. *Arch Otolaryngol Head Neck Surg.* 2006;132:686-9.
7. Rahbar R, Vogel A, Myers LB, et al. Fetal surgery in otolaryngology: a new era in the diagnosis and management of fetal airway obstruction because of advances in prenatal imaging. *Arch Otolaryngol Head Neck Surg.* 2005;131:393-8.
8. Preciado DA, Rutter MJ, Greenberg JM, Bahado-Singh R, Lambers D, Willing JP. Intrapartum management of severe fetal airway obstruction. *J Otolaryngol* 2004;33:283-8.