

SCIENTIFIC LETTER

Subacute thyroiditis metamorphosing into Graves' disease



Tiroiditis subaguda metamorfoseada en enfermedad de Graves

Dear Editor

A 79-year-old female presented to her primary care physician with sore throat and anterior neck tenderness for 4 weeks. The patient had a history of chronic obstructive pulmonary disease but had no personal or family history of thyroid disease. Her vital signs were normal, oropharynx was mildly erythematous, and thyroid was not enlarged but was tender, without palpable nodules or lymphadenopathy. The remainder of the physical examination was unremarkable. Her complete blood count, electrolytes, and renal and hepatic functions were normal. TSH levels were $0.68 \mu\text{IU/mL}$ (normal $0.5\text{--}6.0$) and free T4 1.32 ng/dL (normal $0.75\text{--}1.85$) (Fig. 1) and test for throat streptococcal infection was negative. The patient was tentatively diagnosed as having viral pharyngitis and given a non-steroidal anti-inflammatory drug for pain relief. Her symptoms persisted and she went to an urgent care clinic where repeat test for throat streptococcal infection was again negative and she was given a nine-day corticosteroid taper for presumed viral pharyngitis with significant relief of her symptoms. Once corticosteroids were tapered off, her symptoms recurred.

The patient returned to the primary care physician one month after the first visit with a persistent sore throat. The throat pain radiated to her head bilaterally and was associated with shortness of breath and a mild nonproductive cough. The patient was afebrile. Thyroid examination findings remained unchanged from those at the prior visit. Two weeks later she developed anterior neck swelling. Her pulse rate was 103, and her thyroid was enlarged and diffusely tender. Her erythrocyte sedimentation rate was 77 (Fig. 1). Thyroid functions at that time were not measured. The patient was diagnosed with subacute thyroiditis and was started on prednisone 40 mg daily with dose taper. Within 1 week, patient reported improvement in her symptoms with decreased throat and neck pain and decreased thyroid tenderness. Three weeks later, she was seen in her primary care office with a heart rate of 69 and unremarkable physical findings. TSH levels were $<0.03 \mu\text{IU/mL}$ and free T4

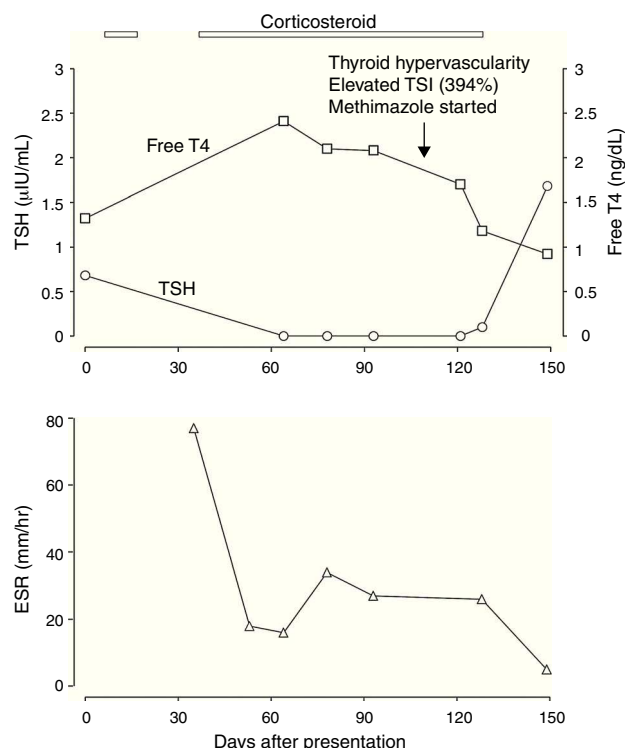


Figure 1 The patient's clinical course and laboratory values. Day 0 indicates initial day of presentation to primary care doctor. Bars indicate duration of corticosteroid treatment. TSI, thyroid-stimulating immunoglobulin; TSH, thyroid stimulating hormone; T4, thyroxine; and ESR, erythrocyte sedimentation rate.

2.41 ng/dL (Fig. 1). TSH was serially measured over the next several weeks and its levels remained suppressed. Thyroid peroxidase antibody levels were 677 units (normal 0–100) and thyroglobulin antibody normal. Due to the persistent hyperthyroidism, patient was referred to an endocrinologist.

At the endocrinologist's office, the patient reported recurrence of some of her symptoms, including malaise with worsened shortness of breath, with gradual tapering of prednisone. Thyroid examination revealed a mildly tender goiter. Ultrasound examination of the thyroid demonstrated hypervascularity consistent with Grave's disease. Thyroid stimulating immunoglobulin (TSI) levels were 394% (normal $<140\%$). Patient was given methimazole 30 mg daily and within 6 weeks patient's condition improved considerably.

TSH levels were normalized to 1.68 μ IU/mL and free T4 to 0.92 ng/dL (Fig. 1).

We have reported here a very rare case of subacute thyroiditis transforming into Graves' disease in an elderly female. Subacute thyroiditis (SAT) is a self-limiting inflammation of the thyroid, presumably of viral etiology, and characterized by a painful goiter and an elevation of systemic inflammatory markers.¹ The clinical course is characterized by an inflammatory phase with leakage of follicular contents resulting in an early hyperthyroid state usually lasting 2–8 weeks, followed by thyroidal depletion and a subsequent hypothyroid state, with eventual recovery. Complete recovery is the norm. The diagnosis of subacute thyroiditis is clinically based and our patient's typical symptoms, elevated erythrocyte sedimentation rate, and response to systemic corticosteroid make a convincing diagnosis of subacute thyroiditis. Interestingly, thyroid function tests performed on initial presentation were normal, which could be seen in some patients.¹ Rather than transitioning into a hypothyroid phase, the patient had persistent hyperthyroidism at 15 weeks after presentation, despite corticosteroid treatment, suggesting other causes of hyperthyroidism. The high titers of TSI and thyroid hyper-vascularity confirmed Graves' disease. It is important to diagnose Graves' disease in a timely manner because treatment of Graves' disease is very effective but different from that for subacute thyroiditis, as shown in this case. Although we cannot exactly pinpoint the transition from subacute thyroiditis to Graves' disease, it probably occurred at 2 months after initial presentation, considering that the hyperthyroid phase of subacute thyroiditis usually lasts 2–8 weeks. The patient's poor response to corticosteroid also suggests a different pathophysiology from that of subacute thyroiditis which usually responds to corticosteroid very promptly.¹ In Graves' disease, although corticosteroids inhibit T4 to T3 conversion, they usually do not change T4 and TSH levels.² Thus prolonged requirement of corticosteroids in a patient presenting with subacute thyroiditis should also raise the

suspicion of Graves' disease. The mechanism for Graves' disease following subacute thyroiditis is usually postulated as that the destructive process and release of autoantigens in subacute thyroiditis can trigger autoimmune disease, such as Graves' disease, in genetically predisposed individuals.^{3,4} As Graves' disease is much less common in elderly patient,⁵ the Graves' disease immediately following her subacute thyroiditis in this 79-year-old patient may be indeed triggered by the latter.

Conflict of interest

The authors have no conflict of interest to disclose.

References

1. Nishihara E, Ohye H, Amino N, Takata K, Arishima T, Kudo T, et al. Clinical characteristics of 852 patients with subacute thyroiditis before treatment. *Intern Med.* 2008;47:725–9.
2. Gamstedt A, Kågedal B, Tegler L. Serum free thyroid hormones are decreased by betamethasone treatment in Graves' disease. *Horm Metab Res.* 1988;20:54–6.
3. Nakano Y, Kurihara H, Sasaki J. Graves' disease following subacute thyroiditis. *Tohoku J Exp Med.* 2011;225:301–9.
4. Hoang TD, Mai VQ, Clyde PW, Shakir MK. Simultaneous occurrence of subacute thyroiditis and Graves' disease. *Thyroid.* 2011;21:1397–400.
5. Aizawa T, Yamada T. Hyperthyroidism due to Graves' disease in aged patients. *Trends Endocrinol Metab.* 1991;2:4–8.

Adrienne Dow, Paul Azer, Run Yu*

Cedars-Sinai Medical Center, 8700 Beverly Boulevard, Los Angeles, CA 90048, USA

*Corresponding author.

E-mail address: run.yu@cshs.org (R. Yu).

17 March 2013 26 July 2013 31 July 2013