

SPECIAL ARTICLE

A case of systemic pseudohypoaldosteronism with a novel mutation in the SCNN1A gene

Nicole Silva^{a,*}, Miguel Costa^a, Albina Silva^a, Carla Sá^a, Sofia Martins^b, Ana Antunes^b, Olinda Marques^b, Sérgio Castedo^c, Almerinda Pereira^a

^a Neonatal Intensive Care Department, Hospital Braga, Braga, Portugal

^b Pediatric Department, Division of Pediatric Endocrinology, Hospital Braga, Braga, Portugal

^c GDPN, Genética Médica e Diagnóstico Pré – Natal, Prof. Doutor Sérgio Castedo, Porto, Portugal

Received 22 April 2012; accepted 8 July 2012

KEYWORDS

Pseudohypoaldosteronism type 1;
Hyperkalemia;
Hyponatremia;
Metabolic acidosis;
SCNN1A gene

PALABRAS CLAVE

Pseudohipoaldosteronismo sistémico tipo 1;
Hiperpotasemia;
Hiponatremia;
Acidosis metabólica;
Gen SCNN1A

Abstract We report a neonatal case of systemic pseudohypoaldosteronism type 1 caused by a novel mutation in the SCNN1A gene (homozygous c.1052+2dupT in intron 3) in which the patient presented with life-threatening hyperkalemia, hyponatremia and metabolic acidosis. It remains uncertain if there is genotype-phenotype correlation, due to the rarity of the disease. This mutation, which to our best knowledge has not been described before, was associated with a very severe phenotype requiring aggressive therapy.

© 2012 SEEN. Published by Elsevier España, S.L. All rights reserved.

Un caso de pseudohipoaldosteronismo sistémico con una mutación nueva en el gen SCNN1A

Resumen Se presenta un caso neonatal de pseudohipoaldosteronismo sistémico tipo 1 causado por una nueva mutación en el gen SCNN1A (homocigotos C.1052 2 dupT en el intrón 3) en el que el se evidenció hiperpotasemia potencialmente mortal, hiponatremia y acidosis metabólica. Continúa sin saberse con certeza si hay correlación genotipo-fenotipo, debido a la rareza de la enfermedad. Esta mutación, que no ha sido previamente descrita, se asoció con un fenotipo muy grave por lo que requirió un abordaje terapéutico agresivo.

© 2012 SEEN. Publicado por Elsevier España, S.L. Todos los derechos reservados.

Introduction

Hyponatremia and hyperkalemia can represent a variety of renal and genetic disorders with significant long-term health implications.²

Pseudohypoaldosteronism type 1 (PHA 1) is a rare genetic aldosterone unresponsiveness syndrome.⁵ The diagnosis is

* Corresponding author.

E-mail address: nicolemad@gmail.com (N. Silva).

established by the presence of high levels of serum aldosterone and plasma renin activity associated with clinical and laboratory findings of hypoaldosteronism.⁹ There are two forms that are clinically and genetically distinct. Systemic PHA 1 has an autosomal recessive transmission and result from mutations in the genes encoding the epithelial sodium channel (ENaC) that exists in multiple organs. Affected patients typically have a severe phenotype and require extremely high doses of sodium, indefinitely, to compensate their severe multiorgan salt wasting.² Renal PHA 1 has an autosomal dominant transmission and results from mutations in the gene that encodes the mineralocorticoid receptor (MR) that exists predominantly on the kidney. Generally, as the mineralocorticoid resistance is isolated to this organ, patients have a mild phenotype which often improves spontaneously after a variable period of time.²

Herein we report a 10-day-old male newborn, who developed severe hyperkalemia, hyponatremia and metabolic acidosis, initially diagnosed as congenital adrenal hyperplasia (CAH) based on an initial high level of 17-hydroxyprogesterone. Endocrinological study subsequently revealed high levels of renin and aldosterone, which led to the diagnosis of PHA 1. It was the severity of his clinical course and his systemic manifestations that made the clinical diagnosis of systemic PHA 1, leading to screening of ENaC mutations which found a homozygous mutation in intron 3 of the SCNN1A gene (c.1052 + 2dupT), which to our best knowledge has never been described before.

Case report

A 10-day-old male newborn was admitted to our hospital due to two episodes of vomiting and dehydration. He was born at full term with a birth weight of 3010 g (10–25th percentile) and there were no perinatal problems. There was no history of parental consanguinity. His older sibling, a 6-year-old female, had been diagnosed with Chediak–Higashi syndrome. Upon admission he looked sick, “septic” and dehydrated with a capillary refill time of 3 s. Heart auscultation revealed arrhythmic heart sounds, sometimes associated with bradycardia. He had no evidence of hyperpigmentation and other physical examination findings were unremarkable. Blood pressure was 89/59 mmHg, median arterial pressure (MAP) 76 mmHg (50–90th centile), heart rate varied between 60 and 120/min, respiratory rate was 40/min, oxygen saturation was 80% in room air and body temperature was 36.5 °C. Blood glucose was normal. Additionally, his weight was 2715 g (weight loss of 9.8%).

Electrocardiogram at admission in Intensive Care Unit was compatible with ventricular tachycardia and initial laboratory evaluation revealed the following: sodium 125 mEq/L; potassium >10 mEq/L; chloride 104 mEq/L; urea 62 mg/dL; creatinine 0.2 mg/dL; C-reactive protein <2.9 g/dL; hemoglobin 21.5 g/dL and hematocrit 58%. The venous blood gas analysis showed a mild metabolic acidosis (pH 7.28, PCO₂ 48.9 mmHg, HCO₃ 22.6 mmol/L, BE –4 mEq/L). Initial 17-hydroxyprogesterone level was slightly raised (10.76 ng/mL) and the rest of the endocrinologic study was in progress. He received normal saline to correct dehydration and calcium gluconate, sodium bicarbonate, nebulized salbutamol, glucose insulin infusion and ion

exchange resin to control hyperkalemia. Intravenous hydrocortisone (30 mg/kg/day) was started as CAH was initially suspected. Despite these measures, he did not improve clinically and hyponatremia did not correct with large amounts of fluid and sodium intake. Attempts at tapering treatment of hyperkalemia resulted in recurrence of severe hyperkalemia. Thus, higher doses of intravenous hydrocortisone (maximum: 200 mg/kg/day) and oral fludrocortisone (1.5 mg/day) were administered. Determination of 17-hydroxyprogesterone on Guthrie card and molecular study of CYP 21A2 were performed and were normal.

The endocrinological study obtained at the time of presentation subsequently revealed normal levels of serum cortisol, ACTH, 17-hydroxyprogesterone and DHEA sulfate but markedly elevated levels of serum aldosterone (1750 ng/dL: range 7–184 ng/dL) and plasma renin activity (70 ng/ml/h; range 0.4–1.9 ng/ml/h), hence a diagnosis of pseudohypoaldosteronism was made and steroids were tapered. Hyponatremia and dehydration continued severely in spite of large fluid and sodium intake and sodium balance was only achieved with 35 mEq/kg/day of sodium chloride. Glucose and insulin infusion, calcium gluconate, sodium bicarbonate and nebulized salbutamol were tapered and stopped and potassium controlled with high dose of ion exchange resin. During hospitalization, he was noted to have episodes of sweating and also recurrent episodes of tachypnea and fever mimicking respiratory infections.

He was discharged home with 5.5 months on oral 20% saline (30 mEq/kg/day) and ion exchange resin (6 times a day). Since then he has had recurrences of fluid and electrolyte imbalances necessitating repeated short-term hospitalizations.

The study of the SCNN1B, SCNN1G and SCNN1A was carried out subsequently and a homozygous mutation in intron 3 of the SCNN1A gene was detected (c.1052 + 2dupT) (Fig. 1).

The patient is currently 8.5 months old and his growth, in weight and length, is below the third percentile. He also has a mild development delay and is under a stimulation program achieving some improvements.

Discussion

Our patient presented with hyponatremic dehydration, metabolic acidosis and severe hyperkalemia. CAH is the most frequent cause of severe dehydration, hyponatremia and hyperkalemia in the newborn period, and therefore this was our first diagnosis, supported by a initial high level of 17-hydroxyprogesterone. However, such severe hyperkalemia, that almost leads to cardiac arrest, is unusual in hyponatremic dehydration without hemolysis, renal failure or significant intake of potassium.² Also, the disappointing response to increasing doses of steroids made CAH a less likely diagnosis. 17-hydroxyprogesterone may be falsely high in sick newborns; therefore a repeated assessment may be required for the diagnosis. This could explain our initial high level of 17-hydroxyprogesterone. PHA 1 can be differentiated clinically from CAH by an earlier onset and by no response to steroid therapy, given the delay in obtaining results for many hormonal assays.¹⁰

PHA 1 was first described in 1958 by Cheek and Perry⁴. Since then, various case reports have been published and

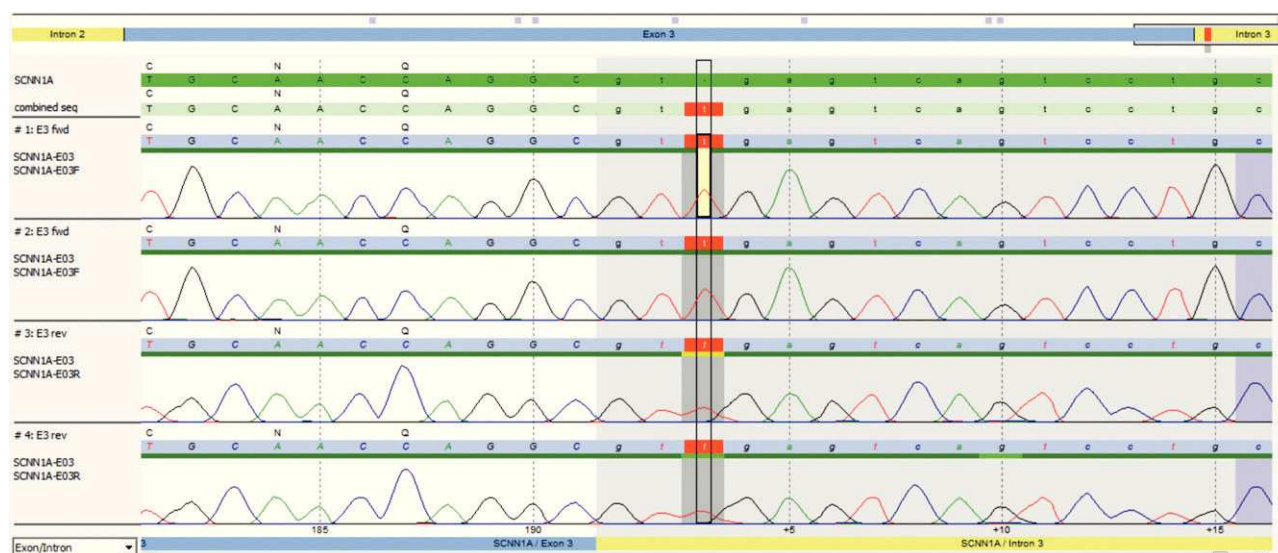


Figure 1 Electrophoretogram of the exon 3–intron 3 transition, highlighting the mutation detected.

recent genetic analysis has identified two genetically different forms of PHA 1: Renal PHA 1 or AD-PHA and Systemic PHA 1 or AR-PHA 1.⁹ Aldosterone, our most potent mineralocorticoid, plays an important role in the regulation of sodium–potassium balance and blood pressure through its effects on the ENaC.² This is done by aldosterone binding to intracytoplasmic MR, which then leads to a signaling cascade that increases the activity of ENaC. Disruption of this process, by mutations in either the MR or ENaC, leads to PHA 1, an aldosterone unresponsiveness syndrome and is thus characterized by three essential features: (1) hyperkalemia, (2) hyponatremia and (3) metabolic acidosis, in the presence of abnormally elevated serum aldosterone and plasma renin activity.³ Such mineralocorticoid resistance may be isolated to the kidney (renal PHA 1 or AD-PHA 1) or may be systemic (systemic PHA 1 or AR-PHA 1). Renal PHA 1 is a rare autosomal dominant form of mineralocorticoid resistance caused by mutations in the NR3C2 gene that encodes the MR.⁹ This mineralocorticoid unresponsiveness is isolated to the kidney leading commonly to a mild to moderate loss of sodium that responds well to sodium supplementation and generally improves spontaneously with age, possibly because of a maturation in the proximal reabsorption of sodium.^{2,9} However, a first case of autosomal recessive PHA 1 caused by compound heterozygous mutations in the MR gene has been described associated with a severe phenotype.¹² Systemic PHA 1 is caused by loss of function mutations of the ENaC subunit genes: SCNN1A (chromosome 12p13.31), SCNN1B (chromosome 16p12.1) and SCNN1G (chromosome 16p12.1).⁸ This form is associated with autosomal recessive transmission.⁶ ENaC is a hetero-multimeric protein formed by three subunits (alpha, beta, and gamma) and is expressed in multiple tissues: distal nephron, colon, sweat and salivary glands and epithelial lung cells. Therefore, this is a more severe condition because of a systemic mineralocorticoid resistance, with affected patients requiring extremely high doses of sodium to compensate their multiorgan salt wasting and sometimes fatal hyperkalemia.² Additional medical management consists on potassium-lowering agents

like ion exchangers and low potassium diet.¹¹ Elevated sodium concentration in sweat and absent nasal or rectal transepithelial voltage differences can be used as quick diagnostic tools.¹¹ Spontaneous remissions have not been described and patients require massive sodium supplementation throughout life. Of interest, affected newborns, as like ours, also manifest a pulmonary syndrome characterized by recurrent episodes of tachypnea and fever, mimicking respiratory infections, but without identifiable bacterial airway infection. This occurs probably due to impaired ability to absorb liquid from airway surfaces.^{7,8,13} Consistent with these findings, mice with disrupted alpha or beta subunits of ENaC die at birth from respiratory failure due to an inability to reabsorb lung water.² However, most of AR-PHA 1 patients do not have neonatal respiratory distress syndromes.¹¹

In our case, it was the severity of his clinical course and his systemic manifestations that made the clinical diagnosis of AR-PHA 1 or systemic PHA 1, leading to screening of ENaC mutations. Our patient has a homozygous mutation in intron 3 of the SCNN1A gene (c.1052+2dupT). The majority of the AR-PHA 1 mutations are localized on the SCNN1A gene, with mutations most frequently located on exon 8.⁵ The majority of mutations responsible for multisystem PHA 1 reported to date, are nonmissense mutations, leading to absence of normal length protein and are associated with a severe phenotype.^{5,11} Missense mutations, lead to normal length protein, and thus a more functional subunit than an absent one, and therefore these mutations are associated with milder phenotypes.⁵ The mutation described, albeit not previously described, is neither a missense, frameshift, nor nonsense mutation, but rather a splice site mutation. Although it has not been described in the literature, and therefore we do not know the precise effect of the mutation on the ENaC structure and function, its location very closely to the highly conserved donor splice site of intron 3 will most probably affect the RNA splicing of this gene and therefore to a grossly abnormal protein, and should therefore be considered as most likely clinically relevant.

Another extremely curious fact is that his older sibling has Chediak–Higashi syndrome, another rare genetic disease that has no relationship with PHA 1. Genetic analysis of his parents is currently under study.

Conclusion

The PHA 1 phenotype of our patient was particularly severe, making normalization of electrolytes a challenging task, only possible with unusually high salt intake as well as continuous ion exchange resin. It remains uncertain if there is genotype–phenotype correlation due to the rarity of the disease and due to the few reported patients with well described clinical characteristics and genotype available.^{1,11} However, it is possible that different mutations correspond to different clinical phenotypes.⁵

To better understand the pathogenesis of PAH 1 all information concerning an accurate description of the clinical phenotype and genotype should be provided to the scientific community.

Ethical approval

Written informed consent was obtained from the patient's parents for publication of this case report.

Conflicts of interest

The authors have no conflicts of interest to declare.

Acknowledgments

The genetic study of the SCNN1A, SCNN1B and SCNN1G was carried out by Cetogene Laboratory (Freiburg, Germany).

References

1. Adachi M, Tachibana K, Asakura Y, Abe S, Nakae J, Tajima T, et al. Compound heterozygous mutations in the gamma subunit gene of ENaC (1627delG and 1570-1G-A) in one sporadic Japanese patient with systemic form of pseudohypoaldosteronism type 1. *J Clin Endocrinol Metab.* 2001;86:9–12.
2. Bahareh S, Moriarty MW, Cadnapaphorchai MA. Case report: severe neonatal hyperkalemia due to pseudohypoaldosteronism type 1. *Curr Opin Pediatr.* 2009;21:269–71.
3. Bonny O, Rossier BC. Disturbances of Na/K balance: pseudohypoaldosteronism revisited. *J Am Soc Nephrol.* 2002;13:2399–414.
4. Cheek DB, Perry JW. A salt wasting syndrome in infancy. *Arch Dis Child.* 1958;33:252–6.
5. Edelheit O, Hanukoglu I, Gizewska M, Kandemir N, Tenenbaum-Rakover Y, Yurdakök M, et al. Novel mutations in the epithelial sodium channel (ENaC) subunit genes and phenotypic expression of multisystem pseudohypoaldosteronism. *Clin Endocrinol (Oxf).* 2005;62:547–53.
6. Fernandes-Rosa FL, Antonini SRR. Resistência aos mineralocorticóides: pseudo-hipoaldosteronismo Tipo 1. *Arq Bras Endocrinol Metab.* 2007;51:373–81.
7. Hanukoglu A, Bistrizter T, Rakover Y, Mandelberg A. Pseudo-hypoaldosteronism with increased sweat and saliva electrolyte values and frequent lower respiratory infections mimicking cystic fibrosis. *J Pediatr.* 1994;125:752–5.
8. Kerem E, Bistrizter T, Hanukoglu A, Hofmann T, Zhou Z, Bennett W, et al. Pulmonary epithelial sodium-channel dysfunction and excess airway liquid in pseudohypoaldosteronism. *N Engl J Med.* 1999;341:156–62.
9. Lee SE, Jung YH, Han KH, Lee HK, Kang HG, Ha Is, Choi Y, et al. A case of pseudohypoaldosteronism type 1 with a mutation in the mineralocorticoid receptor gene. *Korean J Pediatr.* 2011;54:90–3.
10. Ranjith G, Uthup S, Satish B, Jain N. Salt wasting disorder in the newborn. *Indian J Pediatr.* 2006;73:95–6.
11. Riepe FG. Clinical and molecular features of type 1 pseudohypoaldosteronism. *Horm Res.* 2009;72:1–9.
12. Teisser R, Hubert EL, Fernandes Rosa FL, Fay M, Rafestin-Oblin ME, Jeunemaitre X, et al. Severe salt-losing neonatal syndrome: the first case of autosomal recessive pseudohypoaldosteronism type 1 caused by compound heterozygous mutations in the mineralocorticoid receptor gene. 50th annual meeting of the European Society for Pediatrics Endocrinology, ESPE, 2011. Posters presentations: P1-d1-339.
13. Schaedel C, Marthinsen L, Kristoffersson AC, Kornfält R, Nilsson KO, Orlenius B, et al. Lung symptoms in pseudohypoaldosteronism type 1 are associated with deficiency of the alpha-subunit of the epithelial sodium channel. *J Pediatr.* 1999;135:739–45.