

REVIEW ARTICLE

TMEM-127 gene mutation: A rare genetic entity associated with metastatic bilateral pheochromocytoma



Mariana Ornelas*, Eduarda Resende, Pedro Gouveia, Maritza Sá, Margarida Ferreira

Serviço de Endocrinologia do Hospital Central do Funchal, Estrada dos Marmeleiros, 9050-495 Monte, Madeira, Portugal

Received 9 July 2024; accepted 8 September 2024

KEYWORDS

Pheochromocytoma;
Transmembrane
Protein 127;
Genetic testing

Abstract A 30-year pregnant woman was unexpectedly diagnosed with pheochromocytoma during obstetric follow-up. The patient – initially treated with optimal medical therapy – underwent elective C-section followed by right adrenalectomy. In the postoperative period, complete tumor resection was confirmed by negative biochemical tests. Ten years later, the patient developed new symptoms suggestive of catecholaminergic hypersecretion and biochemical tests documented increased urinary fractionated metanephrines. In the postoperative biochemical testing and imaging, persistent disease was documented. During follow-up, repeated imaging modalities evidenced the presence of hepatic and peritoneal metastasis. Genetic testing documented a germline pathogenic variant (c.410-2A>C) in the TMEM-127 gene, a rare pheochromocytoma etiology that typically presents as unilateral adrenal lesion with rare metastatic behavior. The authors underline less frequent findings described in the literature – bilaterality and metastatic behavior – and emphasize the absence of aggressive prognostic markers at initial clinical presentation.

© 2024 SEEN y SED. Published by Elsevier España, S.L.U. All rights are reserved, including those for text and data mining, AI training, and similar technologies.

PALABRAS CLAVE

Feocromocitoma;
Proteína
transmembranal 127;
Estudio genético

Mutación del gen TMEM-127: una entidad genética rara asociada con feocromocitoma bilateral metastásico

Resumen Una mujer embarazada de 30 años fue diagnosticada inesperadamente con feocromocitoma durante el seguimiento obstétrico. La paciente inició tratamiento médico y posteriormente se le realizó una cesárea electiva seguida de adrenalectomía derecha. En el postoperatorio se confirmó la resección completa del tumor con pruebas bioquímicas negativas. Diez años después, la paciente desarrolló nuevos síntomas indicativos de hipersecreción

* Corresponding author.

E-mail address: mariana.f.ornelas@hotmail.com (M. Ornelas).

catecolaminérgica y el estudio hormonal documentó un aumento de metanefrinas urinarias. Los estudios de imagen confirmaron la presencia de feocromocitoma contralateral y se realizó adrenalectomía izquierda. En el estudio hormonal e imagenológico del postoperatorio se ha documentado la persistencia de la enfermedad y durante todo el seguimiento se evidenció metástasis hepática y peritoneal. El estudio genético documentó una variante patogénica de la línea germinal del gen TMEM-127 (c.410-2a>C), que es una etiología rara de feocromocitoma; normalmente se presenta como una lesión de la glándula suprarrenal unilateral con comportamiento metastásico poco común. Los autores enfatizan hallazgos poco reportados en la literatura – bilateralidad y comportamiento metastásico – y enfatizan la ausencia de marcadores pronósticos agresivos en la presentación clínica inicial.

© 2024 SEEN y SED. Publicado por Elsevier España, S.L.U. Se reservan todos los derechos, incluidos los de minería de texto y datos, entrenamiento de IA y tecnologías similares.

Introduction

About 30% up to 35% of pheochromocytomas and paragangliomas (PPGL) have an accountable germline mutation in 1 of more than 20 susceptibility genes described while 35% up to 40% are affected by somatic mutations.¹ Genetic testing allows allocations to 1 of the 3 main molecular clusters: cluster 1 mutations (Krebs cycle/VHL/EPAS1) are associated with pseudohypoxic pathway, vascular endothelial growth factor hyperexpression and increased vascularization²; they tend to be extra-adrenal with a noradrenergic biochemical profile, sustained hypertension and significant recurrence/metastatic risk¹; cluster 2 tumors are mostly adrenal and are associated with abnormal kinase signaling pathways (PI3Kinase/AKT, RAS/RAF/ERK, mTOR), adrenergic intermittent secretion with sporadic symptoms and a less aggressive behavior.² Wnt signaling – related cluster 3 mutations are poorly described and seem to have an aggressive behavior.¹ TMEM-127 gene mutation is rarely reported (<2% of patients) and it is transmitted in a dominant autosomal inheritance pattern with no syndromic features.¹⁻³ TMEM-127 is a tumor suppressor gene involved in kinase signaling and it has been included within cluster 2 tumors.¹ When mutated, it triggers kinase overactivation with sustained cell growth, survival, proliferation, and angiogenesis. TMEM-127-related tumors (TMEM-127-RT) are described as almost exclusively adrenal (96%), frequently unilateral (62%) and with an essentially non-metastatic behavior (>95% of cases).^{1,4} The median age at diagnosis is older than 40 years, resembling sporadic pheochromocytomas and inconsistent with most familial PPGL, conditioning a challenging clinical distinction.^{1,5} This article was previously presented as an oral communication at Congresso Português de Endocrinologia, on March 3rd, 2024.

Case description

The authors report a 30-year pregnant woman with a hypertension medical history diagnosed at a young age. During obstetric follow-up, the second-trimester ultrasound documented an incidental right adrenal mass with poorly demarcated dimensions according to this imaging modality.

Table 1 Initial endocrine test at diagnosis.

24-h urine test

Fractionated catecholamines

Epinephrine, µg/24 h	4447 (4–20)
Norepinephrine, µg/24 h	86 (23–105)
Dopamine, µg/24 h	584 (190–450)
Overall, µg/24 h	5117

Fractionated metanephrines

Metanephrine, µg/24 h	16915 (<298)
Normetanephrine, µg/24 h	1580 (<354)
3-Methoxytyramine, µg/24 h	436 (<1000)
Total, µg/24 h	18931
Cortisol, µg/24 h	83.2 (58–403)
Urine volume, mL/24 h	5200

Elevated fractionated catecholamines and metanephrines in 24-h urine test were documented with a predominant adrenergic profile (urinary epinephrine and metanephrine increase), suggesting the presence of a catecholamine-secreting tumor.

On the physical examination, the patient had no virilization signs, Cushing's clinical stigmata or other associated comorbidities. The lesion was then appropriately characterized by abdominal magnetic resonance imaging (MRI) to avoid radiation exposure during pregnancy and was described as "cystic and solid 14 cm × 12 cm × 12 cm right adrenal mass, resembling a pheochromocytoma". Endocrine test of adrenal incidentaloma revealed elevated fractionated catecholamines and metanephrines (UFCM) in 24-h urine with an adrenergic predominance confirming initial suspicion of pheochromocytoma (Table 1). Optimal medical therapy with combined alpha and beta blockade (phenoxybenzamine plus labetalol) was initiated prior to surgery and maintained until labor with satisfactory blood pressure levels and heart rate control. Afterwards, a sequential surgical strategy was adopted: the patient first underwent an elective C-section on week 36 of her pregnancy with no postoperative complications; the surgery was followed by tumoral staging with thoracoabdominopelvic computed tomography (CT) that excluded metastatic disease; afterwards, the patient underwent successfully right

Table 2 Hormonal test progression at the follow-up.

	10 years after right adrenalectomy	1 month after left adrenalectomy
24-h urine test		
<i>Fractionated catecholamines</i>		
Epinephrine, $\mu\text{g}/24\text{h}$	35.7 (0.5–20)	26.2 (0.5–20)
Norepinephrine, $\mu\text{g}/24\text{h}$	31.6 (15–80)	36.9 (15–80)
Dopamine, $\mu\text{g}/24\text{h}$	265.3 (65–400)	124.3 (65–400)
Total, $\mu\text{g}/24\text{h}$	332.5	187.3
<i>Fractionated metanephrines</i>		
Metanephrine, $\mu\text{g}/24\text{h}$	1290 (≤ 276.1)	565 (< 276)
Normetanephrine, $\mu\text{g}/24\text{h}$	191.4 (≤ 549.6)	96.5 (≤ 632)
3-Methoxytyramine, $\mu\text{g}/24\text{h}$	105.6 (≤ 459.6)	80.2 (≤ 426.4)
Total, $\mu\text{g}/24\text{h}$	1587	742
Cortisol, $\mu\text{g}/24\text{h}$	80.8 (59–403)	–
Urine volume, mL/24h	2750	1900

Emergence of catecholaminergic symptoms and increased urinary fractionated catecholamines and metanephrines levels with adrenergic predominance 10 years after right adrenalectomy were consistent with pheochromocytoma relapse. After imaging documentation of a contralateral pheochromocytoma, the patient underwent left adrenalectomy. The 1-month postoperative endocrine test confirmed biochemical disease persistence with increased urinary metanephrines.

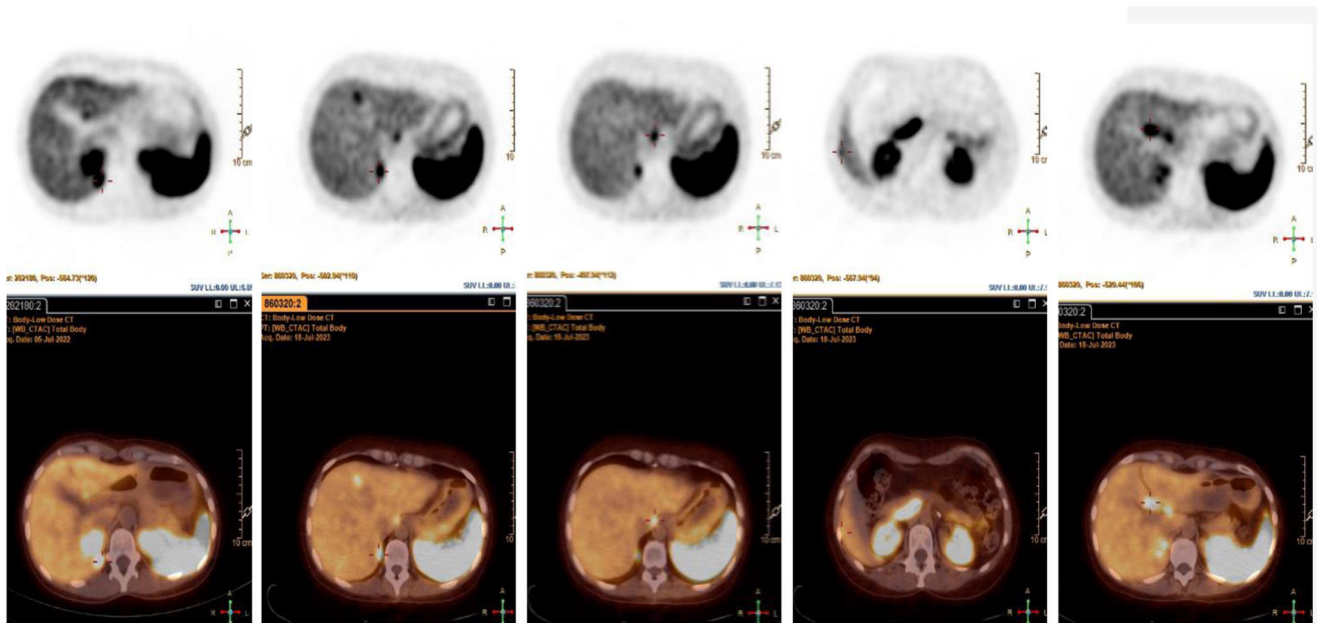


Figure 1 Functional imaging modality with evidence of metastatic disease. A ^{68}Ga -DOTANOC PET/CT was performed after biochemical persistence disease documentation following bilateral adrenalectomy. Radiotracer uptake was consistent with multiple metastatic foci expression in the following locations: right kidney posterior region, liver medial region, and anterior region of the right 12th rib; several peritoneal lesions were found on the right paravertebral and right pre-aortic perihepatic region and lateral liver surface (segment V/VI), along with multiple hepatic hilum foci, which may be adenopathies or peritoneal lesions.

adrenalectomy and was discharged from the hospital clinically stable. Pathology report confirmed the diagnosis of pheochromocytoma. Three months later, biochemical testing with UFCM and postoperative abdominal imaging was suggestive of total tumor removal. The patient maintained endocrine annual follow-up with UFCM levels and remained biochemically stable for 10 years. After this, the patient started experiencing occasional palpitations suggestive of catecholamines hypersecretion and the UFCM confirmed the presence of biochemical disease

relapse (Table 2). Abdominopelvic CT (APCT) revealed a 16mm adrenal nodule in the left contralateral adrenal gland with 32 Hounsfield Units (HU). Functional imaging was conducted and both metaiodobenzylguanidine (MIBG) scintigraphy and single-photon emission computed tomography (SPECT) demonstrated localized hyperfixation in the left adrenal gland. The patient underwent left adrenalectomy with no postoperative complications. Pathology report suggested pheochromocytoma diagnosis with no invasion of other structures, Ki-67 index $< 5\%$ with positive immunohis-

tochemical staining for chromogranin and synaptophysin. In the 3-month postoperative test, disease persistence was documented (Table 2). The patient repeated APCT that revealed no traces of metastasis; however nuclear medicine imaging with ⁶⁸Ga-DOTANOC PET/CT (Fig. 1) and MIBG detected metastatic disease in the right kidney posterior region, hepatic foci and peritoneal carcinomatosis. The patient underwent biochemical, anatomic, and functional imaging exams throughout an 8-month period that showed stable metastatic disease. Attending to the complex nature of this case, it was discussed with a multidisciplinary team of a reference cancer center and clinical follow-up was determined. In case of disease progression, the patient would be proposed to peptide receptor radionuclide therapy using somatostatin receptors. The patient underwent genetic testing and a germline pathogenic variant (c.410-2A>C) in TMEM-127 gene was documented. Her only daughter was also tested when she was 14 years old and presented the same genetic mutation. She is currently asymptomatic and awaits biochemical evaluation.

Management (and supporting evidence)

Although the treatment of TMEM-127-RT is surgical whenever possible, it is not necessarily curative¹ since these tumors might be recurrent or multifocal. If surgical approach is unfeasible, systemic therapy may include chemotherapy, radionuclide therapy, tyrosine kinase inhibitors and immunotherapy; genetically driven cluster-specific therapy is currently under investigation as a promising emerging therapy; however it is not currently well established.^{1,3} Current management recommendations released by the of the European Society of Hypertension Working Group on Endocrine Hypertension for metastatic PPGL suggest chemotherapy as a first-line therapy for rapidly progressing PPGL (<6 months) and radionuclide therapy (¹³¹I-metaiodobenzylguanidine [¹³¹I-MIBG] or peptide receptor radionuclide therapy [PRRT] depending on tumor uptake and location) as first-line therapy for slow-to-moderately progressing PPGL (>6 months).³ Other therapies include tyrosine kinase inhibitors (sunitinib, cabozantinib, lenvatinib), somatostatin analogues or other specific targeted signaling pathway inhibitors.^{1,3} Systemic therapy is rarely necessary in cluster 2 tumors due to the low metastatic risk involved.

Areas of uncertainty

Disease penetrance associated with TMEM-127 gene mutation is unknown due to its rare occurrence (<2% of patients) with conflicting data: although some studies have suggested a low penetrance level, recent evidence suggests the high penetrance capabilities of PPGL.^{1,4}

Inconsistent data have been reported on PPGL biochemical profile: a study reported no predominant catecholamine secretion⁶ and others suggested an adrenaline secretion predominance.⁷⁻⁹ There are no specific recommendations on the at-risk patients' ideal age to offer genetic testing or clinical follow-up of asymptomatic mutation carriers. Toledo et al. suggested genetic screening at age 22 years

and annual clinical follow-up with biochemical testing in mutation carriers.⁴

Guidelines

2017 WHO classification abandoned the terms "benign" and "malignant" for PPGL characterization regarding the absence of a histological classification predictable of metastatic behavior and instead endorsed the term "metastatic" as a more suitable term. All pheochromocytomas have metastatic potential but it has rarely been described with this mutation.^{2,3} Currently, there are no predictive biomarkers of metastatic behavior, nevertheless there are some risk features: tumor size ≥ 5 cm, multifocality, extra-adrenal location, specific mutations (SDHx, fumarate hydratase, malate dehydrogenase 2, solute carrier family 25 Member 11, hypoxia inducible factor 2 α), noradrenergic/dopaminergic phenotype, high Ki-67 index or previously detectable metastatic lesions.¹⁻³ This aggressive phenotype was unpredictable at diagnosis since none of these prognostic features were present at the time.

PPGL clinical characterization and treatment has grown exponentially in the last years and cluster-specific management is being addressed. Recent published guidelines released in 2021 by the Endocrine Society advocate for a personalized management according to cluster groups. In patients with PPGL history, periodic clinical follow-up of the removed adrenal surgical site and contralateral gland is recommended due to its multicentric/bilaterality occurrence.⁴ More recent evidence suggests annual biochemical evaluation and abdominal/pelvic MRI once every 5 years in TMEM-127-RT (by analogy to RET- and NF1-mutation, both cluster 2 mutations).¹

Conclusions and recommendations

This case reveals an unpredicted metastatic behavior in a tumor with slow-to-moderate progression related to TMEM-127 gene mutation. Although described as almost exclusively non-metastatic, some authors documented metastatic behavior or aggressive histological profile in other genetic variants.^{5,6,10,11} Nonetheless, Toledo et al. studied a six-generation family carrying this specific variant (c.410-2A>C) and no metastases were found.

The authors emphasize that all PPGL have potential metastatic behavior, even if they are categorized as low-risk metastatic cluster 2 tumors and exhibit an adrenergic profile (that should not promptly be interpreted as a benign course predictor). The genotype-phenotype correlation promotes tumor behavior prediction, nonetheless it should not be empirically interpreted since some of these genetic changes are still under characterization. Another distinct feature of this case was the early age at which diagnosis was established (30 years) compared with the older age often described in TMEM-127-RT (>40 years), which speaks for how sporadic these early cases really are. Particularly in the case of TMEM-127-RT, clinical follow-up of the removed adrenal surgical site and contralateral gland is needed throughout life due to its multicentric/bilaterality nature. Considering that PPGL are the most hereditary endocrine tumors,

genetic testing is mandatory in all cases regardless of the characteristics of the patients and their families.

Declaration of generative AI and AI-assisted technologies in the writing process

Nothing to declare.

Funding

None declared.

Conflicts of interest

None declared.

Acknowledgements

The authors would like to thank the accurate clinical information and functional imaging kindly provided by Nuclear Medicine and Endocrinology departments of Instituto Português de Oncologia de Lisboa Francisco Gentil (Lisbon, Portugal).

References

- Nölting S, Bechmann N, Taieb D, Beuschlein F, Fassnacht M, Kroiss M, et al. Personalized management of pheochromocytoma and paraganglioma. *Endocr Rev.* 2021;43:199–239, <http://dx.doi.org/10.1210/edrev/bnab019>.
- Lam AK. Update on adrenal tumours in 2017 World Health Organization (WHO) of endocrine tumours. *Endocr Pathol.* 2017;28:213–27, <http://dx.doi.org/10.1007/s12022-017-9484-5> [PubMed PMID: 28477311].
- Lenders JWM, Kerstens MN, Amar L, Prejbisz A, Robledo M, Taieb D, et al. Genetics, diagnosis, management and future directions of research of phaeochromocytoma and paraganglioma: a position statement and consensus of the Working Group on Endocrine Hypertension of the European Society of Hypertension. *J Hypertens.* 2020;38:1443–56, <http://dx.doi.org/10.1097/hjh.0000000000002438> [PubMed PMID: 32412940; PubMed Central PMCID: PMC7486815].
- Toledo SP, Lourenço DM Jr, Sekiya T, Lucon AM, Baena ME, Castro CC, et al. Penetrance and clinical features of pheochromocytoma in a six-generation family carrying a germline TMEM127 mutation. *J Clin Endocrinol Metab.* 2015;100:E308–18, <http://dx.doi.org/10.1210/jc.2014-2473> [Epub 12.11.14; PubMed PMID: 25389632].
- Armaiz-Pena G, Flores SK, Cheng ZM, Zhang X, Esquivel E, Poullard N, et al. Genotype–phenotype features of germline variants of the TMEM127 pheochromocytoma susceptibility gene: a 10-year update. *J Clin Endocrinol Metab.* 2021;106:e350–64, <http://dx.doi.org/10.1210/clinem/dgaa741> [PubMed PMID: 33051659; PubMed Central PMCID: PMC7765648].
- Yao L, Schiavi F, Cascon A, Qin Y, Inglada-Pérez L, King EE, et al. Spectrum and prevalence of FP/TMEM127 gene mutations in pheochromocytomas and paragangliomas. *JAMA.* 2010;304:2611–9, <http://dx.doi.org/10.1001/jama.2010.1830> [PubMed PMID: 21156949].
- Abermil N, Guillaud-Bataille M, Burnichon N, Venisse A, Manivet P, Guignat L, et al. TMEM127 screening in a large cohort of patients with pheochromocytoma and/or paraganglioma. *J Clin Endocrinol Metab.* 2012;97:E805–9, <http://dx.doi.org/10.1210/jc.2011-3360> [Epub 14.03.12; PubMed PMID: 22419703].
- Hernandez KG, Ezzat S, Morel CF, Swallow C, Otremba M, Dickson BC, et al. Familial pheochromocytoma and renal cell carcinoma syndrome: TMEM127 as a novel candidate gene for the association. *Virchows Arch.* 2015;466:727–32, <http://dx.doi.org/10.1007/s00428-015-1755-2> [Epub 24.03.15; PubMed PMID: 25800244].
- Fernández-Pombo A, Cameselle-Teijeiro JM, Puñal-Rodríguez JA, Loidi L, Peinó-García R, Cabanas-Rodríguez P, et al. Novel. *Case Rep Endocrinol.* 2019;2019:2502174, <http://dx.doi.org/10.1155/2019/2502174> [Epub 27.10.19; PubMed PMID: 31781416; PubMed Central PMCID: PMC6855059].
- Favier J, Amar L, Gimenez-Roqueplo AP. Paraganglioma and phaeochromocytoma: from genetics to personalized medicine. *Nat Rev Endocrinol.* 2015;11:101–11, <http://dx.doi.org/10.1038/nrendo.2014.188> [Epub 11.11.14; PubMed PMID: 25385035].
- Bausch B, Schiavi F, Ni Y, Welander J, Patocs A, Ngeow J, et al. Clinical characterization of the pheochromocytoma and paraganglioma susceptibility genes SDHA, TMEM127, MAX, and SDHAF2 for gene-informed prevention. *JAMA Oncol.* 2017;3:1204–12, <http://dx.doi.org/10.1001/jamaoncol.2017.0223> [PubMed PMID: 28384794; PubMed Central PMCID: PMC5824290].