

LETTER TO THE EDITORS

---

## ATYPICAL CHOROIDAL MELANOMA: REPORT OF 3 CASES

André Gustavo Bombana Nicoletti, Deborah Salerno Costa, Ramon Coral Ghanem, Pedro Carlos Carricondo, Ruth Miyuki Santo, and Suzana Matayoshi

---

Choroidal melanoma is the most common primary ocular malignant neoplasm among adults.<sup>1</sup> However, innumerable benign and malignant lesions may mimic its ophthalmoscopic features.<sup>2</sup> Moreover, atypical presentations of the tumor may also occur, in some cases making diagnostic elucidation even more difficult and thus increasing the importance of supplementary tests, especially ultrasonographic methods. Three cases of choroidal melanoma with uncommon clinical features are presented in which the supplementary tests and the clinical follow-up were essential for the correct diagnosis of the lesions.

## CASE 1

A female patient, 44 years old, leukodermatous, presented with a 2-week history of sudden decrease in visual acuity of the right eye, preceded by photopsia for approximately 2 weeks. On examination of visual acuity by finger counting at 20 cm, an afferent pupillary defect was observed; intraocular pressure (IOP) was 12 mm Hg. On biomicroscopy, retro-lens retinal detachment was observed, which was better evidenced on retinal mapping, where an inferior exudative detachment with involvement of the posterior pole was found. No abnormalities were detected on examination of the left eye. Echography of the right eye revealed the presence of an elevated vitreous lesion with a base diameter of approximately 16 mm, anteriorly limited by the retina and/or choroid, and with high internal reflectivity. In view of these findings, diagnostic hypotheses such as malignant choroidal melanoma and suprachoroidal

hemorrhage were considered. The option was echography every 2 weeks, upon which the presence of low internal reflectivity, forming an angle kappa highly suggestive of melanoma of the choroid<sup>3</sup> was evidenced. The presence of arterial vascularization in the interior of the lesion on Doppler ultrasound reinforced this hypothesis. Clinical staging tests did not show systemic dissemination of the tumor.

The proposed treatment was enucleation of the of the right eyeball, which was initially rejected by the patient; however, within 30 days, she progressed with signs of pain, total retinal detachment, light perception visual acuity, 58 mm Hg IOP, rubeosis iridis on biomicroscopy, and angle neovascularization on gonioscopy, characterizing neovascular glaucoma. Enucleation of the right eyeball was performed, and histopathologic examination revealed a neoplasm of choroidal origin predominantly occupying the inferior quadrants with an approximate thickness of 15 mm at the greater axis associated with total retinal detachment. The tumor was extensively necrotic (over 90%) with hemorrhagic areas and lymphocyte infiltration. The search for melanin in the whole tumor, including necrotic cells, was positive. The immunohistochemical tests were positive for S-100, vimentin, and HMB-45, confirming the diagnosis of choroidal melanoma.

The patient is without evidence of local or systemic relapse after 18 months of follow-up.

## CASE 2

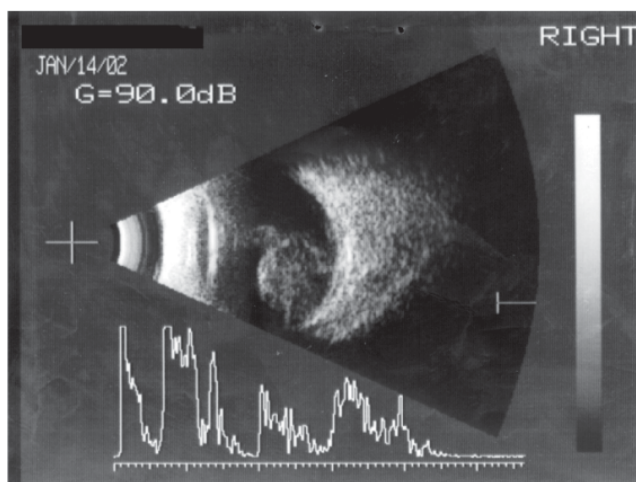
A female patient, 51 years old, leukodermatous, presented with a history of intense ocular pain in the right eye for 6 days, with ipsilateral irradiation to the frontoparietal region. She reported loss of vision of this eye 10 years previously after a blunt ocular injury. On examination, absence

---

Department of Ophthalmology, Hospital das Clínicas, São Paulo University Medical School - São Paulo/SP, Brazil.  
Email: [deborahsalerno@yahoo.com.br](mailto:deborahsalerno@yahoo.com.br)

This is an Open Access article distributed under the terms of the Creative Commons Attribution Non-Commercial License (<http://creativecommons.org/licenses/by-nc/3.0/>) which permits unrestricted non-commercial use, distribution, and reproduction in any medium, provided the original work is properly cited.

of light perception visual acuity, fixed medial mydriasis, glaukomflecken, congested iris vessels, and a shallow anterior chamber were observed. On funduscopy, the retina appeared fibrotic and completely detached. Intraocular pressure measured by applanation tonometry was 58 mm Hg. On gonioscopy, a 360° angle closure without presence of new blood vessels on indentation was observed. The left eye presented visual acuity of 20/20 with -1.00 D sph, a deep anterior chamber, and an IOP 14 of mm Hg. Echography the right eye was then performed showing closed funnel retinal detachment and the presence of a solid lesion in the temporal sector with a base diameter of approximately 8 mm (in the B mode), with low to moderate internal reflectivity forming the angle kappa observed in the A mode (Figure 1). After clinical evaluation, enucleation of the right eyeball was indicated. The histopathologic examination confirmed the established hypothesis of malignant choroidal melanoma.



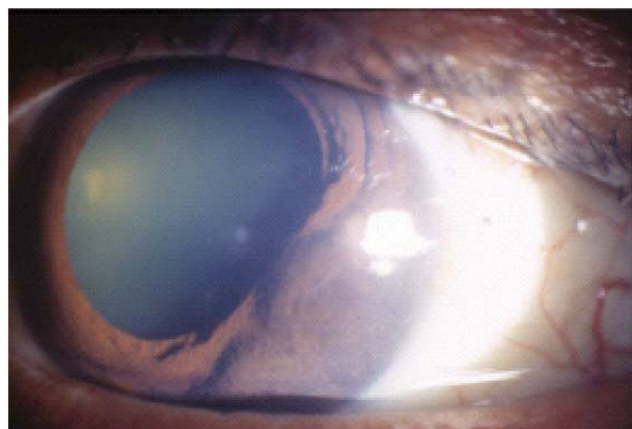
**Figure 1** - Case 2 echography: Closed funnel retinal detachment and the presence of a solid lesion in the temporal sector with a diameter of approximately 8 mm, with low to moderate internal reflectivity forming the angle kappa

The patient is being followed up as an outpatient and is without evidence of systemic dissemination 1 year after the diagnosis.

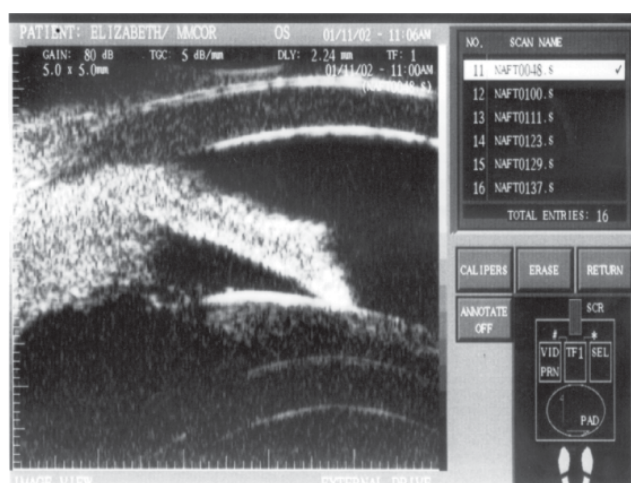
### CASE 3

A female patient, 50 years old, leukodermatous, presented with complaints of pain of moderate intensity and reduction in visual acuity for approximately 2 months. On examination, the visual acuity measured in the left eye was 20/80. The direct pupillary light reflex was decreased on the left, with a relative afferent defect. On biomicroscopy a pigmented nodule was detected in the inferior temporal sector of the iris of the left eye, associated with mild con-

junctival hyperemia and anterior chamber reaction (Figure 2). The mean IOP was 14 mm Hg. On funduscopy, the presence of an inferior exudative retinal detachment was observed with involvement of the posterior pole. Examination of the right eye did not reveal alterations. On echography, an elevated, solid, and homogeneous lesion with medium to low echogenicity was detected, delineating the angle kappa in the region anterior to the inferior temporal equator, associated with inferior retinal detachment involving the posterior pole. The length of the lesion basement was 13.7 mm transversally, and the height was 6 mm. Ultrasound biomicroscopy (UBM) showed rectification and anterior detachment of the inferior temporal sector of the iris, with disorganization of the ciliary processes between 3 and 5 hours. In addition, an increase in the thickness of the ciliary body in a solid form and with variable echogenicity with impairment of the root of the iris was observed (Figure 3).



**Figure 2** - Case 3 biomicroscopy: a pigmented nodule was detected in the inferior temporal sector of the iris



**Figure 3** - Case 3 ultrasound biomicroscopy (UBM): increase in the thickness of the ciliary body, in a solid form and with variable echogenicity, with impairment of the root of the iris

In view of the described features, the established diagnosis was choroidal melanoma with extension to the iris through the ciliary body. After systemic examination, the patient underwent enucleation of the left eyeball. Histopathologic examination confirmed uveal involvement by primary choroidal melanoma.

After approximately 1 year, the patient is without any evidence of local or systemic relapse.

## DISCUSSION

Innumerable benign and malignant lesions may simulate the ophthalmoscopic features of choroidal melanoma.<sup>2</sup> Historically, 20% of enucleated eyes with a clinical diagnosis of malignant choroidal melanoma presented benign lesions on histological examination. More recent studies, based on improved supplementary tests, have reported a much better diagnostic precision, with 95% to 100% correct diagnoses.<sup>2-5</sup> The Collaborative Ocular Melanoma Study Group (COMS) found only 2 false positive cases (0.48%) in 413 eyes with a clinical diagnosis of malignant choroidal melanoma.<sup>2</sup>

Among the lesions that might simulate ophthalmoscopic features of malignant melanoma, limited hemorrhages of the choroid should be noted, which may result from abnormal conditions such as hypotonia, inflammation, trauma, vascular diseases, or which might even occur spontaneously.<sup>6-9</sup> Recent choroidal hemorrhages present a reddish color, but after their organization, hemosiderin content and associated proliferation of the retinal pigment epithelium result in an ophthalmoscopic aspect similar to melanoma of the choroid.<sup>10</sup> In addition, this lesion may be presented as a typical hemorrhagic choroidal detachment. Reese et al<sup>11</sup> reported a case that seemed to be a hemorrhagic process and was later correctly diagnosed as melanoma. This fact was attributed to the initial presence of an associated choroidal hemorrhage that masked the presence of the tumor. Indeed, the patient of case 1 had choroidal hemorrhage concomitant with the tumoral lesion, which made the initial diagnosis difficult, both by impairing adequate identification of the lesion and by producing a high internal reflectivity, a characteristic contrary to that of melanoma. The extensive necrosis observed in case 1 of over 90% is an atypical histologic presentation and could also be responsible for the detected high internal reflectivity, as has been proposed by Bujara et al.<sup>12</sup> However, choroidal hemorrhages may also present with low internal reflectivity, making the differential diagnosis even more difficult.

Using color Doppler, the presence of arterial vascularization was observed in the interior of the tumor, providing

further support for the elucidation of the case. Lieb et al,<sup>13</sup> studying 44 intraocular masses, were able to show blood in the interior of 39 of them. In addition, they were not able to identify a vascular supply to benign lesions.

Some authors have reported cases of patients with a clinical diagnosis of malignant choroidal melanoma who actually presented limited hemorrhages that were observed only during the follow-up of these patients after detection of reduction in the diameter of these lesions.<sup>6,8</sup> Augsburger et al observed that such hemorrhages completely disappeared within periods of less than 2 months.<sup>7</sup>

Association between uveal melanomas and secondary glaucomas has been established by several authors.<sup>14-17</sup> The occurrence of glaucomas secondary to intraocular tumors has been known for many years. In 1896, Marshall et al<sup>18</sup> observed that 57% of eyes enucleated because of uveal melanomas presented intraocular hypertension. Yanoff<sup>17</sup> studied 96 eyes with a diagnosis of uveal melanoma and detected ocular hypertension in 19 cases (20%). These authors also observed that tumors of the anterior segment or those of the posterior segment presenting a large volume, mainly those accompanied by total retinal detachment, were more frequently associated with secondary glaucomas. Indeed, the patient of case 2 presented a choroidal lesion of large volume and associated with total retinal detachment, although she had first been diagnosed 10 years after a blunt ocular trauma.

Crises of angular closure typically occur in anatomically predisposed eyes, which, among other particularities, present a decrease in the axial length of the eye.<sup>19</sup> In general, such characteristics are observed bilaterally. The patient of case 2 presented an anterior chamber with normal depth in the noninvolved eye, which led to the suspicion of a secondary cause of angular closure and increase in IOP, although angular closure without neovascularization associated with choroidal melanoma is an atypical clinical presentation. Because of the presence of total retinal detachment, fundoscopic examination of the posterior segment was not possible, and echography was required. In the B mode, a roundish choroidal lesion was observed, with a base diameter of approximately 8 mm, localized at the posterior pole. In the A mode, low internal reflectivity was observed determining the angle kappa; such characteristics were compatible with malignant choroidal melanoma,<sup>3</sup> which was confirmed afterwards by histopathologic examination. According to Yanoff,<sup>17</sup> the presence of glaucoma may render the diagnosis of malignant uveal melanomas difficult. This author observed that the clinical diagnosis of these tumors before enucleation was obtained in 75/77 (95%) nonglaucomatous patients and in only 12/19 (63%) cases of secondary glaucoma, with 6 of 7 nondiagnosed

patients of the latter group presenting opacification of the optical media.

Shield et al<sup>20</sup> evaluated 200 patients (208 eyes) referred to them because of lesions of the iris suspected to be malignant melanoma. The clinical diagnosis of melanoma of the iris was confirmed in only 40 eyes (24%). The other lesions were classified as pseudomelanomas, the most frequent findings being primary cysts, nevus, essential atrophy, and foreign bodies.

Secondary involvement of the iris by a choroidal melanoma is a rare condition and must also be considered in the differential diagnosis of pigmented nodules of the

iris, as was observed in the patient of case 3. In these situations, UBM is of great value because it is able to identify the tumor's extent by contiguity of the choroidal melanoma to the anterior uvea.

The 3 described cases illustrate different clinical presentations of uveal melanoma, which, together with the different benign lesions simulating their clinical aspects, contributed to the difficult diagnosis of these and certain other cases. Ultrasonographic methods (echography and UBM) and outpatient follow-up make a correct diagnosis and treatment possible and practical for these patients with a clinical suspicion - even if it is a remote possibility - of a malignant tumor.

## REFERENCES

1. Scotto J, Fraumeni FJ, Lee JH. Melanomas of the eye and other noncutaneous sites: epidemiologic aspects. *J Natl Cancer Inst.* 1976;56:489-91.
2. Accuracy of diagnosis of choroidal melanomas in the Collaborative Ocular Melanoma Study. COMS report no. 1. *Arch Ophthalmol.* 1990;108:1268-73.
3. Fuller DG, Snyder WB, Hutton WL, Vaiser A. Ultrasonographic features of choroidal malignant melanomas. *Arch Ophthalmol.* 1979;97:1465-72.
4. Char DH, Stone RD, Irvine AR, Crawford JB, Hilton GF, Lonn LI, et al. Diagnostic modalities in choroidal melanoma: sensitivity, specificity, and reproducibility. *Am J Ophthalmol.* 1980;89:223-30.
5. Ferry AP. Lesions mistaken for malignant melanoma of the posterior uvea. A clinicopathologic analysis of 100 cases with ophthalmoscopically visible lesions. *Arch Ophthalmol.* 1964;72:463-9.
6. Morgan CM, Gragoudas ES. Limited choroidal hemorrhage mistaken for a choroidal melanoma. *Ophthalmology.* 1987;94:41-46.
7. Augsburger JJ, Coats TD, Lauritzen K. Localized suprachoroidal hematomas - ophthalmoscopic features, fluorescein angiography, and clinical course. *Arch Ophthalmol.* 1990;108:968-72.
8. Williams DF, Mieler WF, Lewandowski M. Resolution of an apparent choroidal melanoma. *Retina.* 1989;9:131-35.
9. Brubaker RF. Intra-ocular surgery and choroidal hemorrhage. *Arch Ophthalmol.* 1984;102: 1753-4.
10. Reese AB. Tumors of the Eye. 3rd edition, Hagerstown, MD. Harper and Row. 1976, p 174-262.
11. Reese AB. The differential diagnosis of malignant melanoma of the choroid. *Arch Ophthalmol.* 1957;58:477-82.
12. Bujara K, Domarus VD, Guthoff R. Necrotic malignant melanoma of the choroid with unusual clinical course. A clinical echographical and histological case study. *Ophthalmologica.* 1980;180:222-7.
13. Lieb WE, Shields JA, Cohen SM. Color Doppler imaging in the management of intraocular tumors. *Ophthalmology.* 1990;97:1660-4.
14. Jensen OA. Malignant melanomas of the uvea in Denmark 1943-1952. A clinical, histopathological, and prognostic study. *Acta Ophthalmol.* 75 (Suppl), 1963;75:1-220.
15. Shields MB, Klintworth GK. Anterior uveal melanomas and intraocular pressure. *Ophthalmology.* 1980;87:503-17.
16. Shields MB, Proia AD. Neovascular glaucoma associated with an iris melanoma. *Arch Ophthalmol.* 1987;105:672-74.
17. Yanoff M. Glaucoma mechanisms in ocular malignant melanomas. *Am J Ophthalmol.* 1970;70:898-904.
18. Marshall CD. On tension in cases of intraocular tumors. *Tr Ophthalmol Soc.* 1896;16:155.
19. George R, Paul PG, Baskaran M, Ve Ramesh S, Raju P, Arvind H, et al. Ocular biometry in occludable angles and angle closure glaucoma: a population based survey. *Br J Ophthalmol* 2003;87:399-402.
20. Shields JA, Sanborn ES, Augsburger JJ. The differential diagnosis of malignant melanoma of the iris. *Ophthalmology.* 1983;90:716-20.