

## LETTER TO THE EDITOR

# Lumbar hernia following percutaneous nephrolithotomy

Ernesto Reggio,<sup>I,II</sup> Marcelo José Sette,<sup>I</sup> Ricardo Lemos,<sup>I,III</sup> Odival Timm Jr,<sup>I</sup> Roberto Gomes Junqueira<sup>I,III</sup>

<sup>I</sup>Centro Hospitalar Unimed, Joinville, Santa Catarina, Brazil. <sup>II</sup>Pontífice Universidade Católica do Paraná, Paraná, Brazil. <sup>III</sup>Universidade de Joinville (Univille), Joinville, Santa Catarina, Brazil.

Email: e\_reggio@hotmail.com

Tel.: 55 47 3433-2531

Percutaneous renal surgery (PRS) is the established procedure to treat several renal conditions, such as large renal stones, ureteropelvic obstruction, and upper tract transitional cell carcinoma. Complications, including urinary tract infections, bleeding necessitating transfusion, extravasation, and transient ureteral obstruction, are uncommon. Other well described complications are pneumothorax or hydrothorax, pneumonia/atelectasis, urinoma formation, bowel injury, or escape of stone fragments into the retroperitoneum.<sup>1</sup> At that time, lumbotomy was the most common approach to the kidney, and many patients developed either muscle atrophy or fascial defects. Because of the particular anatomy of retroperitoneum, this condition might be difficult to repair.<sup>2</sup> Percutaneous access is carried out using dilating systems generally considered to be less traumatic. This technique is less aggressive to the abdominal wall. To our knowledge, this is the first report of this complication after PRS.

## CASE REPORT

A 46-year-old woman was referred to us with a 31-mm pelvic renal stone. Percutaneous nephrolithotripsy (PRN) was carried out under general anesthesia. The patient was placed in the prone position, and a lower pole calyx was selected for renal access. An 18-gauge diamond tip needle was inserted into the opacified calyx. Two punctures were necessary to enter the collecting system. Acute tract dilation was performed only once by inserting Alkens serial coaxial dilators to 26Fr and then Amplatz dilator set with a 30Fr sheath under fluoroscopic guidance. We utilized pneumatic lithotripsy, and a complete removal of fragments was achieved. There was no need for Amplatz sheath repositioning during the procedure. Subsequently, an 18Fr nephrostomy tube was positioned into the renal pelvis. On the second postoperative day, the tube was removed, and the patient was discharged.

Five months later, the patient returned, complaining of lumbar pain. She had a small bulge around the lumbar scar. The patient denied risk factors associated with lumbar hernia, such as chronic debilitation, nutritional depletion, obesity, pulmonary conditions with cough, and previous wound infection. Results of a physical examination revealed

a soft, small mass at the site of the previous surgery. A sonography was obtained and revealed a herniation through a 2.17-cm muscle defect (see Fig. 1).

Laparoscopic transperitoneal access with three ports was used. The descending colon was mobilized medially by opening the peritoneal reflection. In addition, the muscle defect was located and measured (see Figure 2). Then, a 10×6-cm polypropylene mesh was placed over the defect. Alignment of the mesh was completed, with 2cm beyond the edges of the defect. The mesh was then stapled to the wall by titanium clips (Endopath EMS; Ethicon Endo-Surgery, Cincinnati, OH) (see Fig. 3). The peritoneum was brought up over the mesh and secured with staples in order to prevent bowel adhesions. Herniorrhaphy was successfully performed with this prosthetic patch laparoscopic technique. We have followed the patient for 26 months, and there is no evidence of recurrence.

## DISCUSSION

Lumbar hernias are uncommon clinical entities that were more prevalent in past eras of conventional renal surgery. Laparoscopic and percutaneous procedures have reduced the incidence of incisional hernias. Moreno-Egea recently reported that there are only approximately 300 cases in the literature.<sup>3</sup> Lumbar hernias are classified as congenital, generally associated with other malformations, or acquired, usually secondary to trauma or surgical incision.<sup>4</sup>

Non-bladed trocar and radially dilating systems, which are frequently used in laparoscopy and percutaneous renal

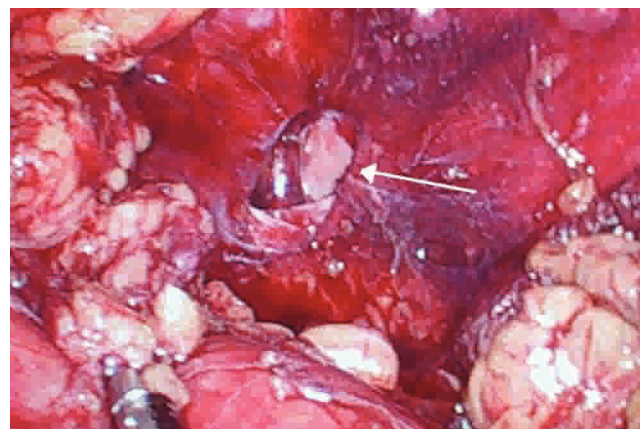
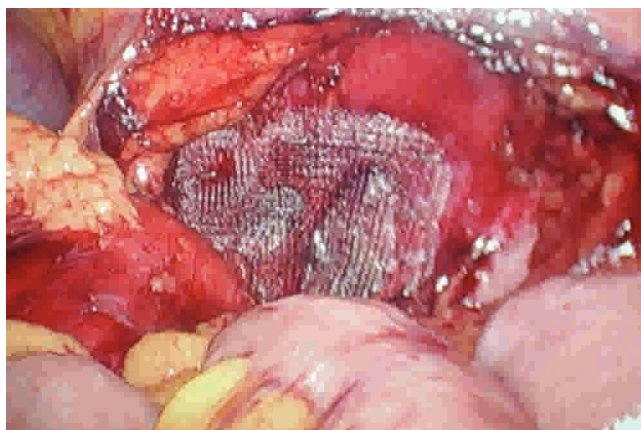
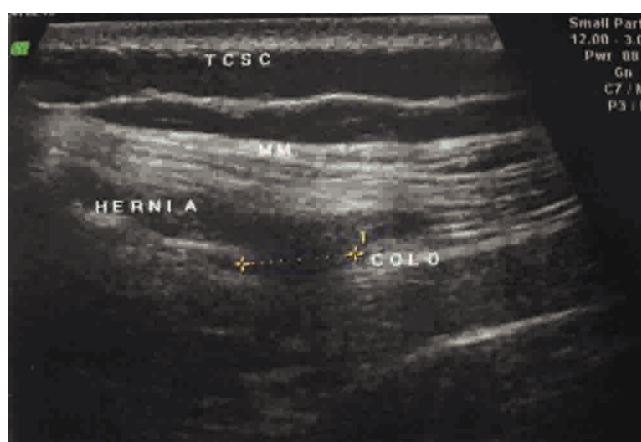


Figure 1 - Sonography showing the muscle defect.



**Figure 2** - Posterior wall and muscle defect.



**Figure 3** - Mesh inserted and fixed on the wall by titanium clips.

surgery, are considered to be less traumatic to the abdominal wall because they do not incise the fascia. However, trocar site hernias following laparoscopic surgery are well known complications.<sup>5</sup> Percutaneous renal surgery is usually performed with non-traumatic dilating systems, such as an Amplatz dilator set and Alkens serial coaxial dilators. The Amplatz sheath site closure is unnecessary and does not result in herniation, as the posterior wall is formed by strong and thick muscles. Nevertheless, other variables may predispose patients to herniation, including muscular atrophy, undernourishment, and poor wound healing conditions. In this particular case, we could not identify any of those conditions, but noted the leanness of the patient. The hernia formation mechanism might have been similar to that of a trocar site hernia. The diagnosis of lumbar hernia may be made clinically in the majority of cases. The most common manifestation is a palpable mass. Imaging tests are useful to confirm the diagnosis and evaluate anatomical relationships. A CT scan can provide necessary information, optimizing therapeutic decisions.<sup>6</sup> Sonography was used in this case, given that the anatomical

features of the patient allowed for a reliable evaluation of the posterior abdominal wall and the muscle defect was easily identified.

Tension-free mesh repair, performed openly or laparoscopically, has been accepted as the standard technique for most of abdominal wall hernias. The open procedure commonly requires a large incision and is associated with pain and a long convalescence period. Heniford et al.<sup>7</sup> published the first report of laparoscopic lumbar hernia repair in 1997. Whereas there is a paucity of studies of endoscopic treatment, the laparoscopic approach provides an excellent exposure and visualization of anatomical structures as well as definition of wall defects limits. Further, the transperitoneal laparoscopic approach may be advantageous over conventional surgery, as it is possible to avoid the dissection of tissue that was previously operated upon. This minimally invasive technique permits a safe fixation of the mesh on the wall, usually with titanium clips. In addition, it has been used as the standard treatment of incisional lumbar hernias.<sup>8</sup>

Shekarritz et al.<sup>9</sup> described three cases that were managed successfully by laparoscopic surgery. Moreno-Egea et al. conducted a prospective analytical study of 15 patients diagnosed with lumbar hernia who were treated with transabdominal laparoscopy. At 12-month follow-up, they found only one recurrence.<sup>10</sup> We chose a laparoscopic correction because the patient had a favorable anatomical conditions and, apart from the PRS, no previous abdominal surgery. The patient benefited from this technique, and we believe that the laparoscopic approach may be the best choice for the treatment of the rare lumbar hernia complication after PRS.

## REFERENCES

1. Michel M, Trojan L, Rassweiler J. Complications in percutaneous nephrolithotomy. *Eur Urol*. 2008;51:899-906, doi: 10.1016/j.eururo.2006.10.020.
2. Yavuz N, Ersoy YE, Demirkisen O, Tortum OB, Erguney S. Laparoscopic incisional lumbar hernia repair. *Hernia*. 2009;13:281-6, doi: 10.1007/s10029-009-0478-1.
3. Moreno-Egea A, Torralba-Martinez JA, Morales G, Fernandez T, Girela E, Aguayo-Albasini JL. Open vs laparoscopic repair of secondary lumbar hernias: a prospective nonrandomized study. *Surg Endosc*. 2005;19:184-97, doi: 10.1007/s00464-004-9067-7.
4. Le Neel JC, Sartre JY, Borde L, Guiberteau B, Bourseau JC. Lumbar hernias in adults. Apropos of 4 cases and review of literature. *J Chir*. 1993;130:397-402.
5. Kouba EJ, Hubbard JS, Wallen E, Pruthi RS. Incisional hernia in a 12-mm nonbladed trocar site following laparoscopic nephrectomy. *TheScientificWorldJOURNAL*. 2006;6:2399-402, doi: 10.1100/tsw.2006.372.
6. Killen KL, Girard S, DeMeo JH, Shanmuganathan K, Mirvis SE. Using CT to diagnose traumatic lumbar hernias. *AJR Am J Roentgenol*. 2000;174:1413-5.
7. Heniford BT, Iannitti DA, Gagner M. Laparoscopic inferior and superior lumbar hernia repair. *Arch Surg*. 1997;132:1141-4.
8. Tobias-Machado M, Rincon FJ, Lasmar MT, Zambon JP, Juliano RV, Wroclawski ER. Laparoscopic surgery for treatment of incisional lumbar hernia. *Int Braz J Urol*. 2005;31:309-14.
9. Shekarritz B, Graziottin TM, Gholami S, Lu HF, Yamada H, Duh QY, et al. Transperitoneal preperitoneal laparoscopic lumbar incisional herniorrhaphy. *J Urol*. 2001;166:1267-9, doi: 10.1016/S0022-5347(05)65750-3.
10. Moreno-Egea A, Guzmán P, Girela E, Corral M, Aguayo Albasini JL. Laparoscopic hernioplasty in secondary lumbar hernias. *J Laparoendosc Adv Surg Tech A*. 2006;16:572-6, doi: 10.1089/lap.2006.16.572.