

CLINICAL SCIENCE

Dental abnormalities and oral health in patients with Hypophosphatemic rickets

Melissa Almeida Souza, Luiz Alberto Valente Soares Junior, Marcela Alves dos Santos, Maria Helena Vaisbich

¹Pediatric Nephrology Unit, Instituto da Criança, Hospital das Clínicas, Faculdade de Medicina, Universidade de São Paulo, São Paulo, SP, Brazil. ²Dentistry Division, Instituto Central, Hospital das Clínicas, Faculdade de Medicina, Universidade de São Paulo, São Paulo, SP, Brazil.

INTRODUCTION: Hypophosphatemic rickets represents a group of heritable renal disorders of phosphate characterized by hypophosphatemia, normal or low serum 1,25 (OH)₂ vitamin D and calcium levels. Hypophosphatemia is associated to interglobular dentine and an enlarged pulp chambers.

AIM: Our goal was to verify the dental abnormalities and the oral health condition in these patients.

MATERIAL AND METHODS: Prospective study of oral conditions in patients with Hypophosphatemic rickets. This report employed a simple method to be easily reproducible: oral clinical exam and radiographic evaluation.

RESULTS: Fourteen patients were studied, 5 males, median age of 11years (4 to 26). Occlusion defects (85,7%) and enamel hypoplasia (57,1%) were significant more frequently than dental abscesses (one patient). We observed enlarged pulp chambers in 43% of the patients and hypoplasia and dentin abnormalities in 14,3%. We could not detect a significant correlation between dental abnormalities and delayed treatment ($p>0,05$). DMFT index for 6 to 12 years patients ($n = 12$) showed that the oral health is unsatisfactory (mean DMFT = 5).

CONCLUSIONS: Patients with Hypophosphatemic Rickets frequently present dental alterations and these are not completely recovered with the treatment, unless dental abscess and they need a periodical oral examination.

KEYWORDS: Hypophosphatemic rickets; Children; Dental abscess; Malocclusion; Dentin alterations.

Souza MA, Soares Junior LAV, Santos MA, Vaisbich MH. Dental abnormalities and oral health in patients with Hypophosphatemic rickets. Clinics. 2010;65(10):1023-1026.

Received for publication on May 25, 2010; First review completed on June 13, 2010; Accepted for publication on July 29, 2010

E-mail: vaisbich@terra.com.br

Tel.: 55 11 3884-2422

INTRODUCTION

Hypophosphatemic rickets represents a group of heritable disorders of phosphate renal regulation with very similar features and with three known forms of inheritance: autosomal dominant (ADHR), autosomal recessive (ARHR) and X-linked dominant (XLH), with the latter being the most common form. In all three types of hypophosphatemic rickets, an increased FGF23 activity has been demonstrated. FGF-23 inhibits renal phosphate resorption in the proximal tubule of the kidney by decreasing of the number of sodium-phosphate cotransporters (NPT2a). It also inhibits 1-alpha hydroxylase^{1,2} and, consequently, diminishes the production of 1,25-(OH)₂ vitamin D, thus reducing the intestinal absorption of phosphate and calcium. Patients can present osteomalacia or rickets,³ and the bone abnormalities are frequently restricted to the lower limbs and manifest clinically as pain while walking and skeletal deformities, with frequent *genu varum*. Inorganic phosphate (Pi) is

required for cellular functions and skeletal mineralization, and hypophosphatemia is associated with dysplastic, poorly mineralized dentin with areas of interglobular dentin (hypomineralization), and enlarged pulp chambers.⁴ Therefore, although the functional properties of odontoblasts are normal, dental and oral abnormalities can occur in these patients and have been observed more frequently in the primary dentition. Recurrent spontaneous abscess formation that affects multiple noncarious primary teeth is the principle clinical finding described in literature.⁵

Our goal was to verify the dental abnormalities and oral health condition in patients with hypophosphatemic rickets.

PATIENTS AND METHODS

We studied 20 patients (aged 0-18 years at diagnosis) with hypophosphatemic rickets who were followed at the Pediatric Nephrology Unit of Instituto da Criança – Hospital das Clínicas da Faculdade de Medicina da Universidade de São Paulo (HCFMUSP). The patients presented normal renal function (clearance of creatinine ≥ 90 ml/minute/1.73 m²). Only patients with good compliance were included in the study, and this assessment was based on the results of laboratory exams and adherence to the scheduled visits and exams. Patients with other renal or systemic diseases were excluded from the study.

This is an Open Access article distributed under the terms of the Creative Commons Attribution Non-Commercial License (<http://creativecommons.org/licenses/by-nc/3.0/>) which permits unrestricted non-commercial use, distribution, and reproduction in any medium, provided the original work is properly cited.

Clinical evaluations of the patients periodically, every 3 or 4 months, in which the patients were submitted to the following exams: serum phosphate and calcium measurements and intact parathyroid hormone (PTH), alkaline phosphatase and urinary calcium. Renal ultrasonography control was performed annually to check for nephrocalcinosis. Other exams were conducted when necessary. The patients received the conventional treatment based on phosphate and 1,25-(OH)₂ vitamin D supplementation.

Stature was evaluated each attendance, and the mean deviation score (z-score) for height calculated according to a standard method.⁶

In this study, we employed a stature z-score $\leq -1,9$ as a marker of delayed treatment or poor compliance based on previous reports from others and our group demonstrating the correlation between a higher stature z-score and early and adequate treatment.^{7,8,9,10}

Oral Examination

Oral examinations were performed at the Dentistry Division of HC-FMUSP. For each patient, we performed an anamnesis and an interview consisting of identification data, age, medical history including main complaints, presence of other diseases, familial history and treatment administered, dental history and oral hygiene. The same dentist carried out the oral examinations in all patients to assess the teeth, gingival tissue, mucosa, tongue, and hard and smooth palate.

We adopted the following parameters of the World Health Organization Oral Health Survey Basic Methods to evaluate oral health status.¹¹

- decayed, missing and filled tooth (dmft) index for primary (0–5 years) and early mixed dentition (6–19 years), and
- Decayed, Missing and Filled Tooth (DMFT) index for late mixed dentition (11–15 years).

The results were compared with the findings obtained for the Brazilian general population.¹²

The patients were also submitted to a radiological exam (panoramic X-ray or orthopantomographic X-ray) that was interpreted by the same radiologist, who evaluated the pulp chamber, root canals, dental abscesses, dental agenesis, dental morphology, dental caries and areas of infection.

Statistical Analysis

Data are presented as the mean \pm standard deviation for normally distributed data and as the median and range for non-normally distributed data. The chi-square test was used to analyze categorical data, and the correlations were tested using Pearson's correlation coefficients. A p value <0.05 was considered significant.

The Local Ethics Committee approved the protocol.

RESULTS

Fourteen of 20 patients were included in this study: five males and 9 females, aged 4 to 26 years, with a median age of 11 years. Six patients were excluded from the study because they did not fulfill the inclusion criteria for adherence. The diagnosis was established prior to 4 years of age in seven patients (50%). All of the patients were taking phosphate supplementation (20 to 90 mg/kg/day)

Table 1 – Clinical findings in 14 patients with hypophosphatemic rickets.

Clinical findings	Number of patients	%
Enamel hypoplasia	8	57.1
Occlusion defects	12	85.7
Dental abscess	1	7.1

and calcitriol ($0,03 \pm 0,01 \mu\text{g/kg/day}$), and some of the patients with a tendency to develop hypercalciuria were receiving potassium citrate to prevent nephrocalcinosis or to avoid its progression, with urinary pH control.

Oral examination

At the time of the study, six patients presented with permanent dentition, 6 patients with mixed dentition and 2 patients with deciduous teeth.

The observed tooth abnormalities are shown in Table 1. As can be observed, occlusion defects and enamel hypoplasia were significantly more frequent than dental abscesses.

The occlusion defects included an open bite in four patients, an end-to-end rim or occlusion in 2 patients, a cross-bite in 1 patient, an ogival palate in 1 patient and 4 patients were under orthodontic treatment.

Figure 1 shows the dental clinical of a patient with hypophosphatemic rickets.

Radiological findings

Table 2 shows the radiological findings in patients with hypophosphatemic rickets. Enlarged pulp chambers were found in 43% of the patients; however, hypoplasia and dentin abnormalities were also observed.

Figure 2 shows the radiological findings of one patient, emphasizing the enlarged pulp chamber.

We were unable to detect a significant correlation between the presence of dental abnormalities (radiographic abnormalities, hypoplasia and malocclusion) and delayed treatment or poor compliance (stature z-score $\leq -1,9$) ($p > 0,05$).

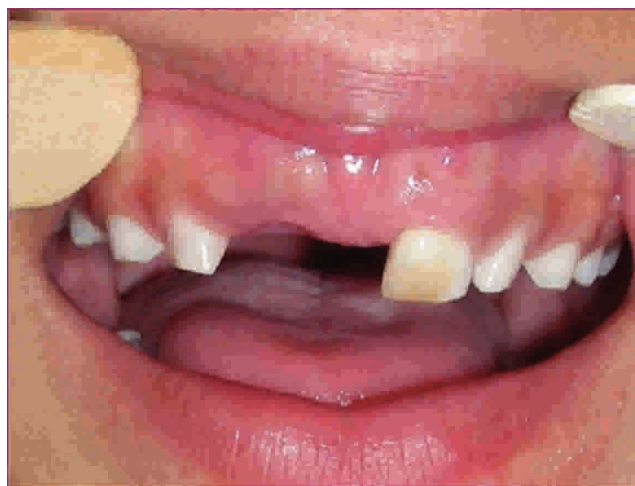

Figure 1 - Clinical aspect of patient with Hypophosphatemic Rickets.

Table 2 – Radiological findings in patients with hypophosphatemic rickets.

Radiographic findings	Number of patients	%
Enlarged pulp chambers	6	42.8
Hypoplasia	2	14.3
Dentin alterations (hypomineralization)	2	14.3

Oral health status

The oral health status of the patients with primary dentition was insufficient for evaluation, because in the present series, this group comprised only two patients, both of whom presented a **dmft** index = 0. The **DMFT** index of the 6 to 12-year-old patients (12 patients) showed that oral health in this group was unsatisfactory (mean **DMFT** = 5) compared to the Brazilian general population (mean **DMFT** = 1,57).

DISCUSSION

Inorganic phosphate plays a major role in many biological systems, including cell membrane functions, energy metabolism, cell signaling, and oxygen transport. In hypophosphatemic rickets, renal proximal tubular resorption is compromised, and the patient presents with hypophosphatemia along with a relative 1,25-(OH)₂ vitamin D deficiency. Patients with hypophosphatemic rickets often exhibit high pulp horns, large pulp chambers, and dentinal clefts.

Malocclusion associated with hypophosphatemic rickets has not been frequently reported. However, impressive results were obtained herein (12/14 cases). An open bite was the most frequent abnormality detected and can be explained by the delay in maxillary growth in relation to the growth of the mandible (Angle class II).¹⁹ Although taurodontism has been reported in the literature, no cases presented with an abnormality in dental morphology in the present study.^{20,21}

The management of these cases remains controversial. Some authors advocate extraction of the teeth that present

periradicular abscesses and eventual restoration with implants. However, endodontic and restorative treatments may not be capable of maintaining asepsis.^{22,23} Dental abscesses are the most frequently reported complication in the literature.¹³ Histologically, the teeth exhibit enlarged pulp chambers, wide predentin zone, marked globular dentin and tubular dentin defects that extend from the pulp to the enamel. Enamel hypoplasia may or may not be present.¹⁴ Most of the analyzed primary incisors displayed fissures that linked the enamel subsurface to the pulp horn. Abe et al (1988) have suggested that the globular dentin caused by hypophosphatemia impairs calcification.¹⁵ The incompletely mineralized dentin exists in the form of calcospherites, which trap microorganisms and impair mechanical endodontic cleaning. These elements may explain the presence of bacteria and dental abscesses. Because enamel and dentin formation occur between 4 months *in utero* and 11 months of age, defects in the primary dentition usually cannot be prevented. According to Hillmann and Geurtsen,¹⁶ the permanent teeth might also be affected by this mechanism, and histopathological examination of the permanent dentition is necessary.

Chaussain-Miller et al (2007) studied seven patients aged 3 to 16 years and observed that untreated or inadequately treated patients had necrotic teeth with impaired dentin mineralization.¹⁷ They concluded that adequate treatment ensures healthy dentin development and mineralization and prevents dental necrosis. This proposition could explain our low rate of dental abscesses, because the patients included is the present study were relatively well treated (50% of the patients started treatment before 4 years of age and appeared to adhere to the treatment).

Typically, the younger the patient when the first abscess appears, the more severe is the dental manifestation.¹⁸ However, permanent teeth form after birth, and their development could potentially be improved by the initiation of medication soon after birth.¹⁶

The occurrence of spontaneous abscesses following a shallow cavity preparation requires aggressive preventive dental procedures.²⁴ In this sense, professional dental care consisting of periodic examinations, topical fluoride applications and maintenance of good oral hygiene is imperative.²⁵

Pit and fissure sealants are useful when the teeth are erupting, as they prevent the ingress of bacteria into enamel microfractures and the initiation of caries in deep pits and fissures. Few studies have evaluated oral health in patients with hypophosphatemic rickets. Baroncelli et al studied nine children and observed that **d/D** ranged from 0 to 9 and **f/F** from 0 to 3. The **dfmt** index was 0 in the three youngest patients.²⁶ Their findings are similar to ours and demonstrate that oral health in older patients is unsatisfactory compared to that in younger patients and in the healthy population.

In the present study, we evaluated the oral status of patients with hypophosphatemic rickets using a simple, reproducible method: a clinical and radiographic exam. Exams that are more detailed would be useful, but in most situations, such tests are not available. We conclude that patients with hypophosphatemic rickets can frequently present dental abnormalities that are incompletely reversed with treatment. However, early treatment could probably avoid dental abscess formation. Moreover, dentists and pediatricians should be aware of the features of this

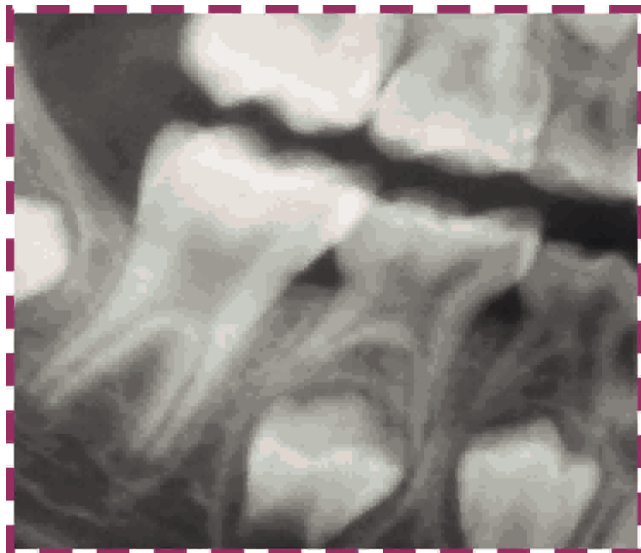


Figure 2 - Radiological aspect - patient with Hypophosphatemic Rickets.

disorder, because early intervention could prevent subsequent serious and more invasive dental procedures. Patients with hypophosphatemic rickets require periodic oral examinations; the dental care of these patients should consist of topical fluoride applications, pit and fissure sealants and maintenance of good oral hygiene.

REFERENCE

1. Bowe AE, Finnegan R, Beur SMJ, Cho J, Levine MA, Kumar R, et al. FGF-23 inhibits renal tubular phosphate transport and is a PHEX substrate. *Biochem Biophys Res Commun*. 2001;284:977-81, doi: 10.1006/bbrc.2001.5084.
2. Quarles LD. FGF-23, PHEX and MEPE regulation of phosphate homeostasis and skeletal mineralization. *Am J Physiol Endocrinol Metab*. 2003;285:E1-E9.
3. Tenenhouse HS, Murer H. Disorders of renal tubular phosphate transport. *J Am Soc Nephrol*. 2003;14:240-7, doi: 10.1097/01.ASN.0000045045.47494.71.
4. Batra P, Tejani Z, Mars M. X-linked hypophosphatemia: dental and histologic findings. *J Can Dent Assoc*. 2006;72:69-72.
5. Goodman JR, Gelbier MJ, Bennet JH, Winter GB. Dental problems associated with hypophosphatemic vitamin D resistant rickets. *International J Pediatr Dent*. 1998;8:19-28, doi: 10.1046/j.1365-263X.1998.00059.x.
6. Cameron N. The methods of auxological anthropometry. In: Falkner F, Tanner JM. Editors. *Human Growth*. Vol 2, Post Natal Growth. New York: Plenum Press, 1978.p 35.
7. Vaisbich MH, Koch VH. Hypophosphatemic rickets: results of a long-term follow-up. *Pediatr Nephrol*. 2006;21:230-4, doi: 10.1007/s00467-005-2077-4.
8. Kooh SW, Binet A, Daneman A. Nephrocalcinosis in X-linked hypophosphatemic rickets: its relationship to treatment, kidney function and growth. *Clin Invest Med*. 1994;17:123-30.
9. Friedman NE, Lobaugh B, Drezner MK. Effects of calcitriol and phosphorus therapy on the growth of patients with X-linked hypophosphatemia. *J Clin Endocrinol Metab*. 1993;76:839-44, doi: 10.1210/jc.76.4.839.
10. Doria A, Kooh SW, Cole WG, Daneman A, Sochett E. Early treatment improves growth and biochemical and radiographic outcome in X-linked hypophosphatemic rickets. *J Clin Endocrinol Metab*. 2003;88:3591-7, doi: 10.1210/jc.2003-030036.
11. World Health Organization. *Oral Health Surveys-Basic Methods*. 4. Ed. Geneva; 1997.
12. Brazilian Health Minister, 2003. Ministério da Saúde. *Condição de saúde bucal da população brasileira 2002-2003*. Brasília DF, 2004. Site: www.saude.gov.br.
13. Murayama T, Iwatsubo R, Akiyama S, Amano A, Morisaki I. Familial hypophosphatemic vitamin D-resistant rickets: dental findings and histologic study of teeth. *Oral Surgery Oral Medicine Oral Pathology*. 2000;90:310-6.
14. Seeto E, Seow WK. Scanning electron microscopic analysis of dentin in vitamin D-resistant rickets: assessment of mineralization and correlation with clinical findings. *Pediatr Dent*. 1991;13:43-8.
15. Abe K, Ooshima T, Lily TS, Yasufuku Y, Sobue S. Structural deformities of deciduous teeth in patients with hypophosphatemic vitamin-D resistant rickets. *Oral Surg Oral Med Oral Pathol*. 1988; 65:191-8, doi: 10.1016/0030-4220(88)90165-X.
16. Hillmann G, Geurtsen W. Pathohistology of undercalcified primary teeth in vitamin D-resistant rickets: review and report of two cases. *Oral Surg Oral Med Oral Pathol Oral Radiol Endod*. 1996;82:218-24, doi: 10.1016/S1079-2104(96)80260-5.
17. Chaussain-Miller C, Sinding C, Septier D, Wolikow M, Goldberg M, Garabedian M. Dentin structure in familial hypophosphatemic rickets: benefits of vitamin D and phosphate treatment. *Oral Dis*. 2007; 13:482-9, doi: 10.1111/j.1601-0825.2006.01326.x.
18. Seow WK, Romanink K, Sclavos S. Micromorphologic features of dentin in vitamin D-resistant rickets: correlation with clinical grading of severity. *Pediatr Dent*. 1989;11:203-8.
19. Kawakami M, Yamamoto TT. Orthodontic treatment of a patient with hypophosphatemic vitamin D-resistant rickets. *J Dent Child*. 1997; 64:395-9.
20. Seow WK, Latham SC. The spectrum of dental manifestations in vitamin D resistant rickets: implications for management. *Pediatr Dent*. 1986;8:245-50.
21. Seow WK, Needleman HL, Holm IA. Effect of familial hypophosphatemic rickets on dental development: a controlled, longitudinal study. *Pediatr Dent*. 1995;17:346-50.
22. Pereira CM, de Andrade CR, Vargas PA, Coletta RD, de Almeida OP, Lopes MA. Dental alterations associated with X-linked hypophosphatemic rickets. *J Endod*. 2004;30:241-5.
23. Tulloch EN, Andrews FF. The association of dental abscesses with vitamin D-resistant rickets. *Br Dent J*. 1983;154:136-8, doi: 10.1038/sj.bdj.4805012.
24. Herbert FL. Hereditary hypophosphatemia rickets: an important awareness for dentists. *ASDC J Dent Child*. 1986;53:223-6.
25. Cohen S, Becker GL. Origin, diagnosis, and treatment of the dental manifestations of vitamin D-resistant rickets: a review of the literature and report of a case. *J Am Dent Assoc*. 1976;92:120-9.
26. Baroncelli GI, Angiolini M, Ninni E, Galli V, Saggese R, Giuca MR. Prevalence and pathogenesis of dental and periodontal lesions in children with X-linked hypophosphatemic rickets. *Eur J Paediatr Dent*. 2006;7:61-66.