
LETTER TO THE EDITOR

ECHOGUIDED HEPATICO-GASTROSTOMY: A CASE REPORT

Everson L.A. Artifon, Dalton M. Chaves, Shinichi Ishioka, Thiago F. Souza, Sérgio E. Matuguma, Paulo Sakai

INTRODUCTION

Endoscopic retrograde cholangiopancreatography (ERCP) with biliary drainage has become the gold standard procedure for decompression of obstructed biliary ducts.^{1,2} Skilled endoscopists are expected to achieve successful drainage in 90% to 95% of cases.³ However, anatomic variation, such as perihilar diverticulum, tumor invasion and surgical diversions are all situations that may result in failure.^{4,5} In cases where such failure occurs, available options include repeat ERCP at a tertiary care center,⁶ percutaneous transhepatic drainage (PTD),^{7,8} and surgery.⁹ PTC has complication rate of up to 32%, with possible fistula formation, cholangitis, peritonitis, empyema, hematoma, and liver abscesses.^{10,11} Surgery, although definitive, is associated with increased morbidity and mortality.¹² The echoguided hepatico-gastrostomy technique was first described in 2003 by Giovannini et al.¹³ and may be seen as a variation of the intrahepatic approach, but without selective drainage through the ampulla.

In terms of a minimally invasive concept and low complication rate, this is the first presentation of hepatico-gastrostomy drainage using both endoscopic ultrasound and fluoroscopy guidance performed at the Gastrointestinal Endoscopy Unit in the Hospital das Clínicas – University of São Paulo School of Medicine.

PATIENT AND METHOD**Preparation**

The patient was placed in a supine decubitus position, and 10% lidocaine solution was sprayed into the pharynx for local anesthesia. An adequate level of sedation was managed by an anesthesiologist, who administered intravenous midazolam and/or propofol.

Serviço de Endoscopia Digestiva do Hospital das Clínicas da Faculdade de Medicina da Universidade de São Paulo, São Paulo, SP-Brazil
Email: eartifon@hotmail.com

Case report

An 82-year-old man presented with a history of discomfort in the right upper quadrant of the abdomen, weight loss and jaundice in the last 2 months. Laboratory data showed abnormal liver functions with serum bilirubin of 31mg/dl. US and CT scan showed a large hilar solid mass, with dilated intrahepatic bile ducts and portal vein invasion. ERCP showed an irregular stop at common hepatic duct and the guide wire attempts to pass through the hilar stenosis did not have success. The patient was judged to have an inoperable locally advanced hilar cancer and indicated for a non-surgical palliative drainage by means of echoguided hepatico-gastrostomy assisted with fluoroscopy.

Technique

The procedure was performed using a linear array echoendoscope with a working channel with 3.8mm (GF-UCT-160, Olympus – Mellville – NY, USA). This instrument is coupled with an ultrasound processor machine. A 19 – gauge needle (EUSN-19T, Wilson-Cook, Winston Salem, NC) was used. Although correct orientation of the 19-gauge needle is more challenging than the 22-gauge, it permits easy passage of a 0.035 – inch guidewire.

The fistula between the gastrointestinal tract and the intrahepatic biliary tree can be enlarged using either a 4 or 6mm wire-guided balloon catheter (Max Force, microvasive); 6 or 7 French bougie (SBDC-6 or 7, Wilson Cook), or passage of the covered biliary metallic stent (Wallstent 60 / 100mm, Boston Scientific) directly through the gastric fistula as done in the present case.

EUS exam was performed to find an appropriate sonographic window around the cardia, in order to have the best position to insert the gauge 19-T needle transgastrically into the distal part of the left hepatic duct, followed by the Doppler analysis of intra-hepatic structures (figure 1 and 2) and contrast medium was injected after previous bile aspiration, then an intrahepatic cholangiogram

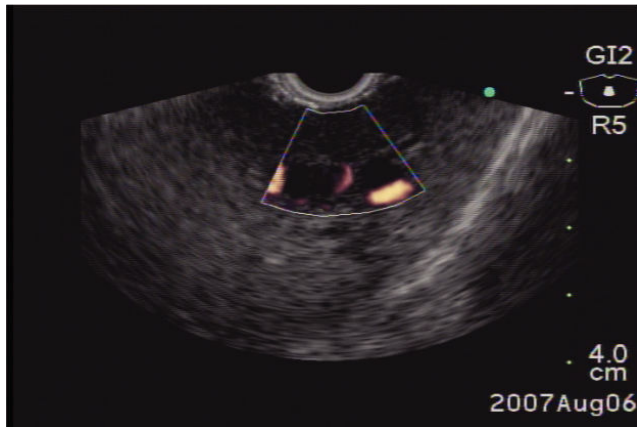


Figure 1 – EUS color Flow Doppler before performing an intrahepatic approach.

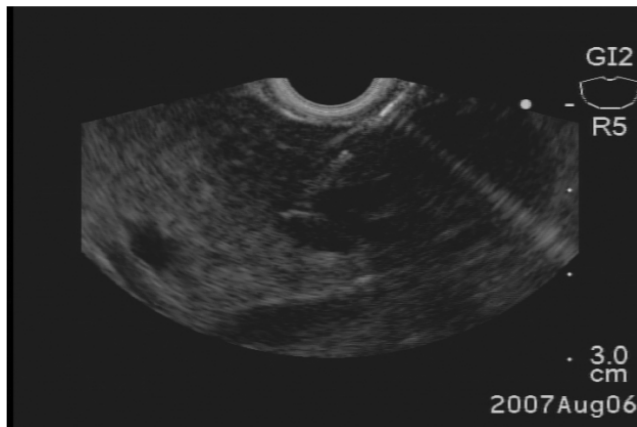


Figure 2 – EUS image demonstrating a 19 – gauge needle puncturing the left hepatic biliary branch under endosonography, intrahepatic approach.

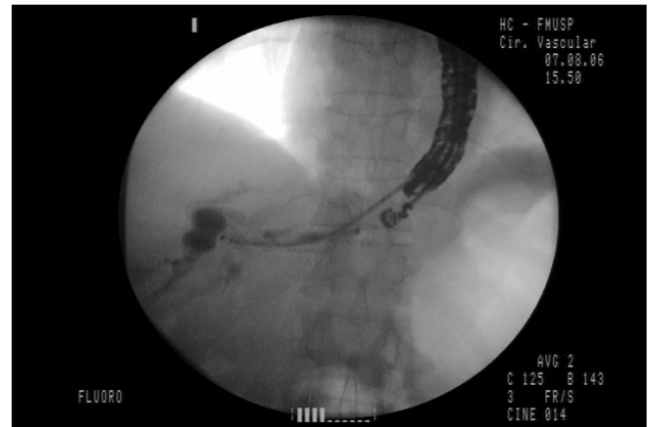


Figure 3 – Fluoroscopic image demonstrating intrahepatic cholangiogram after contrast media injection under EUS guidance

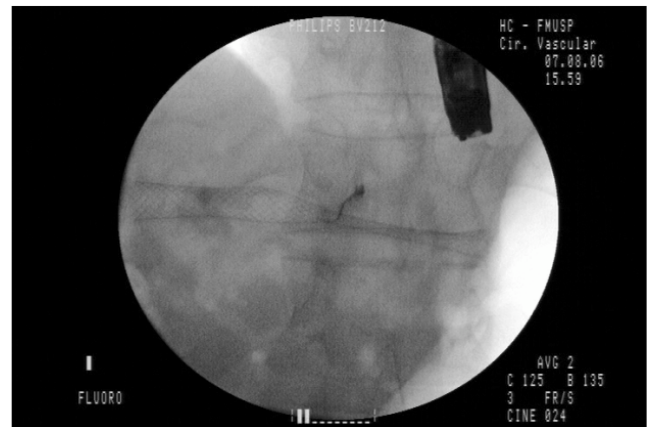


Figure 4a – Fluoroscopy image demonstrating the metallic stent opened.

was obtained (figure 3). An important technique detail is to adequate the tip of the needle into the dilated intrahepatic duct punctured synchronized with diaphragm breath movements. The needle is exchanged for a guidewire and the image was controlled by both EUS and fluoroscopy guidance. A flexible metallic stent was passed over the guide through gastric fistula to the left intra-hepatic duct without any dilation procedure. The deployment of metallic stent occurred successfully and bile flow to stomach demonstrated the method's effectiveness. However as the patient has an esophageal-gastric hernia, the gastric opening of metallic stent occurred in the cardia, very close to the esophageal-gastric junction (figure 4). Up to the 8th follow up day, the patient did not present abdominal pain, his liver enzymes and bilirubin decreased significantly and his conventional abdominal US was normal with no bile leakage. At the 30th follow-up day, the patient did not present jaundice and a normal conventional US was obtained. The patient presented an uneventful recovery.

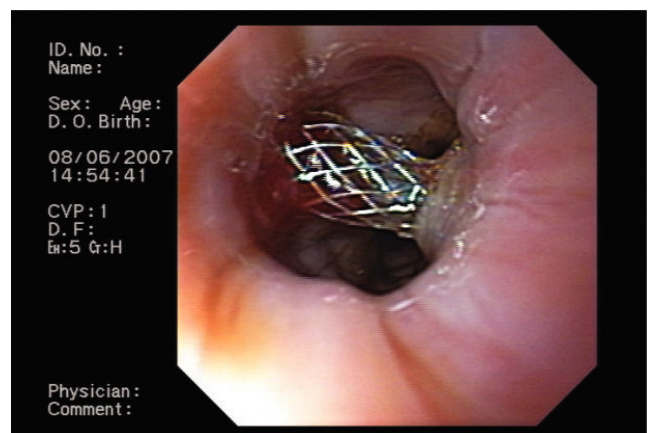


Figure 4b – Endoscopic view of the metallic stent opened in the cardia.

DISCUSSION

Burmester et al.¹⁴ attempted ecoguided hepato-gastrostomy (EH) in four cases, with the successful place-

ment of 8.5 French stents in three and with one bile leak as a complication. In two cases, Mallery et al.¹⁵ performed EH by cannulation adjacent to a EUS-placed wire, with a minor complication of wire passage outside the bile duct lumen. Puspok et al.¹⁶ reported successful (lower than 100%) EH with no immediate complications. Another bile leak was reported by Bories and Will et al.^{17,18} in a case of malignant biliary obstruction treated with EUS-guided hepaticogastrostomy followed by the deployment of a covered Wallstent, similar to the one used in the present case.

One could argue about alkaline gastritis due to bile in the gastric mucosa but these patients have poor survival and the quality of life comes to be the most important factor among many clinical features raised in the palliative method used in patients with advanced biliary cancer.

The overall reported success rate of EH was 89% with an overall complication rate of 18% that included three major complications (bile leak in 8%).¹⁶

Technical problems encountered by the endoscopist are similar to those encountered via the percutaneous route. These include difficulties associated with advancement of the guide wire through tortuous ducts and high-grade ob-

structions requiring judicious use of bougies and other dilator catheters.^{2,16}

Advantages of EH over percutaneous transhepatic drainage include puncture of the biliary tree with real-time ultrasound guidance using color Doppler information, thus avoiding the possibility of vascular injury. In addition, ascites is not seen in the interventional field when present in the peritoneum. Finally, with EH there is no need for an external drain and simultaneous staging of the tumor is possible. The limitation of EH is that access to the right hepatic ductal system generally does not permit advancement of the guidewire into the distal common bile duct.^{3,14,15}

In conclusion, EH has been shown to have high efficacy with an acceptable complication rate. Consequently, EH has become a credible alternative to the palliative biliary internal drainage at tertiary care centers. Improvement in the design of available large-channel echoendoscopes, as well as devices that permit the performance of one-step procedures, will probably improve the safety of the procedure, and lead to wider use. However, multicenter studies comparing EH with PTC are needed to further define the utility and indications of this technique.

REFERENCES

1. Fogel EL, Sherman S, Devereaux BM, Lehman GA. Therapeutic biliary endoscopy. *Endoscopy*. 2001;33:31-38.
2. Carr-Locke DL. Overview of the role of ERCP in the management of diseases of the biliary tract and the pancreas. *Gastrointest Endosc*. 2002;56:S157-S160(suppl).
3. Huibregtse K, Kimmey MB. Endoscopic retrograde cholangiopancreatography, endoscopic sphincterotomy and endoscopic biliary and pancreatic drainage, in Yamada T (ed): *Textbook of Gastroenterology*. Philadelphia, PA, J.B. Lippincott, 1995, pp 2590-2617.
4. Lobo DN, Balfour TW, Lftkhar SY. Periampullary diverticula: consequences of failed ERCP. *Ann R Coll Surg Engl*. 1998;80:326-331.
5. Wright BE, Cass OW, Freeman ML. ERCP in patients with long-limb Roux-en-Y gastrojejunostomy and intact papilla. *Gastrointest Endosc*. 2002;56:225-232.
6. Choudari CP, Sherman S, Fogel EL, Phillips S, Kochell A, Flueckiger J, et al. Success of ERCP at a referral center after a previously unsuccessful attempt. *Gastrointest Endosc*. 2000;52:478-483.
7. Ferrucci JT Jr, Mueller PR, Harbin WP. Percutaneous transhepatic biliary drainage: technique, results, and applications. *Radiology*. 1980;135:1-13.
8. Harbin WP, Mueller PR, Ferrucci JT Jr. Transhepatic cholangiography: complications and use patterns of the fine-needle technique – a multiinstitutional survey. *Radiology*. 1980;135:15-20.
9. Smith AC, Dowsett JF, Russel RC, Hatfield AR, Cotton PB. Randomised trial of endoscopic stenting versus surgical bypass in malignant low bile duct obstruction. *Lancet*. 1994;344:1655-1660.
10. Lameris JS, Stoker J, Nijs HG, Zonderland HM, Terpstra OT, van Blankenstein M, et al. Malignant biliary obstruction: percutaneous use of self-expandable stents. *Radiology*. 1991;179:703-707.
11. Beissert M, Wittenberg G, Sandstede J, Beer M, Tschammler A, Burghardt W, et al. Metallic stents and plastic endoprotheses in percutaneous treatment of biliary obstruction. *Z Gastroenterol*. 2002;40:503-510.
12. Kama NA, Coskun T, Yuksek YN, Doganay M, Reis E, Akat AZ. Factors affecting post-operative mortality in malignant biliary tract obstruction. *Hepatogastroenterology*. 1999;46:103-107.

13. Giovannini M, Dotti M, Bories E, Moutardier V, Pesenti C, Danisi C, et al. Hepaticogastrostomy by echoendoscopy as a palliative treatment in a patient with metastatic biliary obstruction. *Endoscopy*. 2003;35:1076-1078.
14. Burmester E, Niehaus J, Leineweber T, Huetteroth T. EUS-cholangio-drainage of the bile duct: report of 4 cases. *Gastrointest Endosc*. 2003;57:246-250.
15. Mallery S, Matlock J, Freeman ML. EUS-guided rendezvous drainage of obstructed biliary and pancreatic ducts: report of 6 cases. *Gastrointest Endosc*. 2004;59:100-107.
16. Puspok A. Biliary therapy: are we ready for EUS-guidance? *Minerva medica*. 2007;98:379.
17. Bories E, Pesenti C, Caillol F, Lopes C, Giovannini M. Transgastric endoscopic ultrasonography-guided biliary drainage: results of a pilot study. *Endoscopy*. 2007;39:287-91.
18. Will U, Thieme A, Fuedner F, Gerlach R, Wanzar I, Meyer F. Treatment of biliary obstruction in selected patients by endoscopic ultrasonography (EUS)-guided transluminal biliary drainage. *Endoscopy*. 2007;39:292-96.