

## LETTER TO THE EDITOR

## HENOCH-SCHÖNLEIN PURPURA IN ADULTS

María José López Meiller, Javier Alberto Cavallasca, María del Rosario Maliandi, Gustavo Guillermo Nasswetter

## INTRODUCTION

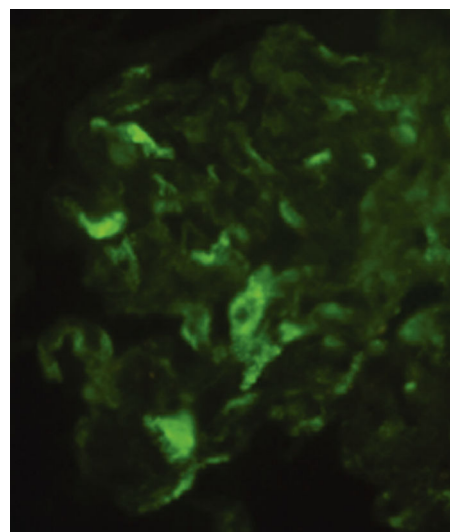
Henoch-Schönlein Purpura (HSP) is a systemic vasculitis mediated by IgA and characterized by the clinical triad of non-thrombocytopenic palpable purpura, abdominal pain, and arthritis. In addition, there may be varying degrees of renal involvement. It is the most frequent vasculitis in children and the incidence in adults varies from 3.4 to 14.3 cases per million, depending upon the experimental series analyzed.<sup>1</sup>

We report the onset, course and response to treatment of five adult patients who required hospitalization at our institution between 2002 and 2006 (all fulfilled the 1990 American College of Rheumatology (ACR) criteria).<sup>2</sup>

**Case 1:** A 24-year-old white male with frequent episodes of pharyngitis was admitted for an eight day course of palpable purpuric lesions on his lower limbs, arthritis in both ankles, and diffuse abdominal pain. A complete blood count with differential analysis, liver function test, coagulation test, chemistry panel, and ERS were normal. A urinary sediment showed dysmorphic hematuria with 30 to 40 red blood cells/high power field and proteinuria of 2.29 g / 24 hr. A skin biopsy of the lower limbs showed leukocytoclastic vasculitis. IgA and C3 deposits were observed upon immunofluorescent assay. The renal biopsy indicated mesangial nephropathy due to IgA deposition (Figure 1).

The patient began treatment with IV methylprednisolone, 1 g/day for 3 days, and continued with oral prednisone, 40 mg/day. During treatment, the patient presented an increase in proteinuria (3.12 g/day), the persistence of dysmorphic hematuria, and developed hypertension. He was therefore treated with IV cyclophosphamide, 1g/m<sup>2</sup>/month for six months, and enalapril, 10 mg/day. Both blood and urine laboratory parameters stabilized after the first pulse of cyclophosphamide.

**Case 2:** A 68-year-old white male with a clinical background of cigarette smoking, arterial hypertension, insulin-



**Figure 1** - Renal biopsy with mesangial IgA deposition (immunofluorescence, 200X)

dependent diabetes mellitus, and chronic kidney failure under hemodialysis treatment was admitted for a four day long bout of diarrhea and diffuse abdominal pain, followed by the appearance of palpable purpuric lesions on the lower limbs two days prior to consultation. The laboratory results of the patient on admission showed the following: hematocrit 21%; hemoglobin 6.8 mg/dL; leukocyte count 17,500/mm<sup>3</sup> (neutrophils 86%, lymphocytes 8%); platelet count 460,000/mm<sup>3</sup>; ERS 77 mm/hour; glycemia 98 mg/dL; serum urea nitrogen 99 mg/dL (normal range 15 – 50 mg/dL); creatinine 5.3 mg/dL (normal range 0.6 – 1.3 mg/dL); and normal liver and coagulation studies. A skin biopsy of the lower limb lesions was performed and showed leukocytoclastic vasculitis with IgA and C3 deposition. The patient's follow-up was favorable, with spontaneous resolution of the cutaneous lesions and disappearance of the abdominal symptoms. Therefore, he did not require treatment.

**Case 3:** A 77-year-old white male with a clinical history of cigarette smoking, myocardial infarction and aortic valve replacement (due to severe stenosis) anticoagulated with coumarin began experiencing episodes of non-bloody diarrhea associated with diffuse abdominal pain 40 days prior to

Division of Rheumatology, Hospital de Clínicas José de San Martín, Faculty of Medicine, University of Buenos Aires - Buenos Aires - Argentina.  
majocontact@yahoo.com.ar

This is an Open Access article distributed under the terms of the Creative Commons Attribution Non-Commercial License (<http://creativecommons.org/licenses/by-nc/3.0/>) which permits unrestricted noncommercial use, distribution, and reproduction in any medium, provided the original work is properly cited.

consultation. Later on, palpable purpuric lesions appeared on all four limbs and trunk. Laboratory tests showed the following: hemoglobin 12.4 mg/dL; leukocyte count 9,900/mm<sup>3</sup> (neutrophils 68%, lymphocytes 23%); platelet count 120,000/mm<sup>3</sup>; serum nitrogen urea 120 mg/dL (normal range 15 – 50 mg/dL); creatinine 2.4 mg/dL (normal range 0.6 – 1.3 mg/dL); ERS 83 mm/hour; and IgA plasma dosage 514 mg/dL (normal range 95 – 283 mg/dL).

A urinary sediment showed dysmorphic hematuria, but no evidence of proteinuria. A stool sample showed no inflammatory reaction, and the stool culture was negative. A biopsy of the lower limb skin lesions reported leukocytoclastic vasculitis. Due to the risk of suspending anticoagulant treatment, a renal biopsy was not performed. Empirical treatment was initiated with IV methylprednisolone, 1 g IV for three days, then continued with oral meprednisone at a dose of 60 mg/day (which was later tapered) and monthly pulses of IV cyclophosphamide (a total of six pulses). The patient presented an improvement in renal function and disappearance of hematuria after the first pulse of cyclophosphamide.

**Case 4:** A 68-year-old white male with a clinical history of cigarette smoking, had a fever and palpable purpuric lesions on all four limbs 15 days prior to admission (Figure 2). Later, he presented colicky abdominal pain, predominantly in the hypogastrium, and two episodes of melena.

Laboratory results showed the following: ERS 85 mm/hour, and a urinary sediment presented 30 – 40 red blood cells/high power field (90% dysmorphic), protein + +, granular, cell and mixed casts, and proteinuria 2.4 g/ 24 hr. Test results were negative for antinuclear antibodies, ANCA, rheumatoid factor (RF), cryoglobulins, HBsAg and HCV serology. His serum complement levels (C3-C4) were normal. A biopsy of the skin was performed; immunofluorescence for IgA, IgG, and C3 were negative. A renal biopsy showed mesangial glomerulopathy by IgA deposits.

The patient presented a favorable clinical response as well as an improvement in the laboratory parameters with

oral meprednisone, 80 mg/day. The condition did not recur during or after corticosteroid tapering.

**Case 5:** A 64-year-old white female was admitted with palpable purpuric lesions on the lower limbs which appeared 24 hr prior to consultation. The lesions then extended to the upper limbs and trunk, in addition to palmar and plantar edema and arthralgias.

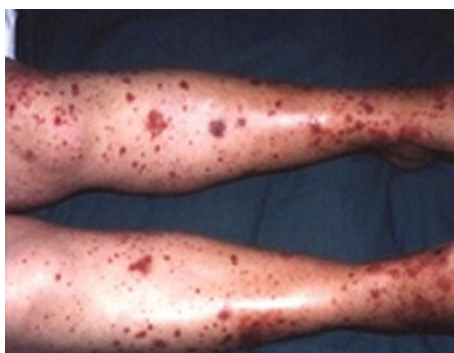The patient had suffered an upper respiratory tract infection with spontaneous resolution one week prior to admission. The indices of renal, liver, and coagulation function were normal. Immunologic tests showed the following: ANA (HEp-2) + 1/40 homogenous pattern, anti-dsDNA (-), ANCA (-) and normal serum complement levels. A urinary sediment analysis showed the following: protein (4+), leukocytes 10, 40 dysmorphic red blood cells/high power field, fatty oval bodies, granular, and white blood cell casts. A biopsy of the skin of the right thigh showed leukocytoclastic vasculitis and immunofluorescence IgA was positive. A renal biopsy showed mesangial nephropathy with IgA deposition. The patient developed arterial hypertension that was difficult to control, oliguria, and a deterioration of renal function. Therefore, the patient started treatment with IV methylprednisone, 3 g (1 g/day for 3 days), and then meprednisone, 1 mg/kg/day and IV cyclophosphamide, 1 g/m<sup>2</sup> (6 pulses monthly). Clinical response, kidney function, and urinary sediment analysis were favorable.

## DISCUSSION

HSP is a systemic small vessel vasculitis characterized by the deposition of IgA complexes in tissues. It generally has a self-limited course, and its main clinical manifestations can be seen in skin, joints, the gastrointestinal tract, and the kidneys. Less frequently, other organs and/or systems, such as the lungs, the central nervous system (CNS) and the genito-urinary tract, can be affected.<sup>3</sup>

Though the etiology of the disease is unknown, multiple infectious agents have been suggested to be responsible.<sup>4</sup> In adults (as opposed to children), renal involvement and the possibility of progression to kidney failure are greater. The prevalence is greater in males.<sup>5</sup>

Only two of our patients presented joint involvement, which corresponds to data published from other series.<sup>6</sup> In addition, four of them had nephropathy (Table 1). Our patients with renal involvement presented with dysmorphic hematuria and non-nephrotic range proteinuria in three cases. Serum creatinine levels were high in two of the patients. Kidney involvement usually determines the prognosis;<sup>7</sup> although the most frequent histological finding is mesangial proliferation,<sup>8</sup> lesions range from minimal change to severe



**Figure 2** - Palpable purpuric lesions on the lower limbs

**Table 1** - Clinical manifestations of five adults with Henoch-Schönlein Purpura

Clinical manifestations	Number of cases
Palpable purpura	5 (100%)
Joint manifestations	2 (40%)
Renal manifestations	
Hematuria	4 (80%)
Proteinuria	3 (60%)
Renal insufficiency	2 (1 previous) (40%)
Gastrointestinal Manifestations	
Bowel angina	4 (80%)
Gastrointestinal bleeding	1 (20%)

crescentic glomerulonephritis.<sup>9</sup> A significant number of patients (up to 36%) in some series may suffer permanent renal damage.<sup>10</sup>

The following predictors of a poor renal course in adults

have been proposed: high creatinine levels at onset, proteinuria greater than 1 g/day, arterial hypertension, increase of proteinuria during follow-up, extracapillary proliferation in the renal biopsy, interstitial fibrosis and tubular atrophy.<sup>10</sup>

Although there are no randomized studies that prove the efficacy of one therapy over another (especially for kidney involvement), corticosteroids have been used at high doses, either orally or in pulses of methylprednisone, and in association (or not) with immunosuppressive agents, such as cyclophosphamide or azathioprine.<sup>11</sup>

Because of their poor prognosis, according to studies mentioned previously, three patients were treated with pulses of corticosteroids and monthly IV cyclophosphamide with a favorable clinical response as well as improvements in laboratory parameters, with no renal sequelae.

Although HSP is infrequent in adults, renal involvement deserves special attention because it darkens the prognosis. Thus, these patients should be detected and treated as early as possible.

## REFERENCES

- Watts RA, Scott D. Epidemiology of the Vasculitides. *Semin Resp Crit Care*. 2004;25:455-464.
- Mills JA, Michel BA, Bloch DA, Calabrese LH, Hunder GG, Arend WP et al. The American College of Rheumatology 1990 criteria for the classification of Henoch Schönlein purpura. *Arthritis Rheum*. 1990;33:1114-21.
- Gedalia A. Henoch-Schönlein purpura. *Curr Rheumatol Rep*. 2004;6:195-202.
- Ballinger S. Henoch-Schönlein purpura. *Curr Opin Rheumatol*. 2003;15:591-4.
- Garcia-Porrua C, Calvino MC, Llorca J, Couselo JM, Gonzalez-Gay MA. Henoch-Schönlein purpura in children and adults: clinical differences in a defined population. *Semin Arthritis Rheum*. 2002;32:149-56.
- Ameal Guirado A, Montes Santiago J. Schönlein Henoch purpura in adults. *An Med Int*. 2004;21:79-80.

7. Shrestha S, Sumingan N, Tan J, Alhous H, McWilliam L, Ballardie F. Henoch Schönlein purpura with nephritis in adults: adverse prognostic indicators in a UK population. *QJM*. 2006;99:253-65.
8. Blanco R, Rodríguez Valverde V, Mata Arnaiz C, Martínez Taboada VM. Síndrome de Schönlein Henoch. *Rev Esp Reumatol*. 2000;27:54-65.
9. Rieu P, Noel LH. Henoch-Schönlein nephritis in children and adults. Morphological features and clinicopathological correlations. *Ann Med Interne*. 1999;150:151-9.
10. Garcia-Porrúa C, Gonzalez-Louzao C, Llorca J, Gonzalez-Gay MA. Predictive factors for renal sequelae in adults with Henoch-Schönlein purpura. *J Rheumatol*. 2001;28:1019-24.
11. Kellerman PS. Henoch-Schönlein purpura in adults. *Am J Kidney Dis*. 2006;48:1009-16.