

LETTER TO THE EDITOR

THE MEDIAN-RADIAL TYPE OF SUPERFICIAL PALMAR ARCH: A CASE REPORT AND REVIEW OF THE LITERATURE

doi: 10.1590/S1807-59322008000300021

Soubhagya R. Nayak, Ashwin Krishnamurthy, Lakshmi Ramanathan, Latha V. Prabhu

INTRODUCTION

The superficial palmar arch (SPA) of the hand is generally formed by the ulnar artery (UA) and superficial palmar branch of the radial artery (RA). Very rarely, however, the SPA is formed by the median artery (MA) and RA. This was termed the *median-radial type* (MRT) of SPA by Adachi in 1961 in Keen (Am. J. Anat. 108: 245-61).¹ The recent use of the RA as a coronary artery bypass graft in myocardial revascularization makes the MRT of SPA clinically more significant.

The SPA is a direct continuation of the ulnar artery. Upon entering the palm, the ulnar artery curves laterally behind the palmar aponeurosis and in front of the long flexor tendons. The arch is completed on the lateral side by one of the branches of the RA, the superficial palmar branch, the arteria radialis indicis (ARI) or the princeps pollicis.² According to Adachi in Keen (1961) there are 3 types of SPA: type I, or “ulnar”, has a minimal or absent contribution from the radial artery; type II, or “radio-ulnar”; and type III, or “median-ulnar”, in which the median artery is strong enough to irrigate the palm of the hand and be a part of the arch. The author also described a very rare type of SPA, where the MA anastomoses with the RA, resulting in a minimal or absent contribution from the ulnar artery (median-radial type of SPA).¹

Although the radial and ulnar arteries provide the majority of the blood supply to the hand, additional circulation may come from the median artery or the interosseous arterial system³. Various anomalous patterns in the arterial arches have been studied, and a classification based on the relationship

between the superficial branches of the RA and the UA has been proposed by various authors.⁴⁻⁹ The paucity of literature regarding the median-radial type of SPA makes additional case reports related to this variation particularly interesting for clinicians, surgeons and anatomists

CASE DESCRIPTION

During routine dissection, we observed a MRT of SPA in the right hand of a 67- year-old male cadaver. The SPA was formed by a joining of the MA with the ARI [The deep branch of the RA] (Fig. 1). We noted that the MA originated from the common interosseous artery (CIA) and pierced the median nerve in the distal third of the forearm as it approached the palm. Of the three common palmar digital arteries (CPDAs), only the radial-most CPDA originated from the SPA, while the remaining two CPDAs originated from the superficial branch of the UA. In addition, the proper palmar digital artery to the radial side of the index finger also originated from the SPA.

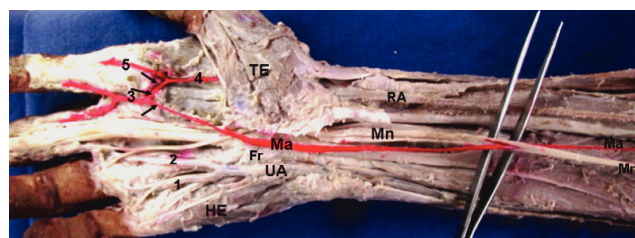


Figure 1 - Ventral aspect of the distal third of the forearm and hand. Fr, flexor retinaculum; HE, hypothenar eminence; Ma, median artery; Mn, median nerve; RA, radial artery; TE, thenar eminence; UA, ulnar artery; 1 & 2, common palmar digital arteries originating from the ulnar artery; 3, common palmar digital arteries originating from the superficial palmar arch; 4, arteria radialis indicis; 5, proper palmar digital artery to the radial side of the index finger. Note that the black arrows indicate the superficial palmar arch.

Department of Anatomy, Centre for Basic Sciences, Kasturba Medical College - Bejai, Mangalore, Karnataka, India.
ranjanbhatana@gmail.com

This is an Open Access article distributed under the terms of the Creative Commons Attribution Non-Commercial License (<http://creativecommons.org/licenses/by-nc/3.0/>) which permits unrestricted noncommercial use, distribution, and reproduction in any medium, provided the original work is properly cited.

DISCUSSION

Doppler and angiographic studies do not accurately assess small connecting vessels, and uncontrollable vasospasms and reactive vasodilatation following dye injection make interpretation of the angiograms unreliable. Thus, we must rely on anatomical studies in planning surgical procedures.⁹ New insights into the SPA, a dominant vascular structure of the palm of the hand, and recent advances in microsurgical techniques for the reconstruction of the hand have further increased its significance.

Jaschtschinski (1897) studied the SPA in 200 subjects and concluded that the superficial arch was absent in 32 patients. When the SPA was present, the distribution of types was: radio-ulnar, 27%; ulnar, 38%; medio-ulnar, 3%; and radio-medio-ulnar, 0.5%⁴.

The MA is a transitory vessel that represents the arterial axis of the forearm during early embryonic life. Its persistence in the human adult has been recorded in two different patterns: as a small and short vessel (antebrachial type) that ends before reaching the wrist joint, and as a large, long vessel (palmar type) that reaches the hand.¹⁰ Sometimes, the palmar type of MA is also involved in forming the SPA. The medio-ulnar and radio-medio-ulnar types of SPA were

the least common types among all the types of SPA observed by various authors. For example, Coleman and Anson (1961) found the medio-ulnar and radio-medio-ulnar types in only 3.8% and 1.2% of cases, respectively, of 650 hands studied.⁵ Similarly, Al-Turk and Metcalf (1984) found the same types of SPA in 4% and 2% of all hands, respectively, using a Doppler Ultrasonic Flowmeter.⁶ Ikeda et al. (1988) observed that the radio-medio-ulnar type of SPA was absent in their study, while the medio-ulnar type was found in only 0.9% of subjects.⁷ Tagil et al. (2007) showed an absence of both the medio-ulnar and radio-medio-ulnar types.⁹ However, Loukas et al. (2005) dissected 200 hands and observed very high percentages of the medio-ulnar type (15%) and radio-medio-ulnar type (6.1%) of SPA.⁸

Although the formation of the SPA by the MA and RA has been mentioned in the literature (Keen, 1961), its rate of occurrence in different populations is not yet known. Further study of the above types of SPA in different races will help to establish its rate of occurrence. The present case documenting a median-radial type of SPA is the first of its kind reported in the recent literature. Although this type of SPA occurs very rarely, surgeons and clinicians should be aware of such an SPA variation when the palm region is involved.

REFERENCES

1. Keen JA. Study of the arterial variations in the limbs, with special reference to symmetry of vascular patterns. *Am J Anat.* 1961;108:245-61.
2. Snell RS. 1995. *Clinical Anatomy for Medical Students*. 5th ED. London: Little, Brown & Company. 1995, p. 450.
3. Ruengsakulrach P, Eizenberg N, Fahrer C, Fahrer M, Buxton BF. Surgical implications of variations in hand collateral circulation: Anatomy revisited. *J Thorac Cardiovasc Surg.* 2001;122:682-6.
4. Jaschtschinski SN. Morphologie und Topography des Arcus volaris sublimis und profundus des Menschen. *Anat Hefte.* 1897;7:161-88.
5. Coleman SS, Anson BJ. 1961. Arterial patterns in the hand based upon a study of 650 specimens. *Surg Gynecol Obstet.* 1961;113:409-24.
6. Al-Turk M, Metcalf WK. A study of the superficial palmar arteries using the Doppler Ultrasonic Flow meter. *J Anat.* 1984;138:27-32.
7. Ikeda A, Ugawa A, Kazihara Y, Hamada N. Arterial patterns in the hand based on three-dimensional analysis of 220 cadaver hands. *J Hand Surg.* 1988;13A:501-9.
8. Loukas M, Holdman D, Holdman S. Anatomical variations of the superficial and deep palmar arches. *Folia Morphol (Warsz).* 2005;64:78-83.
9. Tagil SM, Cicekcibasi AE, Ogun TC, Buyukmumcu M, Salbacak A. Variations and Clinical Importance of the Superficial Palmar Arch. *S D U Typ Fak Derg.* 2007;14:11-6.
10. Rodriguez-Niedenfuhr M, Sanudo JR, Vazquez T, Nearn L, Logan B, Parkin I. 1999. Median artery revisited. *J Anat.* 1999;195:57-63.