

## LETTER TO THE EDITOR

# ENCEPHALOCRANIOCUTANEOUS LIPOMATOSIS (HABERLAND'S SYNDROME) - A CASE REPORT OF A NEUROCUTANEOUS SYNDROME AND A REVIEW OF THE LITERATURE

doi: 10.1590/S1807-59322008000300020

Giovanna Negrisoli Koishi,<sup>I</sup> Mauricio Yoshida,<sup>I</sup> Nivaldo Alonso,<sup>I</sup> Hamilton Matushita,<sup>II</sup> Dov Goldenberg<sup>I</sup>

## INTRODUCTION

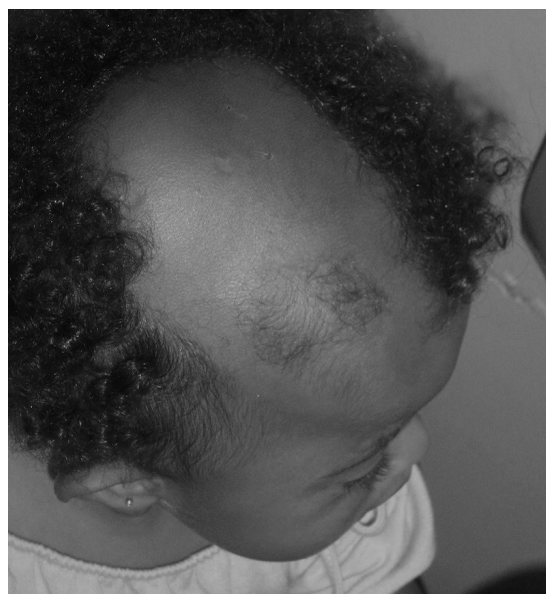Encephalocraniocutaneous Lipomatosis (ECCL) is a rare neurocutaneous syndrome first described by Haberland and Perou in 1970.<sup>1</sup> It is characterized by unilateral cutaneous, ocular, and neurologic malformations. There are 53 cases described in the literature, but only four of these are in Brazil.<sup>2-10</sup>

## CASE REPORT

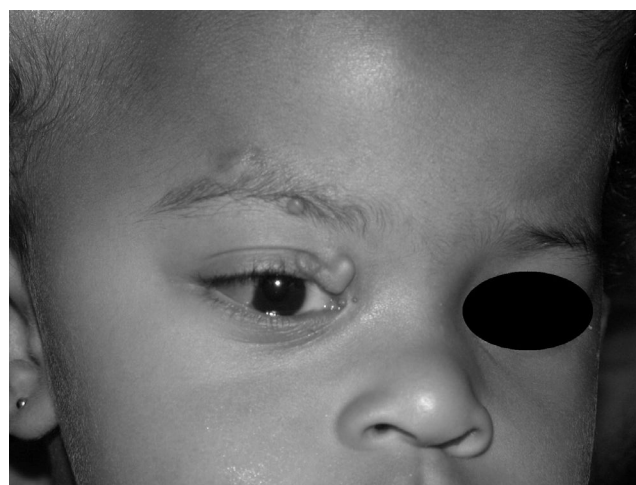
We present the case of a full-term girl born to non-consanguineous parents. Physical examination revealed a large (14 x 6 centimeters) hairless lesion on the right frontal-parietal scalp (Fig.1), multiple nodular lesions of the right upper eyelid and eyebrow, and a reddish bulbar conjunctival lesion on the right eye consistent with choriocystoma (Fig.2).

A CT scan of the brain showed cranial asymmetry, an arachnoid cyst of the right middle fossa, a right frontal subdural collection, a porencephalic cyst, hemiatrophy of the right hemisphere, and cortical calcifications of the parietal and occipital lobes (Fig.3).

At the age of two years, the patient underwent a complete excision of the scalp lesion after tissue expansion and excision of the nodules on the eyelid (Fig.4). The histopathological examination of the scalp lesion showed absence of hair follicles, a thinned dermis, and extended adipose tissue into the dermis; the cutaneous nodules were



**Figure 1** - The hairless lesion ("naevus psiloliparus")

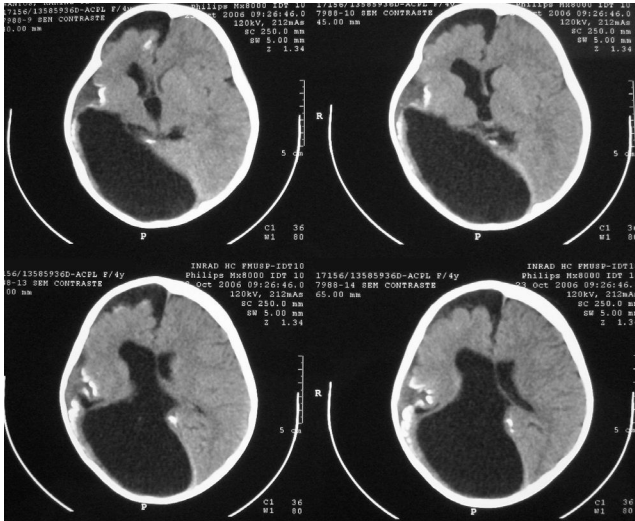


**Figure 2** - The choriocystoma and the lipomas of the eyelid

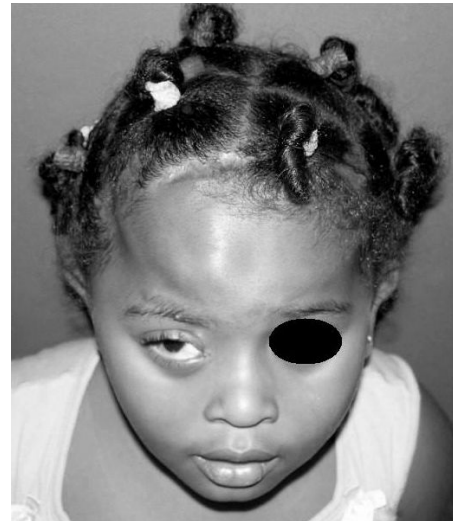<sup>I</sup> Craniofacial Unit, Faculdade de Medicina da Universidade de São Paulo – São Paulo/SP, Brazil.

<sup>II</sup> Neurosurgery Department, Faculdade de Medicina da Universidade de São Paulo – São Paulo/SP, Brazil.  
gikoishi@hotmail.com

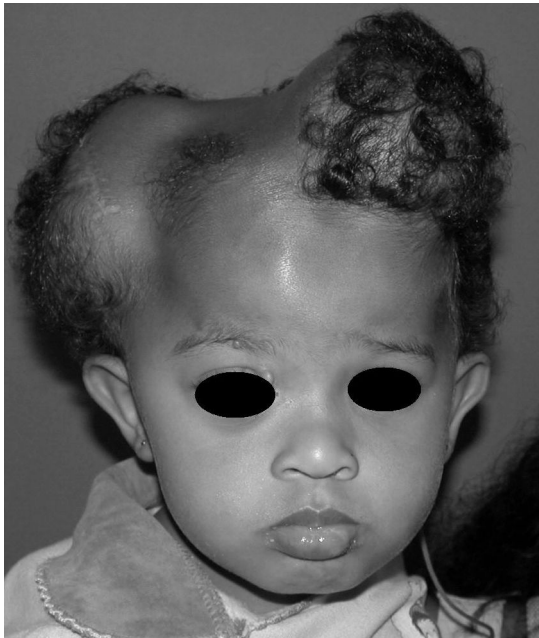This is an Open Access article distributed under the terms of the Creative Commons Attribution Non-Commercial License (<http://creativecommons.org/licenses/by-nc/3.0/>) which permits unrestricted noncommercial use, distribution, and reproduction in any medium, provided the original work is properly cited.



**Figure 3** - CT scan of the brain shows: porencephalic cyst, hemiatrophy of the right hemisphere, subdural collection and parietal calcifications



**Figure 5** - Post-operative results



**Figure 4** - Tissue expansion for surgical excision of the “naevus psiloliparus”

consistent with lipoma. In the four year follow-up period, the patient was noted to have mental retardation and seizures that were controlled with medication and neurological treatment (Fig.5).

## DISCUSSION

ECCL is a rare, sporadic, neurocutaneous syndrome with no predominant gender, racial, or geographical association.<sup>11,12</sup> The genetic mechanism has been hypothesized to involve lethal autosomal dominant genes

that survive by mosaicism, and the pathogenesis is most likely a dysgenesis of the cephalic neural crest and anterior neural tube.<sup>3,11,13</sup>

Clinically, ECCL is characterized by unilateral abnormalities of the brain, eyes, and skin. The most common neurological findings are hemiatrophy, dilated ventricles, porencephalic cysts, abnormal calcifications, intracranial lipoma, and cranial asymmetry. Most patients present with seizures and mental retardation.<sup>3,9,11,12</sup> The hairless lesion of the scalp (“naevus psiloliparus”) is pathognomonic, and the papular lesions of the eyelid, consistent with lipomas, are the most frequent feature in all cases reported. However, other lesions have also been reported, such as lipomas of the vertebral spine, odontom, and “café-au-lait” spots.<sup>3,14</sup>

The diagnosis of ECCL may be difficult because of the overlapping features with other neurocutaneous syndromes. Patients with oculocerebrocutaneous syndrome (Delleman's syndrome) have similar lesions of the eyes and scalp, but also present with a pathognomonic mid-hindbrain malformation. Other syndromes, like Sturge-Webber syndrome and Proteus syndrome, have neurological features similar to ECCL, although the cutaneous malformations are very different.<sup>3,6,11,14</sup> Therefore, a careful and complete examination of these patients including a multidisciplinary evaluation and follow-up by a neurosurgeon, pediatrician, ophthalmologist, and plastic surgeon is necessary for accurate diagnosis of this condition. Delay in diagnosis is common in these patients though it is best if the pediatrician makes the diagnosis at birth to improve prognosis and orientations of the relatives. Antenatal diagnosis is not usually made because the intracranial malformations noted on an antenatal sonogram are not specific for ECCL.<sup>15</sup>

## REFERENCES

1. Habeland C, Perou M. Encephalocraniocutaneous lipomatosis: a new example of ectodermal dysgenesis. *Arch Neurol.* 1970;22:144-55.
2. Hauber K, Warmuth-Metz M, Rose C, Bröcker E, Hamm H. Encephalocraniocutaneous lipomatosis: a case with unilateral odontomas and review of the literature. *Eur J Pediatr.* 2003;162:589-93.
3. Gokhale NR, Mahajan PM, Belgaumkar VA, Pradhan SN, Uttarwar NS. Encephalocraniocutaneous lipomatosis: a rare neurocutaneous syndrome. *Indian J Dermatol Venereol Leprol.* 2007;73:40-2.
4. Valladares MJ, Blanco MJ, Lopez-Lopez F, Gonzalez F. Bilateral ocular involvement in encephalocraniocutaneous lipomatosis. *Eur J Pediatr Neurol.* 2007;11:108-10.
5. Rathoryia R, Shrivastava J. Encephalocraniocutaneous lipomatosis. *Indian Pediatr* 2006;43:262-3.
6. Sofiatti A, Cirto AG, Armone M, Romiti R, Santi C, Leite C, et al. Encephalocraniocutaneous lipomatosis: clinical spectrum of systemic involvement. *Pediatr Dermatol* 2006;23:27-30.
7. Donaire A, Carreno M, Bargallo N, Setoain X, Agudo R, Martin G, et al. Presurgical evaluation and cognitive functional reorganization in Fishman syndrome. *Epilepsy Behav.* 2005;6:440-3.
8. Cultrera F, Guarnera F, Giardina MC. Overlap among neurocutaneous syndromes. Observations on encephalocraniocutaneous lipomatosis. *Minerva Pediatr.* 2004;56:219-22.
9. Lasiera R, Valencia I, Carapeto FJ, Ventura P, Samper MP, Rodriguez G, et al. Encephalocraniocutaneous lipomatosis: neurologic manifestation. *J Child Neurol.* 2003;18:725-9.
10. Guazzelli UF, Rufatto LA, Tavares AJ, Gehrke R. Encephalocraniocutaneous lipomatosis (Haberland syndrome). *Rev Soc Bras Cir Craniomaxilofac.* 2005;1:24.
11. Cruz AA, Schirmbeck T, Pina-Neto JM, Funayama CA. Cicatricial upper eyelid retraction in encephalocraniocutaneous lipomatosis: a report of two cases and review of literature. *Ophthalm Plast Reconstr Surg.* 2002;18:151-5.
12. Almer Z, Vishnevskia-Dai V, Zadok D. Encephalocraniocutaneous lipomatosis: case report and review of the literature. *Cornea.* 2003;22(4):389-90.
13. Happle R. Lethal gene surviving by mosaicism: a possible explanation for sporadic birth defects involving the skin. *J Am Acad Dermatol.* 1987;16:899-906.
14. Rubegni P, Risulo M, Sbrano P, Buonocore G, Perrone S, Fimiani M. Encephalocraniocutaneous lipomatosis (Haberland syndrome) with bilateral cutaneous and visceral involvement. *Clin Exp Dermatol.* 2003;28:387-90.
15. Nowaczyk MJ, Mernagh JR, Bourgeois JM, Thompson PJ, Jurriaans E. Antenatal and postnatal findings in the encephalocraniocutaneous lipomatosis. *Am J Med Genet.* 2000;91(4):261-6.