

## LETTER TO THE EDITOR

CYSTOPROSTATECTOMY WITH ILEAL NEOBLADDER  
FOR TREATMENT OF SEVERE CYSTITIS  
GLANDULARIS IN AN AIDS PATIENT

doi: 10.1590/S1807-59322008000500023

Rafael Ferreira Coelho,<sup>I</sup> Giovanni Scala Marchini,<sup>II</sup> Marcos Francisco Dall'Oglio,<sup>I</sup> Mabel Tatty de Medeiros,<sup>III</sup> Adriano João Nesrallah,<sup>I</sup> Miguel Srougi<sup>I</sup>

## INTRODUCTION

Cystitis glandularis (CG) is a proliferative and metaplastic disorder of the bladder urothelium<sup>1</sup> that usually occurs when the bladder mucosa becomes hyperproliferative in the presence of chronic inflammation and nests of urothelium appear within the lamina propria. If inflammation persists, the urothelium may differentiate and eventually develop into cystic lesions (cystitis cystica) or glandular metaplastic lesions (cystitis glandularis).<sup>2</sup>

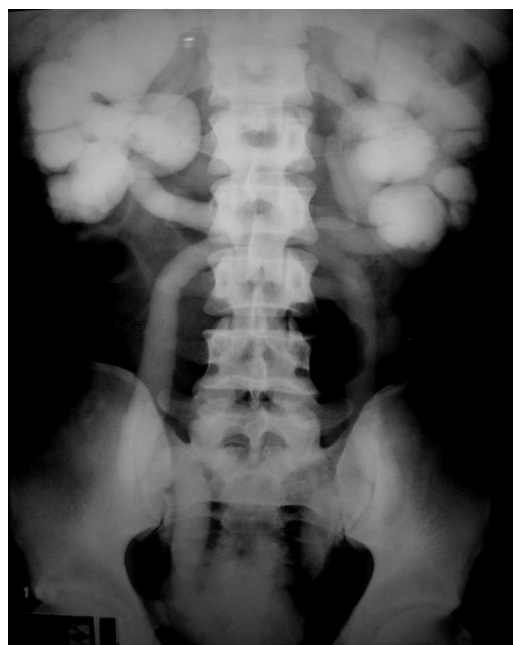CG is rarely reported in children; even in adults, its incidence and clinical significance are not well known.<sup>3</sup> It is generally a microscopic finding subsequent to cystoscopy and biopsy in a patient with irritative bladder symptoms or hematuria.<sup>4-6</sup> Most patients do not require more aggressive surgery options, and sparse literature is available regarding the management of severe CG.<sup>6</sup> We report here a case of an AIDS (Acquired Immunodeficiency Syndrome) patient with cystitis glandularis refractory to standard treatment who was treated with a total cystoprostatectomy and ileal neobladder reconstruction.

## CASE REPORT

A 47-year-old man presented at our institution with a 10-year history of irritative and obstructive voiding symptoms

and intermittent macroscopic hematuria. He was using Lamivudine, Zidovudine, and Efavirenz for treatment of acquired immune deficiency syndrome (AIDS). Physical examination revealed that he had a homogeneous 20 g prostate, and laboratory testing showed normal creatinine (1.2 mg/dL) and PSA (0.8 mg/dL). Urinary culture was invariably negative.

Urinary ultrasonography revealed a thickened bladder wall and a polypoid mass in the vesical trigone and prostatic urethra. Intravenous urography showed severe bilateral hydronephrosis and delayed contrast excretion (Figure 1). Computed tomography (CT) confirmed the thickening of the bladder wall and revealed bilateral distal ureteral thickening



**Figure 1** – Intravenous urography showing bilateral ureterohydronephrosis and delayed contrast excretion. (150 minutes)

<sup>I</sup> Department of Urology, Hospital das Clínicas, Faculdade de Medicina da Universidade de São Paulo – São Paulo/SP, Brazil.

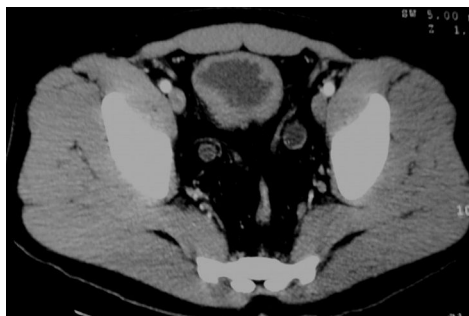<sup>II</sup> Department of General Surgery, Hospital das Clínicas, Faculdade de Medicina da Universidade de São Paulo – São Paulo/SP, Brazil.

<sup>III</sup> Department of Pathology, Hospital das Clínicas, Faculdade de Medicina da Universidade de São Paulo – São Paulo/SP, Brazil.

Phone: 55 11 9450.2824

Email: coelho@uol.com.br

This is an Open Access article distributed under the terms of the Creative Commons Attribution Non-Commercial License (<http://creativecommons.org/licenses/by-nc/3.0/>) which permits unrestricted noncommercial use, distribution, and reproduction in any medium, provided the original work is properly cited.



**Figure 2** –Pelvic computed tomography revealing diffuse bladder wall thickening and bilateral ureteral wall thickening and dilatation

and dilatation up to the ureterovesical junction (Figure 2). Cystoscopy revealed a polypoid mass in the vesical trigone and prostatic urethra with an inflammatory aspect. The ureteral orifices were completely obstructed and therefore impossible to identify. An incomplete transurethral resection (TURB) of the lesion was performed. Histological study revealed chronic CG with the formation of an inflammatory polyp.

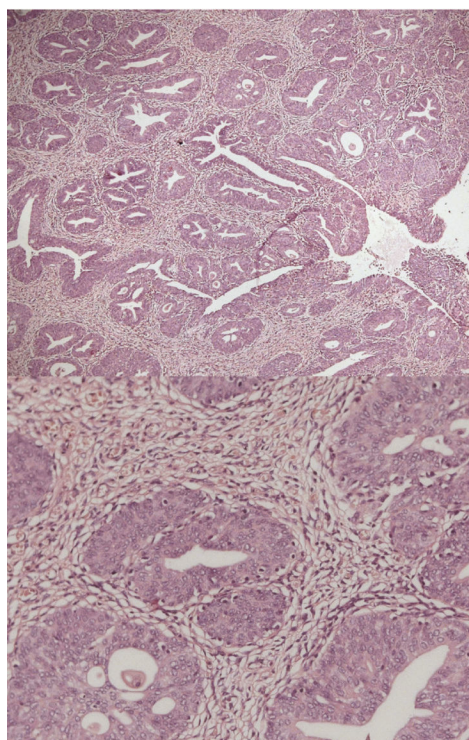
After treatment, the patient was asymptomatic for two months, after which the irritative voiding symptoms recurred. Another two TURBs were performed, with partial and temporary improvement of the symptoms. Six months after the first TURB, the patient presented anuria and azotemia secondary to bilateral ureteral obstruction. Bilateral percutaneous nephrostomy was performed, with complete

recovery of renal function. After considerable counseling, the patient underwent a total cystoprostatectomy with ileal neobladder construction. Microscopic analysis confirmed chronic CG all along the bladder urothelium (Figure 3). The postoperative period was uneventful. At the 6-month follow-up, the patient was voiding well with complete continence; the serum creatinine level was 1.0 mg/dl and intravenous urography showed normal contrast excretion, with markedly reduced ureterohydronephrosis (Figure 4).

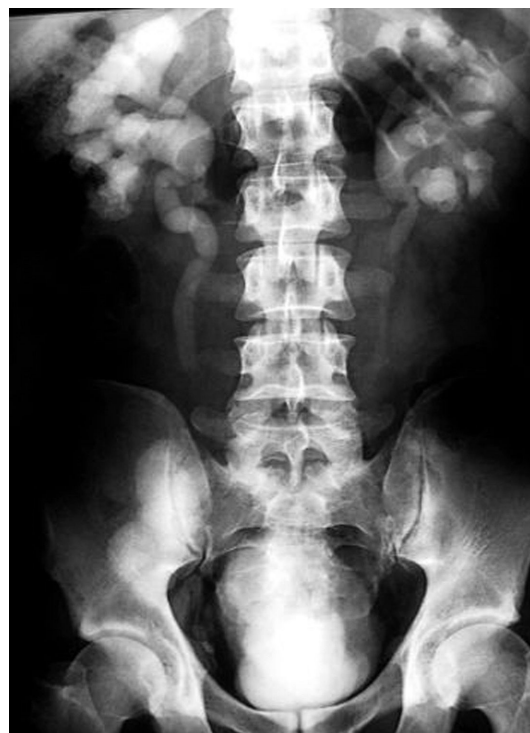## DISCUSSION

CG is a benign proliferative disease of the bladder mucosa. It is accepted that the intestinal metaplasia of cystitis glandularis is a result of a chronic irritative and infectious stimulus, initially appearing as submucosal masses of epithelial cells (Brunn's nest) followed by cavitations of such structures, central necrosis, or serosal secretion. This results in the appearance of miliary cystic structures lined with cubic or columnar epithelium and filled with serosal fluid, termed cystitis cystica. The condition is termed cystitis glandularis when there is metaplasia in a mucus-secreting epithelium.<sup>7</sup>

The exact incidence of cystitis glandularis is unknown. Patients with bladder exstrophy,<sup>8</sup> pelvic lipomatosis<sup>9</sup>, and chronic or recurrent UTIs are considered to be at risk.<sup>7,10,11</sup> Other causal factors, such as avitaminosis, allergy, hormone



**Figure 3** - Histology showing glandular structures lined with mucus-secreting cubic and columnar cells consistent with cystitis glandularis



**Figure 4** - Intravenous urography, at the 6-month follow-up, showing normal contrast excretion and marked reduction of ureterohydronephrosis

imbalance, specific carcinogens, and IgA-mediated immune mechanisms have been proposed.<sup>9,10</sup> To our knowledge, our case is the first report of severe cystitis glandularis in a patient with AIDS. The exact correlation, if one exists, between immunodeficiency and cystitis glandularis is still unclear.

If an etiology such as chronic infection is identified, it must be appropriately treated. In the reported case, no urinary infection or other causal factors were found. An associated risk of bladder cell carcinoma<sup>10</sup> and adenocarcinoma has been reported<sup>11-15</sup> but is still debated.<sup>4</sup> Although most patients with cystitis glandularis will never develop a malignant bladder lesion, it cannot be excluded that the most widely proliferative lesions may have premalignant potential.<sup>7</sup>

Lesions of cystitis glandularis are most frequent at the bladder neck or trigone,<sup>3</sup> as in the reported case. If a mass lesion is identified, it is resected transurethrally. Generally, effective management is implemented and no further procedures are necessary to control the disease. Intravesical BCG (bacillus Calmette-Guerin) application has been described as an adjuvant therapy after TURB for

the treatment of cystitis glandularis.<sup>16</sup> Ureteral obstruction is a rare complication that results from infiltration of the periureteral submucosa.<sup>17</sup> It may be treated with ureteral reimplantation into the dome of the bladder<sup>18</sup> in the presence of a contractile bladder, or may require temporary percutaneous nephrostomy, as was performed in our patient. Intravesical hydrocortisone instillation<sup>19</sup> and laser ablation<sup>20</sup> for the management of severe CG cases have been reported as alternative treatments. Cystectomy with continent urinary diversion for cystitis glandularis has been very rarely reported.<sup>6,5</sup> Obviously, such surgical procedures should be the last resort in these patients.<sup>6</sup> Urinary diversion without cystectomy in such cases is considered to be ill-advised due to the possibility of persistent symptoms and the associated risk of adenocarcinoma. Our current patient had florid disease, leading to persistent irritative voiding symptoms and upper urinary tract obstruction even after multiple transurethral resections. He was successfully submitted to cystoprostatectomy with ileal neobladder reconstruction and has been asymptomatic up to the present.

## REFERENCES

1. Bryan T, Nicholls J H, Harrison R F, Jankowski J A, Wallace M A. The role of B-catenin signaling in the malignant potential of cystitis glandularis. *J Urol*. 2003; 170:1892-6.
2. Jacobs L B, Brooks J D, and Epstein, J I. Differentiation of colonic metaplasia from adenocarcinoma of the urinary bladder. *Hum Pathol*. 1997;28:1152-7.
3. Capozza N, Collura G, Nappo S, De Dominicis M, Francalanci P, Caione P. Cystitis Glandularis In Children. *BJU International*. 2005;95:411-3.
4. Andersen J A, Hansen, B F. The incidence of cell nests, cystitis cystica and cystitis glandularis in the lower urinary tract revealed by autopsies. *J Urol*. 1972;108:421-4.
5. Young R H, Bostwick, D G. Florid cystitis glandularis of intestinal type with mucin extravasation: a mimic of adenocarcinoma. *Am J Surg Pathol*. 1996; 20:1462-8.
6. Black PC, Lange PH. Cystoprostatectomy and Neobladder Construction for Florid Cystitis Glandularis. *Urology*. 2005;65:174.
7. Rigatti P, Fenaroli P, Guazzoni G, Lucetti U. Modern approaches to the etiopathogenesis and therapy for cystic and glandular cystitis. *Minerva Urol Nephrol*. 1986;38:351-9.
8. Hardy JC. La cystopathie glandulaire. *Acta Urol Belgica*. 1970; 38:464-73.
9. Heyns CF, De Kock MI, Kirsten PH, van Velden DJ. Pelvic lipomatosis associated with cystitis glandularis and adenocarcinoma of the bladder. *J Urol*. 1991;145:364-6.
10. Parker C. Cystitis cystica and glandularis - a study of 40 cases. *Proc Roy Soc Med*. 1970;63:239-42.
11. Medina Perez M, Valero Puerta JÁ, Valpuesta Fernández I, Sánchez González M. Bladder adenocarcinoma with glandular cystitis areas. *Arch Esp Urol*. 2001;54:254-6.
12. Shaw JL, Gislason GJ, Imbriglia JE. Transition of cystitis glandularis to primary adenocarcinoma of the bladder. *J Urol*. 1958;79:815-22.

13. Kittredge WE, Collett AJ, Morgan C. Adenocarcinoma of the bladder associated with cystitis glandularis: a case report. *J Urol*. 1964;91:145-50.
14. Edwards PD, Hurm RA, Jaesohke WH. Conversion of cystitis glandularis to adenocarcinoma of the bladder. *J Urol*. 1972;108:568-70.
15. O'Brien AM, Urbanski SJ. Papillary adenocarcinoma in situ of the bladder. *J Urol*. 1985;134:544-6.
16. Mitre AI, Silveira CA, Leite KR, Piovesan AC Glandular cystitis: a rare benign condition presenting as a pseudo-tumor of the bladder. *Clinics*. 2007;62:93-4.
17. Navarro JE, and Huggins TJ. Cystitis glandularis: an unusual cause of ureteral obstruction. *Urol Radiol*. 1984;6:27-9.
18. Rao KG. Cystitis glandularis causing bilateral ureteric obstruction and hydronephrosis. *Br J Urol*. 1975;47:398.
19. Holder P, Plail R, Walker MM, Witherow RO. Cystitis glandularis-reversal with intravesical steroid therapy. *Br J Urol*. 1990;65:547-8.
20. Stillwell TJ, Patterson DE, Rife CC, Farrow GM. Neodymium:YAG laser treatment of cystitis glandularis. *J Urol*. 1988;139:1298-9.