

## LETTER TO THE EDITOR

## AN ANOMALY OF FLEXOR MUSCLES OF THE FIFTH (LITTLE) FINGER OF THE HAND: AN ANATOMICAL CASE REPORT

doi: 10.1590/S1807-59322009001100016

Ali Yılmaz, Cüneyt Bozer, Enis Uluçam, Oğuz Taşkinalp

## INTRODUCTION

Various anomalies of the flexor digitorum superficialis (FDS) and flexor digitorum profundus (FDP) muscles of the little finger have been reported in the literature. These include many variations of the FDS and FDP, such as absence of the little finger FDS tendon, aplasia of the FDP to the little finger, an accessory FDS to the little finger, doubling of the tendon, attachments to other superficialis tendons or to the profundus tendon, tendon insertion anomalies, and additional muscle slips from the FDS of the ring finger to the FDS of the little finger.<sup>1-16</sup>

Variations of the FDS have been termed retrogressive or progressive according to the presence of remnants of the connections between two sheets of muscles or the occasional separation (up to the origin point) of individual muscle bellies, respectively.<sup>10,14</sup>

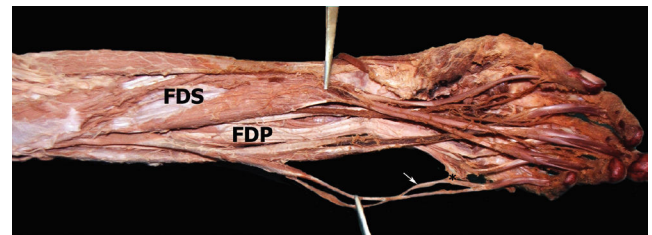
Furthermore, single-origin (either antebrachial or palmar) and dual-origin (both antebrachial and palmar) hypotheses have been proposed for the origin of the FDS, based on the variations seen, the innervations present, and ontogeny and phylogeny.<sup>7,17</sup>

A general survey of the literature failed to reveal any case reports similar to ours. Therefore, the purpose of this case study is to describe a muscular variant, which to our knowledge has not previously been identified.

## CASE REPORT

A routine dissection course on the anterior aspect of

the left forearm of a 32-year-old female cadaver revealed a double FDS tendon, with one tendon acting as the FDP tendon to the little finger. In addition, there was a connection between this anomalous tendon and the FDP tendon to the ring finger. The FDP tendon originated from the FDS muscle at the forearm and had a normal distal attachment. The FDS was innervated by the median nerve. The blood supply of the tendon acting as the FDP tendon to the little finger was from a muscular branch of the ulnar artery. It was innervated by a branch from the median nerve. There were no muscular anomalies in the right arm or hand (Figs. 1-3).



**Figure 1** - Anterior aspect of the left forearm. FDS: flexor digitorum superficialis, FDP: flexor digitorum profundus. White arrow indicates the FDP tendon originating from the FDS muscle, and the black asterisk indicates the intertendinous connection

## DISCUSSION

Absence of the FDP of the little finger was recently reported by Furrer et al. Their case report showed the presence of the FDS and the absence of the FDP by ultrasound and magnetic resonance imaging in the right little finger of a nine-year-old boy.<sup>13</sup> However, unlike the present case, there was no muscle or tendon substituting for the FDP tendon to the little finger.

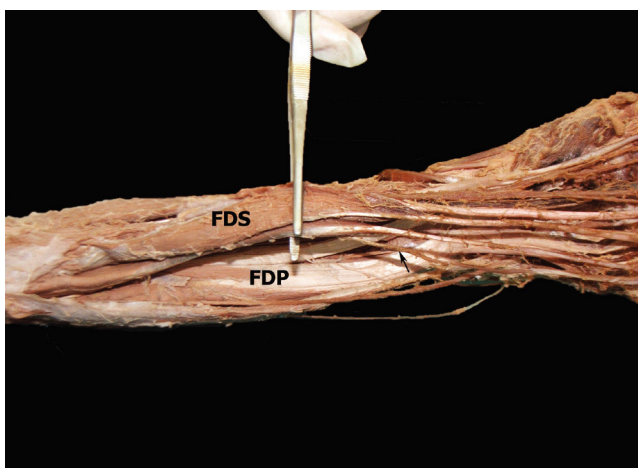
In three specimens, Austin et al. demonstrated tendinous slips from the FDS to the FDP of the little finger. These slips were well defined and very narrow and prevented FDS

Trakya University, Faculty of Medicine, Department of Anatomy, Balkan Campus - Edirne, Turkey.  
Email: cuneytbozer@trakya.edu.tr  
Tel: +90/284/2355935

This is an Open Access article distributed under the terms of the Creative Commons Attribution Non-Commercial License (<http://creativecommons.org/licenses/by-nc/3.0/>) which permits unrestricted noncommercial use, distribution, and reproduction in any medium, provided the original work is properly cited.



**Figure 2** - Close view of the connection between the anomalous tendon and the FDP tendon to the ring finger. The white arrow indicates the FDP tendon originating from the FDS muscle, and the white asterisk indicates the intertendinous connection



**Figure 3** - Anterior aspect of the left forearm. FDS: flexor digitorum superficialis, FDP: flexor digitorum profundus. Black arrow indicates the FDP tendon originating from the FDS muscle

function independently of FDP function to the little finger.<sup>15</sup> A review of FDS and FDP muscle variations by Bergman et al. mentioned that there has also been a report of a slip from the ulnar side of the FDP running to join the FDS tendon of little finger.<sup>14</sup> In addition, the FDP was fused with the FDS in 11% of 205 arms examined; however, the FDS and FDP muscle bellies were not fused in the present case. The FDP

tendon to the little finger originated separately from the FDS muscle.<sup>14</sup>

The review by Bergman et al. also reported that occasionally a tendon separated from the FDS joins one of the tendons of the FDP muscle (accessorius profundus digitorum).<sup>14</sup> However, in the present case, there was no tendon to the little finger from the FDP muscle, so the FDS tendon to the little finger could not be described as accessory. Wahba et al. reported an accessory belly of the FDP that originated from the intercompartmental septum on the medial side of the forearm just proximal to the wrist joint and inserted on the proximal phalanx of the little finger. Despite this anomaly, the FDS and FDP muscles and tendons were completely intact, with no abnormal variations. This muscle was defined as a combination of an accessory FDP muscle belly acting on the metacarpophalangeal joint of the little finger, and Wahba et al. have named this variant an accessory flexor digiti minimi profundus muscle.<sup>16</sup> Kisner found a double FDS tendon to the little finger with absence of the profundus on the left hand of a 15-year-old patient during surgery; however, unlike the present case, there was a single fifth FDS tendon with normal appearance dividing into FDP and FDS tendons at the level of the distal palmar crease.<sup>6</sup>

The FDS tendon of the little finger is frequently interconnected with the FDS of the ring finger. In the present case, the anomalous FDP tendon to the little finger was attached to the FDP tendon to the ring finger. The close functional link between the ring finger FDS and the little finger FDS explains how an injury to either the ring or little finger can cause malfunction of the adjacent finger. The FDS has been used as a motor for a wide variety of tendon transfer operations in the hand. Most of these transfers are on the volar side of the hand and are used to restore synergistic actions (such as opposition of the thumb) or as intrinsic replacements.<sup>1,9,18</sup> Recognition of these anomalies is important during surgical repair of tendon lacerations. The treating surgeon should consider both digits when dealing with an injury to either finger.<sup>5,15,19</sup>

## REFERENCES

1. Beasley RW. Beasley's Surgery of the Hand. New York: Thieme Medical Publishers Inc; 2003.
2. Johnson D, Ellis H. Pectoral Girdle and Upper Limb: Forearm. In: Standring S, editor. Gray's Anatomy The Anatomical Basis of Clinical Practice. 39<sup>th</sup> ed. Philadelphia: Elsevier Ltd; 2005. pp. 876-7.
3. Cassell MD, Bergman RA. Palmaris longus muscle substituting for the ring finger slip of flexor digitorum superficialis. *Anat Anz.* 1990;171:201-4.
4. Elliot D, Khandwala AR, Kulkarni M. Anomalies of the flexor digitorum superficialis muscle. *J Hand Surg [Br]*. 1999;24:570-4.
5. Gonzalez MH, Whittum J, Kogan M, Weinzwieg N. Variations of the flexor digitorum superficialis tendon of the little finger. *J Hand Surg.* 1997;22:277-80.
6. Kisner WH. Double sublimis tendon to fifth finger with absence of profundus. *Plast Reconstr Surg.* 1980;65:229-30.

7. Kobayashi N, Saito S, Wakisaka H, Matsuda S. Anomalous flexor of the little finger. *Clin Anat.* 2003;16:40-3.
8. Kostakoglu N, Borman H, Kecik A. Anomalous flexor digitorum superficialis muscle belly: an unusual case of mass in the palm. *Br J Plast Surg.* 1997;50:654-6.
9. Nayak SR, Pai MM, Krishnamurthy A, Kumar MSJ, Vadgaonkar R, Prabhu LV. An unusual flexor of the little finger and ulnar nerve entrapment: a case report. *Neuroanatomy.* 2007;6:30-1.
10. Nayak SR, Ramanathan L, Prabhu LV, Raju S. Additional flexor muscles of the forearm: case report and clinical significance. *Singapore Med J.* 2007;48:231-3.
11. Robinson SC. An anomalous flexor digitorum superficialis muscle-tendon unit associated with ulnar neuropathy. A case report. *Clin Orthop Relat Res.* 1985;194: 169-71.
12. Tountas CP, Halikman LA. An anomalous flexor digitorum sublimis muscle. A case report. *Clin Orthop Relat Res.* 1976;121:230-3.
13. Furrer M, Schweizer A, Meuli-Simmen C. Aplasia of the flexor digitorum profundus tendon of the small finger. *J Hand Surg Eur Vol.* 2007;32:111-2.
14. Bergman RA, Afifi AK, Miyauchi R. Illustrated Encyclopedia of Human Anatomic Variation: Opus I: Muscular System: Muscles of the upper limb: Forearm and hand [cited 2009 June 2]. Available from: <http://www.anatomyatlases.org/AnatomicVariants/MuscularSystem/Text/F/17Flexor.shtml>
15. Austin GJ, Leslie BM, Ruby LK. Variations of the flexor digitorum superficialis of the small finger. *J Hand Surg.* 1989;14:262-7.
16. Wahba MY, Singh GD, Lozanoff S. An anomalous accessory flexor digiti minimi profundus muscle: a case study. *Clin Anat.* 1998;11:55-9.
17. Haines RW. The flexor muscles of the forearm and hand in lizards and mammals. *J Anat.* 1950;84:13-29.
18. Agee J, McCarroll HR, Hollister A. The anatomy of the flexor digitorum superficialis relevant to tendon transfers. *J Hand Surg.* 1991;16:68-9.
19. Bowman P, Johnson L, Chiapetta A, Mitchell A, Belusko E. The clinical impact of the presence or absence of the fifth finger flexor digitorum superficialis on grip strength. *J Hand Ther.* 2003;16:245-8.