

## TECHNICAL NOTE

### EFFECTS OF THE MODIFICATION OF THE AORTIC BIFURCATION GEOMETRY: A TECHNICAL NOTE REGARDING A NOVEL MODEL FOR EXPERIMENTAL ATHEROSCLEROTIC AND ANEURYSMATIC LESIONS

doi: 10.1590/S1807-59322010000300018

Rogelio Iván Ortiz-Velázquez,<sup>I,II,III</sup> José Guilherme Mendes Pereira Caldas,<sup>II</sup> Bruno Carmello Rocha Lobo,<sup>I</sup> Jorge Arturo Santos-Franco,<sup>III</sup> Rodrigo Mercado-Pimentel,<sup>III</sup> Rogelio Revuelta<sup>III</sup>

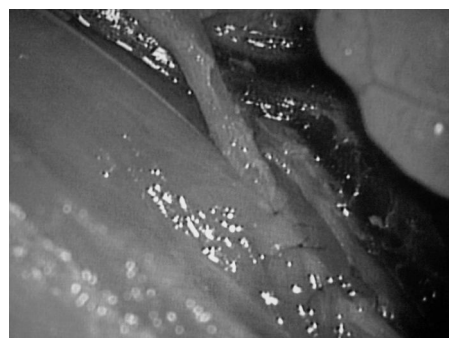
#### INTRODUCTION

Although the defining feature of the vascular tree is its repeated bifurcation, only specific arterial bifurcations are frequent sites for the development of obstructive atherosclerotic and aneurysmatic lesions.<sup>1</sup> Despite the fact that several experimental approaches are available in which these lesions can be induced, no consensus has been reached regarding their pathogenesis.<sup>2</sup> However, in all of these models, the altered hemodynamics have been identified as a major influence in pathogenesis.<sup>3</sup> This aspect motivated the investigation of the vascular flow patterns linked to these particular bifurcations.<sup>4</sup> In these bifurcations, the flow at the artery level is complicated by several features;<sup>5,6</sup> however, these effects are minor compared to the anatomical variations in the bifurcation.<sup>7</sup> Therefore, these aspects prompted us to determine the effects of modifications to the geometry of aortic bifurcation.

#### MATERIALS AND METHODS

The institutional guidelines for research involving animals were followed, and the experimental study was reviewed and approved by the local committee for ethics (Approval no. 382/06). Fifteen male Wistar rats each weighing 250 g

were anesthetized via an intraperitoneal injection of xylazine hydrochloride (10 mg/kg body weight; Pfizer Pharma) and ketamine (100 mg/kg body weight; Pfizer Pharma) and were placed on a thermoregulated surgical table. The body temperature of the rats was maintained at 37 °C. Supplemental doses of the anesthetic were given as needed to maintain a uniform level of anesthesia allowing spontaneous breathing. After supine positioning of the animal, an abdominal midline incision was made. Using a surgical microscope, the aortic bifurcation was approached, and the iliac vessels were isolated distal to the site of bifurcation. The modification of the aortic bifurcation geometry was performed by tunneling the distal end of the iliac artery in the iliolumbar muscle at the root of the inferior member (Fig. 1). Left nephrectomy and ligation of the right inferior renal artery were performed to enhance the vascular stress. The abdominal incision was sutured in a unique layer using a 4-0 mono-nylon running suture, and the animals were kept in cages with food and a solution of 1% NaCl that was provided as drinking water *ad libitum*. All animals were subjected to the same proposed method. After six months of monitoring, the animals were anesthetized,



**Figure 1** - The angle of aortic bifurcation was modified by the tunneling of the right femoral artery into the iliolumbar muscle.

<sup>I</sup> Instituto de Neurocirurgia da Amazônia Ocidental (INAO) - Porto Velho/RO, Brazil.

<sup>II</sup> Interventional Neuroradiology, Instituto de Radiologia do Hospital das Clínicas da Faculdade de Medicina da Universidade de São Paulo (USP) - São Paulo/SP, Brazil.

<sup>III</sup> Instituto Nacional de Neurologia y Neurocirurgia "MVS" (INNN) - México/DF, México.

Email: rivanov72@usp.br

Tel.: 55 11 3069.7065

and the aortic bifurcation and the proximal iliac arteries were inspected and subsequently removed for histopathological analysis. The animals were killed by a massive intraperitoneal injection of sodium pentobarbital (200 mg/kg body weight; Sanofi Aventis). The arterial samples were fixed in 10% neutral buffered formalin for 48 hours and then embedded paraffin blocks in their anatomic form (Y-shape). Serial 5-mm slices were sectioned perpendicularly and parallel to the long axis of the vessels, and the slices were stained using Hematoxylin & Eosin following the Masson and Verhoeff techniques. The slices were observed under an optical microscope to identify inflammatory cells, bleeding, fibrosis, thickening/thinning, and interruption/disorganization of the layers of the arterial wall.

## RESULTS

Four rats developed aneurysmal dilatations at the aortic bifurcation (Fig. 2). Subsequent histopathological analysis of these lesions showed a disorganization of the endothelium, progressive loss of the muscle and elastic layers and substitution of the muscle and elastic layers by disorganized collagen tissue. This connective tissue showed a similar morphological pattern as the one described for atherosclerotic plaques and spontaneous aneurysms in humans (Figs. 3 and 4).

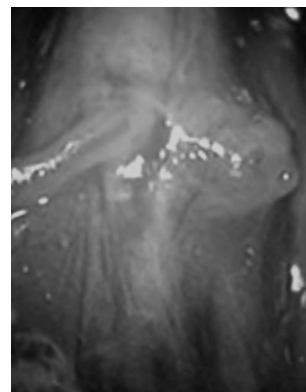
## CONCLUSIONS

In rats with enhanced vascular stress, the modifications to the aortic bifurcation geometry generated hemodynamic alterations resulting in abnormal vascular remodeling with atherosclerotic-like lesions and lead to the formation of aneurysms.

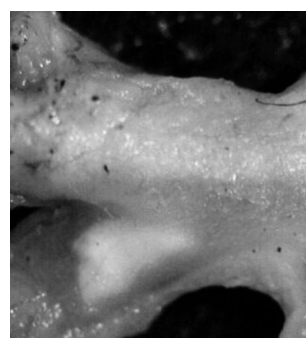
**DISCLOSURE:** This work was supported by a grant from the FAPESP (06/03977-1).

## REFERENCES

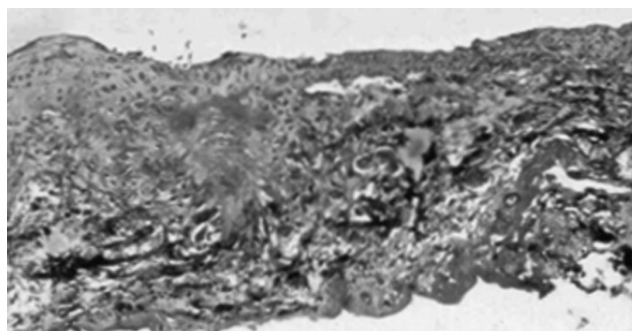
1. Cheng C, Tempel D, van Haperen R, van der Baan A, Grosveld F, Daemen MJAP, et al. Atherosclerotic lesion size and vulnerability are determined by patterns of fluid shear stress. *Circulation*. 2006;113:2744-53.
2. Hashimoto N, Handa H, Hazama F. Experimentally induced cerebral aneurysms in rats. *Surg Neurol*. 1978;10:3-8.
3. Hashimoto N, Kim C, Kikuchi H, Kojima M, Kang Y, Hazama F. Experimental induction of cerebral aneurysms in monkeys. *J Neurosurg*. 1987;67:903-905.
4. Cebal JR, Castro MA, Appanaboyina S, Putman C, Millan D, Frangi AF. Efficient Pipeline for Image-Based Patient-Specific Analysis of Cerebral Aneurysm Haemodynamics: Technique and Sensitivity. *IEEE T Med Imaging*. 2005;24:457-67.
5. Ku DN. Blood Flow in Arteries. *Annu Rev Fluid Mech*. 1997;29:399-434.
6. Taylor C, Draney MT. Experimental and computational methods in cardiovascular fluid mechanics. *Annu Rev Fluid Mech*. 2004;36:197-231.
7. Sitzer M, Puac D, Buehler A, Steckel DA, von Kegler S, Markus H, et al. Internal carotid artery angle of origin a novel risk factor for early carotid atherosclerosis. *Stroke*; 2003;34:950-5.



**Figure 2** - The wide-base saccular lesion was located adjacent to the aortic bifurcation.



**Figure 3** - The atherosclerotic-like lesion of the aortic bifurcation.



**Figure 4** - Masson's trichrome stained section from the aortic wall at the aneurysmal lesion (40 x). Notice the substitution of the normal elements of the arterial wall with fibrous connective tissue.