

## REVIEW

# Retroperitoneoscopic adrenalectomy in pheochromocytoma

Marcelo Hisano, Fabio Carvalho Vicentini, Miguel Srougi

Hospital das Clínicas da Faculdade de Medicina da Universidade de São Paulo.

Since the first laparoscopic adrenalectomy, the technique has evolved and it has become the standard of care for many adrenal diseases, including pheochromocytoma. Two laparoscopic accesses to the adrenal have been developed: transperitoneal and retroperitoneal. Retroperitoneoscopic adrenalectomy may be recommended for the treatment of pheochromocytoma with the same peri-operative outcomes of the transperitoneal approach because it allows direct access to the adrenal glands without increasing the operative risks. Although technically more demanding than the transperitoneal approach, retroperitoneoscopy can shorten the mean operative time, which is critical for cases with pheochromocytoma where minimizing the potential for intra-operative hemodynamic changes is essential. Blood loss and the convalescence time can be also shortened by this approach. There is no absolute indication for either the transperitoneal or retroperitoneal approach; however, the latter procedure may be the best option for patients who have undergone previous abdominal surgery and obese patients. Also, retroperitoneoscopic adrenalectomy is a good alternative for treating cases with inherited pheochromocytomas, such as multiple endocrine neoplasia type 2A, in which the pheochromocytoma is highly prevalent and frequently occurs bilaterally.

**KEYWORDS:** Adrenalectomy; Laparoscopy; Retroperitoneoscopy; Pheochromocytoma; MEN2A.

Hisano M, Vicentini FC, Srougi M. Retroperitoneoscopic adrenalectomy in pheochromocytoma. Clinics. 2012;67(S1):161-167.

E-mail: mhisano@usp.br

Tel.: 55 11 2661-0000

## INTRODUCTION

Pheochromocytoma (PHEO) is a neuroendocrine tumor that derives from chromaffin cells of the adrenal medulla (1). It is a challenging disease that can be cured by removing the affected adrenal gland (2). Open adrenalectomy has been the standard of care in this situation (1). Laparoscopic adrenalectomy was first described in 1992 by Gagner et al. (3) using the transperitoneal approach. Since then, the procedure has been continuously developed and has become the gold standard of care (4–6). Laparoscopic adrenalectomy has evolved from the transperitoneal approach to the retroperitoneal approach, and even single-site access and natural orifice transluminal endoscopic surgery (NOTES) have been developed (7–10).

Retroperitoneoscopy was first described in 1969 by Bartel (11) as a diagnostic tool. In the following years, it has evolved to a minimally invasive diagnostic procedure and finally became a useful route for operative procedures by the early 90s (12–15).

Retroperitoneoscopic adrenalectomy was developed in 1993 (16), initially only for small benign lesions and recently for lesions >5 cm and even malignancies (17). This technique

gained popularity because it allows direct access to the gland and avoids unexpected lesions to intra-abdominal organs. In some academic centers (18), it has become the surgery of choice for adrenalectomy, although it requires a strict working space and an unusual anatomical recognition compared with transperitoneal access.

Of note, retroperitoneal adrenalectomy may be especially useful for treating cases with inherited PHEO, especially those with multiple endocrine neoplasia type 2 (MEN2A) in which PHEO frequently occurs concomitantly with medullary thyroid carcinoma and primary hyperparathyroidism. The prevalence of PHEO with MEN2A is 50% and frequently occurs bilaterally (50–60%), either synchronic or asynchronously (19). Recently, PHEO was reported to be highly prevalent in MEN2A patients harboring the double 634/791 mutation in the *RET* proto-oncogene (20).

In the present paper, we briefly described the revised retroperitoneoscopic adrenalectomy technique and the outcomes of adrenal lesions that have been operated on using this approach.

## Surgical technique

After confirming the diagnosis of PHEO, the patient needs to be clinically prepared for adrenalectomy in order to avoid the possibility of a dangerous intraoperative adrenal crisis. This preparation usually requires at least 4–6 weeks of using either amlodipine, or preferentially prazosin, a selective  $\alpha_1$ -antagonist. Initially, 1 mg/day is given at bedtime for 10–15 days. Then, 1 mg of prazosin should be added for 7–10 days until a dose of approximately

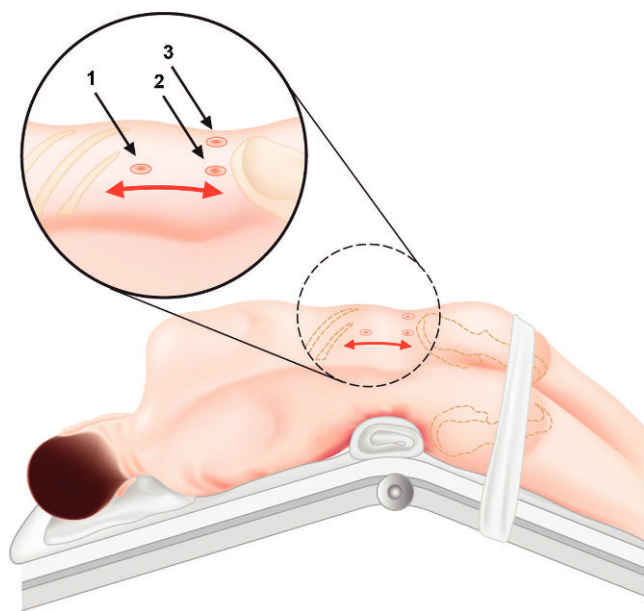
This is an Open Access article distributed under the terms of the Creative Commons Attribution Non-Commercial License (<http://creativecommons.org/licenses/by-nc/3.0/>) which permits unrestricted noncommercial use, distribution, and reproduction in any medium, provided the original work is properly cited.

No potential conflict of interest was reported.

10 mg is reached. Prazosin has a short effective lifespan and, thus, should be given two or three times a day. Also, the ingestion of large amounts of liquids (>2.5 L/day) and a salty diet in order to expand the extracellular volume and avoid possible postsurgical hypotension or even hypovolemic shock is recommended (21,22).  $\beta$ -adrenoceptor antagonists (e.g., propranolol) should be added only 2–3 days before surgery, if necessary (e.g., the occurrence of tachycardia) (1,2,23). Usually, computerized tomography or magnetic resonance imaging has been already performed during the diagnostic phase of PHEO and will be useful for choosing specific surgical techniques. For the success of the surgical procedure, it is crucial to obtain a careful surgical history of all PHEO patients who are candidates for retroperitoneoscopic adrenalectomy. The reason for this is because a previous retroperitoneal intervention may represent a relative contraindication for this procedure. Conversely, previous upper abdominal surgery can make the procedure more attractive.

Surgery is performed with the patient under general anesthesia, with laryngeal intubation and assisted ventilation. A peripheral arterial line and a central venous catheter are inserted for cardiovascular control in all cases. An orogastric tube is routinely placed for the procedure only. The bladder remains empty by using a Foley catheter (RÜSCH®, Teleflex).

There are two basic positions that the patient should be placed into for a retroperitoneoscopic adrenalectomy: the lateral posterior and the prone position (24–28), and the surgeon should choose which position he/she prefers. In the lateral position, the patient is placed in total lateral decubitus with hyperextension of the affected side by elevating the lumbar bridge of the table and straightening the ipsilateral lower extremity in order to increase the space between the 12th costal arch and the iliac crest (18,28,29) (Figure 1). In the prone position, the patient is placed in a



**Figure 1** - Lateral position. The patient is placed in a hyperextension position. 1 – first incision is made below the last rib to create a retroperitoneal space; 2 – second port, 1 cm above the iliac crest, where the 0° endoscope enters; 3 – working port located 4 cm anterior to trocar number 2.

half-jackknife position, with the hip, joints and knees bent at 75–90° (Figure 2). The aim of this position is to increase the space between the last rib and the iliac crest.

The first incision is usually made just below or at the tip of the last rib, and the retroperitoneal space is reached by sharp or blunt dissection of the abdominal wall. A retroperitoneal space can be created using the index finger or balloon dissection, and the latter option is more suitable for obese patients. Other ports can be placed under finger guidance or by retroperitoneoscopic direct vision. A Hasson-type trocar or a blunt-tip trocar (BLUNT TIP®, Covidien) with an inflatable balloon can be used during the first incision in order to avoid or minimize gas leakage. The distribution of the laparoscopic ports varies among different institutions, and the endoscopic angle depends on the preference of the surgeon. Care should be taken to avoid the subcostal nerves. CO<sub>2</sub> pressure can usually be maintained between 10 and 15 mmHg, although a CO<sub>2</sub> pressure of 20–25 mmHg can be safely applied for patients in the prone position (30).

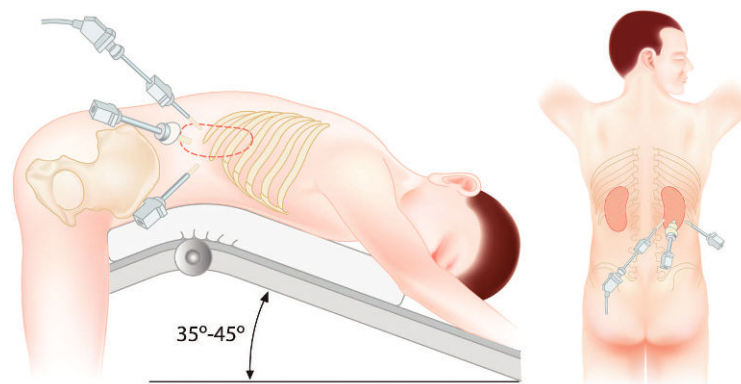
After reaching the retroperitoneum, the surgical tactics involve the identification of psoas muscle for special orientation and either vascular access to the adrenal gland by following the inferior vena cava (on the right side) or the renal vein (on the left side), or posterior access to the adrenal by opening Gerota's fascia, mainly for the prone position. For the right side, the adrenal vein is usually situated posterolaterally to the inferior vena cava (Figure 3); for the left side, the adrenal vein is usually located on the upper surface of the renal vein (Figure 4). In case of PHEO, it is recommended to perform an early ligation of the main adrenal vein in order to minimize potential intraoperative hypertension due to catecholamine release during adrenal manipulation (31–33). Alternatively, some prefer to dissect the gland before adrenal vein ligation (34–36). The inferior and medial aspects of the gland are then dissected, and the small inferior and medial adrenal arteries and veins are separated by clips or sectioned using ultrasonic scissors (Figures 5 and 6). It is important to always avoid direct gland and tumor manipulation during the dissection. The superior aspect of the gland is dissected, followed by the lateral aspects, which are usually poorly vascularized. The specimen is extracted through the first incision using an appropriate retrieval bag system. Placing an aspirative drain for the retroperitoneal space is optional, and the trocars are removed under retroperitoneoscopic observation. The fascia of the port sites that are more than 10 mm are closed, followed by skin closure using an absorbable material.

## RESULTS

There are few studies concerning the retroperitoneal approach to treat adrenal PHEO, although most of them are not exclusively related to PHEO cases. Earlier studies were based on case series to show the feasibility and safety of this type of treatment. Also, comparative studies of the transperitoneal and retroperitoneal routes, and between the open and retroperitoneal routes, are available, as commented below.

## Clinical series

Laparoscopy itself has been shown to be a safe procedure and does not increase the cardiovascular risk of treating patients with PHEO (37–39). Some studies do not report any difference between open and laparoscopic approaches in regards to intraoperative hemodynamic changes and



**Figure 2** - Prone position. The patient is placed in a half-jackknife position with the hip, joints and the knees bent 75–90°. Trocar disposition and camera entrance are illustrated.

complications (37). Nau et al. (38) compared these parameters for the transperitoneal laparoscopic approach to treat PHEO and other adrenal diseases and detected only an increased use of antihypertensive drugs during the procedure for patients with PHEO ( $p < 0.001$ ). They did not find any other increased cardiovascular risk or complication in this group, even when considering the fact that PHEO patients present a significantly higher classification according to the American Society of Anesthesiologists (ASA) ( $p < 0.001$ ). It is important to stress that hypertension must be controlled before the procedure in order to achieve a positive clinical outcome.

Walz et al. described a series of 560 retroperitoneal adrenalectomies that were performed via the posterior approach; 119 of the procedures were for PHEO (30). The mean operative time of all of these cases was 67 min; the operative time for PHEO was significantly longer than for other adrenal diseases (80 vs. 62 min, respectively;  $p < 0.001$ ). There was one conversion to the laparoscopic lateral approach due to severe obesity among the PHEO cases. Overall, intraoperative complications were noticed in 4.2% of cases; severe bleeding that required a transfusion occurred in one patient who was undergoing a partial adrenalectomy. The main complication encountered during follow-up was hypoesthesia or relaxation of the abdominal wall in 8.5% of the 560 cases.

In 2007, Zhang et al. (18) published a series of 824 retroperitoneoscopic adrenalectomies that were performed via the lateral retroperitoneal approach, of which 62 of these procedures were for PHEO. In these cases, there was one conversion to open surgery (1.6%) due to large lesions and adhesions. The mean operative time for all of these cases was 45 min. No major bleeding or transfusion was reported.

A prospective study conducted by Walz et al. (39) treated both PHEO and paraganglioma patients. Of 161 treated tumors, 113 (70.2%) were unilateral PHEOs that were treated by retroperitoneoscopy. The median operative time in these cases was 82 min (range: 20–300 min); for the first half of these patients, the median time for the procedure was 110 min, but the second half required only 55 min ( $p < 0.001$ ).

Li et al. (36) described the largest retrospective series specifically for describing lateral retroperitoneoscopic adrenalectomy that included 131 procedures, including 11 for extra-adrenal PHEO. The authors divided their experiences into three phases and compared their laparoscopic data to

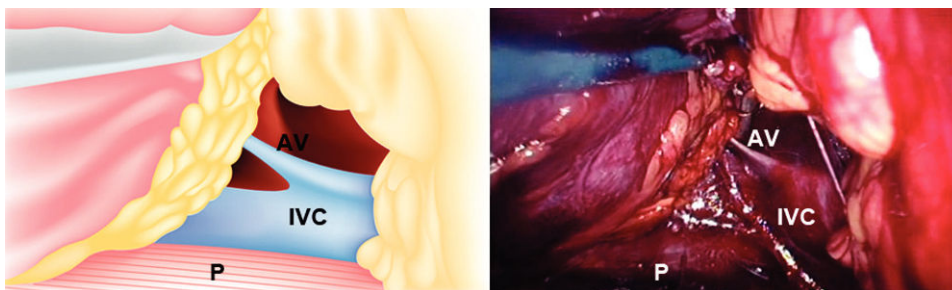
open-access cases. In the first phase, laparoscopy accounted for 37% of the cases, and in the third phase laparoscopy was responsible for 83% of the cases. The median operative times in the first, second, and third phases were 105, 85, and 75 min, respectively. Median blood loss in the same phases was 450, 140, and 70 mL, respectively. Fourteen patients (10.7%) had no complications and most of them (71.4%) were considered Clavien grade I complications.

### Comparative Studies

A non-randomized retrospective study comparing retroperitoneal access to the open approach for adrenal PHEO (40) reported statistical differences that favored the retroperitoneal access when comparing mean blood loss (140 vs. 592 mL,  $p < 0.05$ ), mean hospital stay (4.4 vs. 9.8 days,  $p < 0.05$ ), and analgesic requirements. The authors concluded that, although technically demanding, retroperitoneoscopic adrenalectomy is a good option for the treatment of PHEO.

Other studies have compared the transperitoneal and retroperitoneal routes for adrenalectomy, but not specifically for PHEO cases. Baba et al. (41) compared three approaches for reaching the adrenal gland: transperitoneal, lateral retroperitoneal, and lumbar retroperitoneal access. The lumbar approach demonstrated the shortest average operative time: 142 versus 194 min for the lateral retroperitoneal route and 252 min for the transperitoneal route ( $p < 0.02$ ). Of note, the first alternative allows direct access to the gland, with no need to retract other abdominal or retroperitoneal organs. Furthermore, blood loss was significantly lower for both lateral retroperitoneal (22 mL) and lumbar access (32 mL) than transperitoneal access (101 mL) ( $p < 0.01$ ). In 1998, Miyake et al. (42) retrospectively compared these surgical routes of access and verified that operative times were longer and postoperative pain was higher for transperitoneal laparoscopy, although there was no statistical difference. Suzuki et al. (24) compared three different approaches to the adrenal gland: anterior transperitoneal, lateral transperitoneal, and lateral retroperitoneal. They found a mean operative time of 175, 118, and 176 min, respectively. The lateral transperitoneal approach was significantly favored ( $p < 0.0001$ ). No significant difference was found regarding blood loss. Shoulder pain and paralytic ileus occurred in patients of all groups, but in the retroperitoneal approach it occurred only when the peritoneum was opened. Suzuki et al. (24) recommended that experienced surgeons should treat small lesions using





**Figure 3** - Right-side retroperitoneoscopic view. AV: adrenal vein. IVC: inferior vena cava. P: psoas muscle.

the minimally invasive retroperitoneal approach to avoid complications related to peritoneum insufflation.

Other authors did not find any significant differences regarding transperitoneal versus retroperitoneal access. Fernandez-Cruz et al. (43) documented no difference regarding blood loss or hemodynamic parameters between both approaches, in addition to operative time, blood loss and complications. Gockel et al. (33) reported that the median operative time is lower in the transperitoneal approach (85 min) compared with the retroperitoneal approach (120 min) ( $p<0.001$ ), particularly when the right side was compared. Also, a shorter learning curve was observed for the transperitoneal approach compared with the retroperitoneal approach. These results were explained by earlier recognition of anatomic landmarks during transperitoneal access.

Rubinstein et al. (44) conducted a randomized prospective comparison between transperitoneal and retroperitoneal routes for adrenalectomy. Patients from both groups were comparable with respect to age, body mass index, tumor size, and ASA classification, and no significant differences were noticed. Thus, median operative time, blood loss, and specimen weight were similar in both groups, as well as analgesic requirements, hospital stay, and complication rates. The mean convalescence time was 4.7 weeks for the transperitoneal approach and 2.3 weeks for the retroperitoneal approach ( $p=0.02$ ). Two patients in the transperitoneal group developed with port site-related hernias.

A retrospective study comparing the transperitoneal and retroperitoneal approaches for treating PHEO analyzed 99 patients with unilateral adrenal lesions and comparable demographic data (45). There were 40 patients in the transperitoneal group and 59 in the retroperitoneal group.

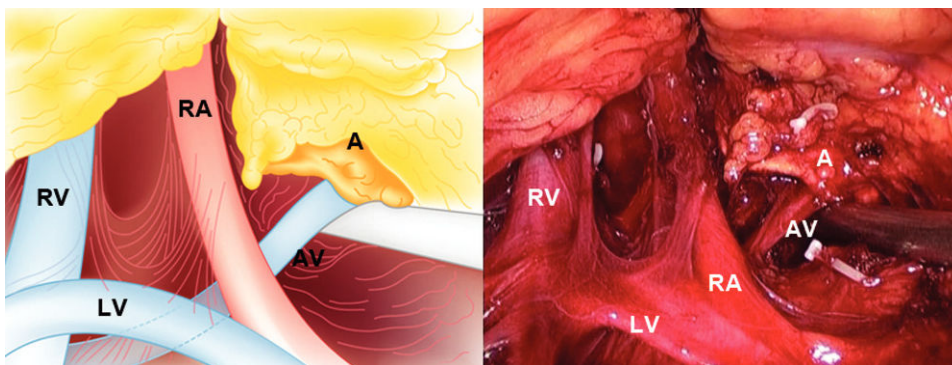
The mean operative time (117 vs. 84 min, respectively;  $p<0.05$ ), blood loss (340 vs. 200 ml, respectively;  $p<0.05$ ), hospital stay (7.8 vs. 4.8 days, respectively;  $p<0.05$ ), and complication rates were significantly higher in the transperitoneal group. Blood pressure fluctuations, long-term blood pressure control, metabolic and imaging follow-up were similar in both groups; however, the recurrence rates were not verified.

### Special situations

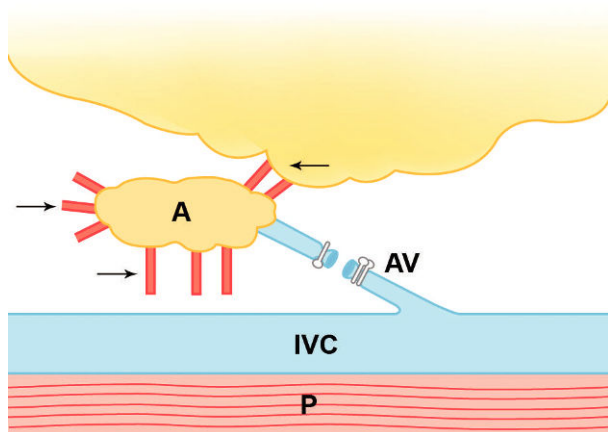
Previous abdominal surgery or radiation therapy does not seem to affect the clinical outcome of the retroperitoneal approach. Viterbo et al. (46) compared retroperitoneal access to the kidneys and adrenals in patients with and without previous abdominal surgery but was unable to verify significant differences regarding operative time, blood loss, or convalescence. Retroperitoneal access is the preferred route for patients with a history of prior abdominal surgery as a way for surgeons to avoid visceral and vascular complications (10,28,44,47,48).

Obese patients with PHEO can be preferentially managed with retroperitoneoscopic adrenalectomy. There are two reported cases that clearly document the feasibility and relative safety of this approach (49,50). Because of the direct access to the gland, some authors consider obesity as an indication to perform the retroperitoneal approach (28,44,51). A high body mass index is correlated with a longer operative time, mainly for those  $>25 \text{ kg/m}^2$  (33,51).

Tumor size must also be taken into consideration when planning the surgical approach. Due to more restricted space, retroperitoneoscopy is usually indicated when adrenal tumors are  $<7 \text{ cm}$  (43,52), although some experienced centers have operated on larger tumors (18,30,53,54).



**Figure 4** - Left-side retroperitoneoscopic view. A: adrenal. AV: adrenal vein. LV: lumbar vein. RA: renal artery. RV: renal vein. Note the laparoscopic clips for the inferior and medial adrenal arteries.

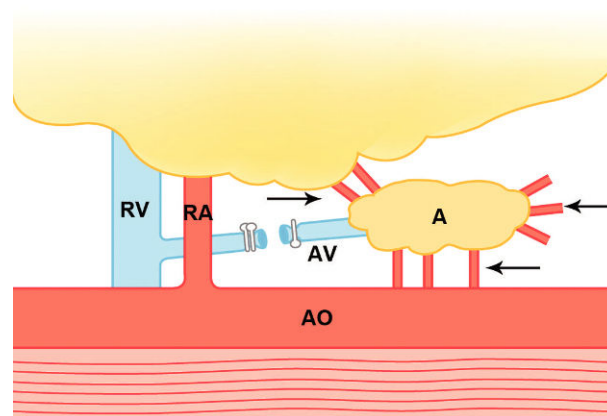


**Figure 5** - Right-side retroperitoneoscopic adrenalectomy after adrenal vein section. Adrenal arteries indicated by the arrows. A: adrenal. AV: adrenal vein. IVC: inferior vena cava. P: psoas muscle.

For both approaches, tumor size >5 cm can increase the operative times (33,55). When there is suspicion of malignant PHEO, the surgical procedure must be considered. In such cases, the open procedure should be favored over the laparoscopic approach (56), mainly if radiological findings indicate local invasion or, as is the case of large tumors (57), some studies document good outcomes in cases of malignant, organ-confined tumors (52,57). Also, there is a relative contraindication for retroperitoneoscopy if there has been previous retroperitoneal manipulation or scarring (44). In these cases, the transperitoneal approach would be more suitable.

Laparoscopic adrenalectomy can also be performed on children. Most cases are conducted by the transperitoneal approach. A non-randomized retrospective multicenter study showed that this method is a feasible and secure procedure for young patients, with a 10% conversion rate (58). Furthermore, when referring to the retroperitoneal approach, there are few studies indicating that the surgical positions for adults can also be applied to children. However, there are no available data related to retroperitoneal treatment specifically for PHEO. Most cases are included in non-specific retroperitoneal adrenalectomy series (59,60), or even included in adult series, indicating the feasibility of the method with no major complications, although right-sided procedures can be technically more demanding (61).

An important issue concerning the retroperitoneoscopic technique is how to teach the procedure to those who do not routinely perform it. A study conducted by Barczynski and Walz (62) reported the experience of a pioneering group in this technique who introduced it to an inexperienced group. The experienced group continuously supervised the student group and offered direct surgical assistance during the initial cases. They compared the first cases of each group and found a significant impact on the operative time and conversions in the learning group. The recommendation was that previous visits and contacts to experienced centers, as well as initial assistance from an experienced surgeon, can flatten the learning curve of the apprentice surgeons, as reflected by safer outcomes for patients. It was estimated that the apprentice had to operate on 20–25 cases under



**Figure 6** - Left-side retroperitoneoscopic adrenalectomy after adrenal vein section. Adrenal arteries indicated by the arrows. A: adrenal. AO: aorta. AV: adrenal vein. RA: renal artery. RV: renal vein.

supervision before being able to perform the procedure in under a mean operative time of 90 min.

Retroperitoneoscopic adrenalectomy can be indicated for the treatment of PHEO with the same peri-operative outcomes as the transperitoneal approach because it allows direct access to the adrenal glands with no increase in the operative risks. Although technically more demanding than the transperitoneal approach, retroperitoneoscopy can shorten the mean operative time, which is useful for cases of PHEO in order to minimize intraoperative hemodynamic changes. Blood loss and convalescence time can be also reduced by this approach. There is no absolute indication for using either the transperitoneal or retroperitoneal approaches; however, the latter procedure may be the better option for cases with a previous abdominal surgeries and obese patients.

## AUTHOR CONTRIBUTIONS

Hisano M, Vicentini FC, and Srougi M have equal participation in this review article. All three authors worked on technical aspect of the surgery, as well as prepared the illustrations, and reviewed the published literature of the subject.

## REFERENCES

- Petri BJ, van Eijck CH, de Herder WW, Wagner A, de Krijger RR. Pheochromocytomas and sympathetic paragangliomas. *Br J Surg.* 2009;96(12):1381–92, <http://dx.doi.org/10.1002/bjs.6821>.
- Lenders JW, Eisenhofer G, Mannelli M, Pacak K. Pheochromocytoma. *Lancet.* 2005;366(9486):665–75, [http://dx.doi.org/10.1016/S0140-6736\(05\)67139-5](http://dx.doi.org/10.1016/S0140-6736(05)67139-5).
- Gagner M, Lacroix A, Bolte E. Laparoscopic adrenalectomy in Cushing's syndrome and pheochromocytoma. *N Engl J Med.* 1992;327(14):1033.
- Winfield HN, Hamilton BD, Bravo EL, Novick AC. Laparoscopic adrenalectomy: the preferred choice? A comparison to open adrenalectomy. *J Urol.* 1998;160(2):325–9.
- Edwin B, Kazaryan AM, Mala T, Pfeffer PF, Tonnessen TI, Fosse E. Laparoscopic and open surgery for pheochromocytoma. *BMC Surg.* 2001;1:2, <http://dx.doi.org/10.1186/1471-2482-1-2>.
- Castilho LN, Medeiros PJ, Mitre AI, Denes FT, Lucon AM, Arap S. Pheochromocytoma treated by laparoscopic surgery. *Rev Hosp Clin Fac Med Sao Paulo.* 2000;55(3):93–100.
- Hirano D, Minei S, Yamaguchi K, Yoshikawa T, Hachiya T, Yoshida T, et al. Retroperitoneoscopic adrenalectomy for adrenal tumors via a single large port. *J Endourol.* 2005;19(7):788–92, <http://dx.doi.org/10.1089/end.2005.19.788>.
- Walz MK, Alesina PF. Single access retroperitoneoscopic adrenalectomy (SARA): one step beyond in endocrine surgery. *Langenbecks Arch Surg.* 2009;394(3):447–50, <http://dx.doi.org/10.1007/s00423-008-0418-z>.
- Perretta S, Allemann P, Asakuma M, Dallemagne B, Marescaux J. Adrenalectomy using natural orifice transluminal endoscopic surgery

- (NOTES): a transvaginal retroperitoneal approach. *Surg Endosc*. 2009;23(6):1390, <http://dx.doi.org/10.1007/s00464-009-0367-9>.
10. Allemann P, Perretta S, Marescaux J. Surgical access to the adrenal gland: the quest for a "no visible scar" approach. *Surg Oncol*. 2009;18(2):131-7, <http://dx.doi.org/10.1016/j.suronc.2008.12.005>.
  11. Bartel M. Die Retroperitoneoskopie. Eine endoskopische Methode zur Inspektion und biopsischen Untersuchung des retroperitonealen Raumes. [Retroperitoneoscopy. An endoscopic method for inspection and biopsic examination of the retroperitoneal space]. *Zentralbl Chir*. 1969;94(12):377-83.
  12. Fantoni PA, Mondina P, Tognoli S, Astuni M, Baroni C, Anardo G, et al. Retroperitoneoscopy for biopsy of pelvic and medium-low para-aortic lymph nodes and tissues. *Int Surg*. 1983;68(2):157-60.
  13. Zhila VV, Rublevskii VP, Shodmonova ZR, Chernenko PS. Operativnye vmeshatel'stva na pochkakh i mochetochnikakh s ispol'zovaniem retroperitoneoskopa. [Operative surgery of the kidneys and ureters using a retroperitoneoscopy]. *Klin Khir*. 1990(12):34-5.
  14. Meretyk S, Clayman RV, Myers JA. Retroperitoneoscopy: foreign body retrieval. *J Urol*. 1992;147(6):1608-11.
  15. Gaur DD. Laparoscopic operative retroperitoneoscopy: use of a new device. *J Urol*. 1992;148(4):1137-9.
  16. Brunt LM, Molmenti EP, Kerbl K, Soper NJ, Stone AM, Clayman RV. Retroperitoneal endoscopic adrenalectomy: an experimental study. *Surg Laparosc Endosc*. 1993;3(4):300-6.
  17. Rosoff JS, Raman JD, Del Pizzo JJ. Laparoscopic adrenalectomy for large adrenal masses. *Curr Urol Rep*. 2008;9(1):73-9, <http://dx.doi.org/10.1007/s11934-008-0014-3>.
  18. Zhang X, Fu B, Lang B, Zhang J, Xu K, Li HZ, et al. Technique of anatomical retroperitoneoscopic adrenalectomy with report of 800 cases. *J Urol*. 2007;177(4):1254-7, <http://dx.doi.org/10.1016/j.juro.2006.11.098>.
  19. Toledo SP, dos Santos MA, Toledo Rde A, Lourenco DM, Jr. Impact of RET proto-oncogene analysis on the clinical management of multiple endocrine neoplasia type 2. *Clinics*. 2006;61(1):59-70, <http://dx.doi.org/10.1590/S1807-59322006000100011>.
  20. Toledo RA, Wagner NM, Coutinho FL, Lourenco DM, Jr., Azevedo JA, Longuini VC, et al. High penetrance of pheochromocytoma associated with the novel C634Y/Y791F double germline mutation in the RET protooncogene. *J Clin Endocrinol Metab*. 2010;95(3):1318-27, <http://dx.doi.org/10.1210/jc.2009-1355>.
  21. Pereira MA, Souza BF, Freire DS, Lucon AM. Feocromocitoma [Pheochromocytoma]. *Arq Bras Endocrinol Metab*. 2004;48(5):751-75, <http://dx.doi.org/10.1590/S0004-27302004000500022>.
  22. Pacak K. Preoperative management of the pheochromocytoma patient. *J Clin Endocrinol Metab*. 2007;92(11):4069-79, <http://dx.doi.org/10.1210/jc.2007-1720>.
  23. van der Horst-Schrivers AN, Kerstens MN, Wolffenbuttel BH. Preoperative pharmacological management of phaeochromocytoma. *Neth J Med*. 2006;64(8):290-5.
  24. Suzuki K, Kageyama S, Hirano Y, Ushiyama T, Rajamahantya S, Fujita K. Comparison of 3 surgical approaches to laparoscopic adrenalectomy: a nonrandomized, background matched analysis. *J Urol*. 2001;166(2):437-43, [http://dx.doi.org/10.1016/S0022-5347\(05\)65959-9](http://dx.doi.org/10.1016/S0022-5347(05)65959-9).
  25. Walz MK, Peitgen K, Krause U, Eigler FW. Die dorsale retroperitoneoskopische Adrenalectomie: eine neue operative Technik [Dorsal retroperitoneoscopic adrenalectomy: a new surgical technique]. *Zentralbl Chir*. 1995;120(1):53-8.
  26. Walz MK, Peitgen K, Walz MV, Hoermann R, Saller B, Giebler RM, et al. Posterior retroperitoneoscopic adrenalectomy: lessons learned within five years. *World J Surg*. 2001;25(6):728-34, <http://dx.doi.org/10.1007/s00268-001-0023-6>.
  27. Baba S, Ito K, Yanaiharu H, Nagata H, Murai M, Iwamura M. Retroperitoneoscopic adrenalectomy by a lumbodorsal approach: clinical experience with solo surgery. *World J Urol*. 1999;17(1):54-8, <http://dx.doi.org/10.1007/s003450050105>.
  28. Sung GT, Hsu TH, Gill IS. Retroperitoneoscopic adrenalectomy: lateral approach. *J Endourol*. 2001;15(5):505-11; discussion 11-2, <http://dx.doi.org/10.1089/089277901750299302>.
  29. Suzuki K. Laparoscopic adrenalectomy: retroperitoneal approach. *Urol Clin North Am*. 2001;28(1):85-95, [http://dx.doi.org/10.1016/S0094-0143\(01\)80010-0](http://dx.doi.org/10.1016/S0094-0143(01)80010-0).
  30. Walz MK, Alesina PF, Wenger FA, Deligiannis A, Szuczik E, Petersenn S, et al. Posterior retroperitoneoscopic adrenalectomy: results of 560 procedures in 520 patients. *Surgery*. 2006;140(6):943-8; discussion 8-50, <http://dx.doi.org/10.1016/j.surg.2006.07.039>.
  31. Salomon L, Rabii R, Soulie M, Mouly P, Hoznek A, Cicco A, et al. Experience with retroperitoneal laparoscopic adrenalectomy for pheochromocytoma. *J Urol*. 2001;165(6 Pt 1):1871-4.
  32. Janetschek G, Neumann HP. Laparoscopic surgery for pheochromocytoma. *Urol Clin North Am*. 2001;28(1):97-105, [http://dx.doi.org/10.1016/S0094-0143\(01\)80011-2](http://dx.doi.org/10.1016/S0094-0143(01)80011-2).
  33. Gockel I, Kneist W, Heintz A, Beyer J, Junginger T. Endoscopic adrenalectomy: an analysis of the transperitoneal and retroperitoneal approaches and results of a prospective follow-up study. *Surg Endosc*. 2005;19(4):569-73, <http://dx.doi.org/10.1007/s00464-004-9085-5>.
  34. Walz MK, Peitgen K, Hoermann R, Giebler RM, Mann K, Eigler FW. Posterior retroperitoneoscopy as a new minimally invasive approach for adrenalectomy: results of 30 adrenalectomies in 27 patients. *World J Surg*. 1996;20(7):769-74, <http://dx.doi.org/10.1007/s002689900117>.
  35. Zhang X, Lang B, Ouyang JZ, Fu B, Zhang J, Xu K, et al. Retroperitoneoscopic adrenalectomy without previous control of adrenal vein is feasible and safe for pheochromocytoma. *Urology*. 2007;69(5):849-53, <http://dx.doi.org/10.1016/j.urol.2007.01.078>.
  36. Li H, Yan W, Ji Z, Xu W, Wang H, Ting W, et al. Experience of retroperitoneal laparoscopic treatment on pheochromocytoma. *Urology*. 2011;77(1):131-5, <http://dx.doi.org/10.1016/j.urol.2010.03.094>.
  37. Tiberio GA, Baiocchi GL, Arru L, Agabiti Rosei C, De Ponti S, Matheis A, et al. Prospective randomized comparison of laparoscopic versus open adrenalectomy for sporadic pheochromocytoma. *Surg Endosc*. 2008;22(6):1435-9, <http://dx.doi.org/10.1007/s00464-008-9904-1>.
  38. Nau P, Demyttenaere S, Muscarella P, Narula V, Hazey JW, Ellison EC, et al. Pheochromocytoma does not increase risk in laparoscopic adrenalectomy. *Surg Endosc*. 2010;24(11):2760-4, <http://dx.doi.org/10.1007/s00464-010-1042-x>.
  39. Walz MK, Alesina PF, Wenger FA, Koch JA, Neumann HP, Petersenn S, et al. Laparoscopic and retroperitoneoscopic treatment of pheochromocytomas and retroperitoneal paragangliomas: results of 161 tumors in 126 patients. *World J Surg*. 2006;30(5):899-908, <http://dx.doi.org/10.1007/s00268-005-0373-6>.
  40. Hemal AK, Kumar R, Misra MC, Gupta NP, Chumber S. Retroperitoneoscopic adrenalectomy for pheochromocytoma: comparison with open surgery. *JSLs*. 2003;7(4):341-5.
  41. Baba S, Miyajima A, Uchida A, Asanuma H, Miyakawa A, Murai M. A posterior lumbar approach for retroperitoneoscopic adrenalectomy: assessment of surgical efficacy. *Urology*. 1997;50(1):19-24, [http://dx.doi.org/10.1016/S0090-4295\(97\)00119-2](http://dx.doi.org/10.1016/S0090-4295(97)00119-2).
  42. Miyake O, Yoshimura K, Yoshioka T, Honda M, Kokado Y, Miki T, et al. Laparoscopic adrenalectomy. Comparison of the transperitoneal and retroperitoneal approach. *Eur Urol*. 1998;33(3):303-7.
  43. Fernandez-Cruz L, Saenz A, Taura P, Benarroch G, Astudillo E, Sabater L. Retroperitoneal approach in laparoscopic adrenalectomy: is it advantageous? *Surg Endosc*. 1999;13(1):86-90, <http://dx.doi.org/10.1007/s004649900907>.
  44. Rubinstein M, Gill IS, Aron M, Kilciler M, Meraney AM, Finelli A, et al. Prospective, randomized comparison of transperitoneal versus retroperitoneal laparoscopic adrenalectomy. *J Urol*. 2005;174(2):442-5, <http://dx.doi.org/10.1097/01.ju.0000165336.44836.2d>.
  45. Li QY, Li F. Laparoscopic adrenalectomy in pheochromocytoma: retroperitoneal approach versus transperitoneal approach. *J Endourol*. 2010;24(9):1441-5, <http://dx.doi.org/10.1089/end.2010.0065>.
  46. Viterbo R, Greenberg RE, Al-Saleem T, Uzzo RG. Prior abdominal surgery and radiation do not complicate the retroperitoneoscopic approach to the kidney or adrenal gland. *J Urol*. 2005;174(2):446-50, <http://dx.doi.org/10.1097/01.ju.0000165654.34635.ad>.
  47. Cadeddu JA, Chan DY, Hedican SP, Lee BR, Moore RG, Kavoussi LR, et al. Retroperitoneal access for transperitoneal laparoscopy in patients at high risk for intra-abdominal scarring. *J Endourol*. 1999;13(8):567-70, <http://dx.doi.org/10.1089/end.1999.13.567>.
  48. Schreinemakers JM, Kiela GJ, Valk GD, Vriens MR, Rinkes IH. Retroperitoneal endoscopic adrenalectomy is safe and effective. *Br J Surg*. 2010;97(11):1667-72, <http://dx.doi.org/10.1002/bjs.7191>.
  49. Dogra PN, Gautam G, Ansari MS. Retroperitoneoscopic adrenalectomy for pheochromocytoma in a morbidly obese patient: a case report. *Int Urol Nephrol*. 2007;39(1):99-101, <http://dx.doi.org/10.1007/s11255-005-4968-5>.
  50. Varela JE. Retroperitoneoscopic adrenalectomy for pheochromocytoma in a morbidly obese. *Obes Surg*. 2009;19(8):1180-2, <http://dx.doi.org/10.1007/s11695-009-9805-y>.
  51. Lezoche E, Guerrieri M, Feliciotti F, Paganini AM, Perretta S, Baldarelli M, et al. Anterior, lateral, and posterior retroperitoneal approaches in endoscopic adrenalectomy. *Surg Endosc*. 2002;16(1):96-9, <http://dx.doi.org/10.1007/s004640090043>.
  52. Zacharias M, Haese A, Jurczok A, Stolzenburg JU, Fornara P. Transperitoneal laparoscopic adrenalectomy: outline of the preoperative management, surgical approach, and outcome. *Eur Urol*. 2006;49(3):448-59, <http://dx.doi.org/10.1016/j.eururo.2006.01.014>.
  53. Hobart MG, Gill IS, Schweizer D, Sung GT, Bravo EL. Laparoscopic adrenalectomy for large-volume (> or = 5 cm) adrenal masses. *J Endourol*. 2000;14(2):149-54, <http://dx.doi.org/10.1089/end.2000.14.149>.
  54. Henry JF, Defechereux T, Gramatica L, Raffaelli M. Should laparoscopic approach be proposed for large and/or potentially malignant adrenal tumors? *Langenbecks Arch Surg*. 1999;384(4):366-9, <http://dx.doi.org/10.1007/s004230050215>.
  55. Sharma R, Ganpule A, Veeramani M, Sabnis RB, Desai M. Laparoscopic management of adrenal lesions larger than 5 cm in diameter. *Urol J*. 2009;6(4):254-9.
  56. Gagner M, Pomp A, Heniford BT, Pharend D, Lacroix A. Laparoscopic adrenalectomy: lessons learned from 100 consecutive procedures. *Ann Surg*. 1997;226(3):238-46; discussion 46-7.

57. Heniford BT, Arca MJ, Walsh RM, Gill IS. Laparoscopic adrenalectomy for cancer. *Semin Surg Oncol*. 1999;16(4):293–306, [http://dx.doi.org/10.1002/\(SICI\)1098-2388\(199906\)16:4<293::AID-SSU4>3.0.CO;2-E](http://dx.doi.org/10.1002/(SICI)1098-2388(199906)16:4<293::AID-SSU4>3.0.CO;2-E).
58. St Peter SD, Valusek PA, Hill S, Wulkan ML, Shah SS, Ferro MM, et al. Laparoscopic adrenalectomy in children: a multicenter experience. *J Laparoendosc Adv Surg Tech A*. 2011;21(7):647–9, <http://dx.doi.org/10.1089/lap.2011.0141>.
59. Eassa W, El-Sherbiny M, Jednak R, Capolicchio JP. The anterior approach to retroperitoneoscopic adrenalectomy in children: Technique. *J Pediatr Urol*. 2012;8(1):35–9, <http://dx.doi.org/10.1016/j.jpuirol.2010.12.007>.
60. Lopez PJ, Pierro A, Curry JI, Mushtaq I. Retroperitoneoscopic adrenalectomy: an early institutional experience. *J Pediatr Urol*. 2007;3(2):96–9, <http://dx.doi.org/10.1016/j.jpuirol.2006.05.010>.
61. Shanberg AM, Sanderson K, Rajpoot D, Duel B. Laparoscopic retroperitoneal renal and adrenal surgery in children. *BJU Int*. 2001;87(6):521–4, <http://dx.doi.org/10.1046/j.1464-410X.2001.00099.x>.
62. Barczynski M, Konturek A, Golkowski F, Cichon S, Huszno B, Peitgen K, et al. Posterior retroperitoneoscopic adrenalectomy: a comparison between the initial experience in the invention phase and introductory phase of the new surgical technique. *World J Surg*. 2007;31(1):65–71, <http://dx.doi.org/10.1007/s00268-006-0083-8>.