

REVIEW

Surgical approach to medullary thyroid carcinoma associated with multiple endocrine neoplasia type 2

Marcos R. Tavares,¹ Sérgio P. A. Toledo,¹¹ Fábio L. M. Montenegro,¹ Raquel A. Moyses,¹ Rodrigo A. Toledo,¹¹ Tomoko Sekiya,¹¹ Claudio R. Cernea,¹ Lenine G. Brandão¹

¹Hospital das Clínicas da Faculdade de Medicina da Universidade de São Paulo, Head and Neck Surgery Division, São Paulo/SP, Brazil. ¹¹Hospital das Clínicas da Faculdade de Medicina da Universidade de São Paulo, Endocrine Division, São Paulo/SP, Brazil.

We briefly review the surgical approaches to medullary thyroid carcinoma associated with multiple endocrine neoplasia type 2 (medullary thyroid carcinoma/multiple endocrine neoplasia type 2). The recommended surgical approaches are usually based on the age of the affected carrier/patient, tumor staging and the specific *rearranged during transfection* codon mutation. We have focused mainly on young children with no apparent disease who are carrying a germline *rearranged during transfection* mutation. Successful management of medullary thyroid carcinoma in these cases depends on early diagnosis and treatment. Total thyroidectomy should be performed before 6 months of age in infants carrying the *rearranged during transfection* 918 codon mutation, by the age of 3 years in *rearranged during transfection* 634 mutation carriers, at 5 years of age in carriers with level 3 risk *rearranged during transfection* mutations, and by the age of 10 years in level 4 risk *rearranged during transfection* mutations. Patients with thyroid tumor >5 mm detected by ultrasound, and basal calcitonin levels >40 pg/ml, frequently have cervical and upper mediastinal lymph node metastasis. In the latter patients, total thyroidectomy should be complemented by extensive lymph node dissection. Also, we briefly review our data from a large familial medullary thyroid carcinoma genealogy harboring a germline *rearranged during transfection* Cys620Arg mutation. All 14 screened carriers of the *rearranged during transfection* Cys620Arg mutation who underwent total thyroidectomy before the age of 12 years presented persistently undetectable serum levels of calcitonin (<2 pg/ml) during the follow-up period of 2–6 years. Although it is recommended that preventive total thyroidectomy in *rearranged during transfection* codon 620 mutation carriers is performed before the age of 5 years, in this particular family the surgical intervention performed before the age of 12 years led to an apparent biochemical cure.

KEYWORDS: Carcinoma; Medullary; Multiple Endocrine Neoplasia; Surgery.

Tavares MR, Toledo SPA, Montenegro FLM, Moyses RA, Toledo RA, Sekiya T, et al. Surgical approach to medullary thyroid carcinoma associated with multiple endocrine neoplasia type 2. Clinics. 2012;67(S1):149-154.

E-mail: mtavares@apm.org.br

Tel.: 55 11 3061-7000

INTRODUCTION

In the era of genomic medicine, multiple endocrine neoplasia (MEN) represents a model paradigm of the strong impact of genetic testing on clinical practice (1–4). An example of this is the impressive impact of mutation analysis of the *RET* proto-oncogene, which leads to MEN type 2 (MEN2A), on the day-to-day activity of clinicians, endocrinologists, neck surgeons, and urologists (5,6). As a result of this, *RET* germline mutation carriers detected at an early age are able to undergo preventive total thyroidectomy (TT), which has a high “cure” rate. This surgical approach may ultimately lead to prevention of highly malignant medullary thyroid carcinoma (MTC), either in its inherited or sporadic (S-MTC) form (5–8).

The well-defined genetic origin of the condition and the possibility of prophylactic surgical treatment of MTC make it a model for early diagnosis, genetic counseling, surgical prevention and therapy, as well as cancer research (9,10). This uncommon tumor has its origin in the thyroid C-cells and accounts for 4–5% of all thyroid cancer tumors in the USA, and it is the main cause of death in MEN2 patients (11,12). MTC may occur as a dominant inherited condition caused by a germline mutation in the *RET* gene in 20–30% of cases of MEN2, although S-MTC is the more prevalent form of the disease.

MTC presents different levels of aggressiveness: (a) it is extremely aggressive and usually occurs during the first year of life in MEN2B (MTC, hyperparathyroidism, pheochromocytoma, and mucosal neuromas); (b) it is highly aggressive in MEN2A (MTC, hyperparathyroidism, and pheochromocytoma) mostly in cases harboring a *RET* 634 codon mutation; and (c) it is often moderately aggressive in familial MTC (FMTC), as well as in S-MTC (13). Therefore, the behavior of MTC in MEN2 may present extreme variations, ranging from an indolent MTC, as frequently seen in cases harboring intracellular “weak” mutations, to

This is an Open Access article distributed under the terms of the Creative Commons Attribution Non-Commercial License (<http://creativecommons.org/licenses/by-nc/3.0/>) which permits unrestricted noncommercial use, distribution, and reproduction in any medium, provided the original work is properly cited.

No potential conflict of interest was reported.

highly aggressive MTC in cases with *RET* mutations in codon 634 and mainly in codon 918 (5,14,15).

Lymph node metastasis in the neck and upper mediastinum is a frequent finding in MTC cases that are diagnosed late, and metastases are present in about 70% of MTC patients who have a palpable thyroid nodule (>1.0 cm diameter). At this stage of the disease, biochemical "cure" rates drop to 30% or less (16,17). Thus, in *RET* mutation carriers, all efforts should be focused on early diagnosis and surgical treatment of MTC (5,14,15). The only effective treatment for this condition is TT, although several drugs acting on the *RET* receptor protein kinase have been tested in clinical trials (18).

Calcitonin measurements

Calcitonin (Ct) is produced by thyroid C-cells and is the tumor marker for MTC. Currently, basal serum Ct measurements and the calcium-stimulated Ct test have been mainly used during the post-surgical follow-up of cases of inherited MTC (5,17). The calcium-stimulated Ct test may be used to predict MTC in patients who present without a thyroid nodule at ultrasound and who have repeatedly normal basal Ct values (males, <8.5 pg/ml; females, <5.0 pg/ml). The higher risk of MTC in cases with abnormally high Ct levels after a calcium-stimulation test could further support an indication for prophylactic TT, possibly with dissection of the central compartment of the neck. However, some specialists argue that calcium-stimulated Ct testing is rarely needed in the diagnosis or follow-up of MTC, because new Ct assays have high sensitivity and specificity, and detection values are as low as 1–2 pg/ml (15).

Conversely, Ct measurements may be highly helpful in the diagnosis of S-MTC cases, which are often diagnosed late. In this context, routine Ct measurements in patients with thyroid nodules may contribute to an earlier diagnosis of MTC, although the prevalence of MTC in thyroid nodules is about 1.0% (19,20).

Genetic testing

Genetic *RET* testing should be offered to all patients with MTC (6), since between 1% and 7% of apparently sporadic MTC cases harbor a germline *RET* mutation, and thus need to be reclassified as inherited cases. Also, genetic *RET* testing should be offered to all at-risk (50% risk) first-degree relatives of patients with familial MTC, in order to disclose potential carriers with positive mutations (1,5). Further to this, genetic testing should be offered to all cases with pheochromocytoma, and possibly to patients with hyperparathyroidism who are younger than 30 years of age (5,21). In at-risk relatives, genetic testing for MTC predisposition should be performed at a very early age, as prophylactic surgical intervention is able to prevent MTC in the vast majority, but not all, of the *RET*-positive mutation carriers who are below the age of 3–5 years (10).

Genetic *RET* testing is usually based on mutation analysis of seven hot-spot exons: 8, 10, 11, 13, 14, 15, and 16. It allows a genetic diagnosis at the pre-neoplastic early stage of MTC, which corresponds to thyroid C-cell hyperplasia (5,15).

Surgical approach

Our main aim is to focus on recommended surgical approaches in young children carrying a germline *RET* mutation.

Recommended age for prophylactic thyroid surgery. The age at which TT in *RET*-positive mutation carriers is performed plays a crucial role in the success of MTC treatment. The recommended ages for TT in MEN2 are presently well defined and they are based on the strong genotype-phenotype correlation in MEN2 (1,5,15). Thus, surgery depends basically on the *RET* codon mutation involved, although the behavior of the disease in a specific family should also be considered in some cases.

At the Seventh International Workshop on MEN at the National Institutes of Health (NIH) (5), a classification of the risk of MTC was established based on the different degrees of MTC aggressiveness, which in turn depend directly on the codon in which the germline *RET* mutation has occurred. Briefly, this consensus recommended that carriers of mutations in extracellular *RET* codons, such as codons 634, 620, 618, and 609, should be operated on before the age of 5 years. Individuals carrying mutations in intracellular *RET* codons, such as codon 804, should undergo TT before the age of 10 years. Patients carrying some specific *RET* mutations, such as those in codons 790 and 791, may have the surgery postponed, and be observed under a strict follow-up. Carriers with a *RET* 918 mutation, which leads to MEN2B, should be operated on by 6 months of age. The purpose of this classification system was to offer a guideline to clinical endocrinologists and neck surgeons.

Recently, the American Thyroid Association (ATA) consensus on MTC added new recommendations (15). Thus, individuals carrying the highly aggressive germline *RET* mutations in codon 634 should undergo preventive thyroid surgery before 5 years of age, possibly around 3 years of age, as MTC has been reported at ages as low as 3 years in *RET* 634 codon mutation carriers (10).

Several guidelines for the diagnosis and management of S-MTC and MTC/MEN2 have been published by different medical authorities such as the International MEN2 Consortium (1), the NIH Workshop on MEN (5), the American Society of Clinical Oncology (ASCO) (22), the ATA (MTC Clinical Guidelines) (15), and the Brazilian Guidelines-MTC (23), among others. The recommendations are broadly similar, although small variations may be present.

General comments. Ideally, all surgical thyroid intervention in MTC/MEN2 cases should be preventive. However, in clinical practice, surgical interventions in MTC may vary from prophylactic to palliative approaches depending on the age at the MTC diagnosis and treatment, the disease stage and the *RET* codon mutation.

Also, as it is mandatory in all surgical thyroid intervention, a careful neck dissection is needed to avoid parathyroid function damage, which may ultimately lead to permanent hypoparathyroidism. Accordingly, special attention is necessary to protect the vascular supply of the parathyroid glands. Also, this would decrease the chance of cervical nerve lesion, which may lead to transient or permanent nerve palsy. It is worth noting that possible thyroid remnants left behind with thyroid C-cells during a TT procedure, such as remnants in the posterior thyroid capsule, may lead to persistent MTC, and may increase the chance for recurrent disease (Tavares et al., unpublished observations).

TT associated with removal of cervical and mediastinal lymph node metastases should be performed by skilled surgeons in tertiary centers with expertise in the management of MTC cases.

Previous investigation for pheochromocytoma is mandatory to avoid the potential risk of adrenal crisis during surgery of MTC, since pheochromocytoma usually occurs in 50% of MEN2A cases (5). Also, hyperparathyroidism needs to be investigated, since it affects 20–30% of MEN2A patients.

Prophylactic treatment. Familial genetic screening of the *RET* proto-oncogene frequently allows planned prophylactic surgery in MEN2 (15).

Total thyroidectomy only. TT has a minimal morbidity. It is recommended for most children aged 3–5 years with *RET*-positive mutated MEN2A, and even beyond this age in those presenting with normal basal serum Ct (<10 pg/ml), no thyroid nodule (or nodules <5 mm), or lymph node metastasis in either side of the neck detected by ultrasound. TT involves the excision of all thyroid tissue, including the superior pole, isthmus, pyramidal remnants, posterior capsule, tubercle of Zuckerkandl, and thyrothymic thyroid rests (15).

In MEN2B, TT is recommended for children younger than 6 months of age with no evidence of disease or thyroid nodule >5 mm and no lymph node metastasis. However, MEN2B cases may present lymph node metastasis at a very young age. Thus, when TT is performed after the first year of life, it is usually associated with cervical lymph node dissection.

In patients with hereditary MTC, disease-free survival is best predicted by tumor, node, metastases (TNM) staging and a preoperative basal Ct level below 30 pg/ml. Basal Ct, class D genotype, and age constitute the key determinants in deciding the timing of preoperative surgery (24).

TT and dissection of the central compartment of the neck (levels VI and VII). The central neck compartment lies in and near the median sagittal plane of the neck and comprises lymph nodes in the pre- and paratracheal area, and precricoid (Delphian) and perithyroidal areas. The central neck is divided into sublevels (25,26) that comprise the following: the prelaryngeal lymph nodes, between the hyoid bone and the superior margin of isthmus of the thyroid gland; the region lateral to the right and left recurrent laryngeal nerve; the pretracheal sublevel, anterior to the trachea from the inferior pole of the thyroid gland, and above the brachiocephalic vein and aortic arch, which includes level VII of the neck. There are few anatomical landmarks and limited appropriate functional studies to individualize the group of lymph nodes located between the recurrent laryngeal nerves below the inferior

pole of the thyroid gland and above the brachiocephalic vein and aortic arch (Figure 1). Surgical access to level VII without splitting the manubrium sternum is laborious, as it is a narrow cavity containing important vessels and other anatomical structures and also some parathyroid glands (26).

We start the central neck dissection by identifying the left common carotid artery at the level of the hyoid bone. It proceeds caudally on the anteromedial rim of the carotid artery until it reaches the superior border of the left innominate vein. From this point on, dissection goes horizontally toward the right side following the superior border of the vein, until it comes to the innominate artery. Dissection follows cranially in the anterior wall of the brachiocephalic and right carotid arteries and finishes at the level of the hyoid bone at the right side of the neck. Lymph nodes are removed *en bloc* in the level of the prevertebral fascia, with partial resection of the upper part of the thymus. Recurrent laryngeal nerves and parathyroid glands have been identified previously during TT, and these should be preserved.

TT associated with elective level VI central neck compartment dissection is recommended in MEN2B cases harboring the *RET* 918 mutation presenting with Ct >40 pg/ml, or evidence of lymph node metastasis by ultrasound, even when TT is to be performed during the first year of life. TT associated with level VI central neck compartment dissection is also recommended in MEN2A/FMTC cases before the age of 5 years with Ct >40 pg/ml or there is evidence of lymph node metastasis.

TT complemented by prophylactic dissection of the central neck may potentially avoid the risk of reoperation of this neck compartment (5,15). This procedure is recommended for most *RET*-positive carriers older than 5 years who have a thyroid nodule <5 mm observed by ultrasound, but with Ct levels >40 pg/ml. The selection of patients to avoid dissection of the central neck is based on the increased risk for postsurgical hypoparathyroidism, a complication with harmful long-term consequences in children. Thus, the surgeon must pay special attention to parathyroid glands and parathyroid vasculature during central neck intervention.

Lateral neck dissection. Complimentary dissection of the lateral neck is performed when jugulo-carotid lymph node metastases are identified by neck ultrasound. Lymph nodes with a diameter >1.0 cm and round in shape are suspicious and must be investigated for MTC metastasis by

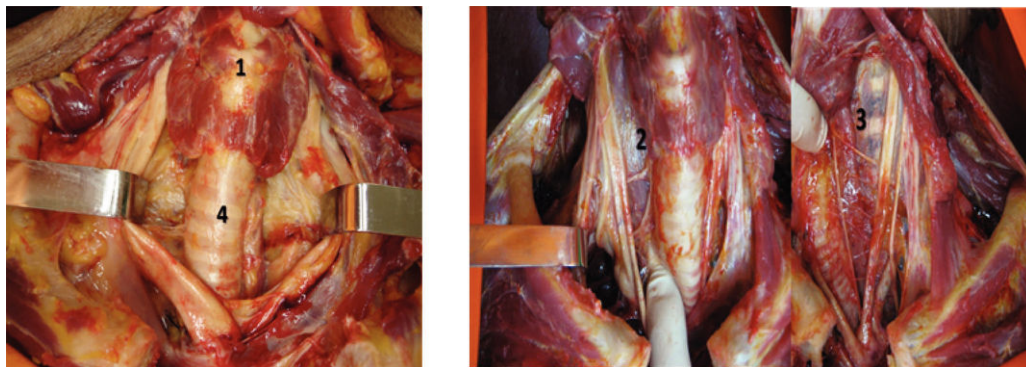


Figure 1 - Sublevels of the central compartment of the neck. Spaces of the central compartment of the neck: prelaryngeal (1); lateral to the recurrent laryngeal nerves on the right (2) and left (3) sides; pretracheal, between the recurrent laryngeal nerves (4).

a performing cytology. It is important to emphasize that lymph nodes with diameters <1.0 cm may already have minimal MTC metastases and cytological accuracy may be not sufficiently high to detect these (8). Thus, a negative cytology result should be followed by immunocytochemistry for Ct and measurement of Ct levels in the washout obtained using a fine needle aspiration biopsy.

Standard modified neck dissection preserving the sternocleidomastoid muscle, jugular vein, and accessory nerve is the best approach if there has been no previous neck dissection. Elective dissection of the lateral compartment of the neck is not indicated for MTC, unless follow-up is not affordable. The low cure rate obtained with the extended neck procedure is attributed to distant metastases. Moreover, dissection of the lateral neck can be safely performed a second time, if necessary.

Surgery for advanced disease. In MTC with a palpable thyroid nodule >1.0 cm, central compartment, bilateral and/or contralateral lymph node metastases are present in up to 50–70% of cases (5). In most cases, TT followed by dissection of central and both lateral neck compartments are indicated. This procedure frequently takes a long time and should be carried out carefully.

Thus, the decision to perform routine, extensive neck lymph node dissection should be taken ideally after confirmation of lymph node disease.

It is worthwhile mentioning that thyroid surgery is the only current potentially curative therapeutic method for MTC, although new drugs acting upon the RET protein kinase receptor have been actively investigated (18).

Persistent and recurrent disease. Persistent or recurrent MTC disease has been reported in up to 2–10% of young patients after prophylactic TT, mostly in cases that had operations after the ages of 8–13 years (12,27,28). In agreement with this, there was no persistent or recurrent MTC in a series of 50 children who underwent prophylactic TT and central neck dissection before the age 8 years (27).

In an MTC series, tumors up to 5 mm were found in seven of eight children, aged from 3 to 13 years, with a RET 634 codon mutation. After TT, a 3-year-old boy developed hypoparathyroidism, a condition that requires ongoing calcium intake and also treatment with calcitriol; this condition has also occurred in 30% of our adult MTC/MEN2 patients after TT (Tavares et al., unpublished data).

Documented loco-regional recurrences can be treated by reoperation of the central neck compartment and/or selective neck dissection of the compromised lateral neck lymph node echelons. Selective dissection is preferred to extensive neck lymph node dissection, based on the high probability that there are distant metastases in these cases, and these render elective lymph node resection ineffective.

Isolated distant metastasis can be treated by surgery, and radiation therapy and chemotherapy are used as palliative measures. New drugs targeting the RET tyrosine kinase receptor are in phase III clinical trials, and they have shown good initial results (18).

Remission. There was no persistent or recurrent MTC in a series of 50 children when they underwent prophylactic thyroidectomy and central neck dissection before age 8 years (27). In a large series, Pelizzo et al. reported that all patients undergoing TT at stages I and II were totally cured (13). Also, in a family with FMTC resulting from the Cys620Arg mutation, all patients undergoing TT below or at 12 years of age were cured biochemically (28). In family

members, it was shown that the chance of achieving a biochemical cure in MTC is clearly dependent on the size of the primary tumor.

Conversely, in one series of children with MEN2A and FMTC who underwent prophylactic TT at age 4 years or over, 11% experienced biochemical persistence or recurrence, and all of them were operated on at age 13 years or above (12).

MTC diagnosed during thyroid surgery. TT is adequate when MTC with a diameter <5 mm is identified by frozen section during surgery for a thyroid nodule. Central neck dissection and examination of both lateral compartments of the neck are necessary only if a positive lymph node is detected. Lymph nodes >1 cm diameter, round in shape and/or with a hard consistency are considered suspicious, and must be excised and subjected to frozen section. Neck dissection of levels II–V is mandatory in the side of the neck with the positive lymph node. Lateral neck dissection is indicated only for disease that has been detected. Although comprehensive modified neck dissection of levels II–V is the best treatment, selective dissection of the compromised level may be considered for these patients. Elective dissection is performed for MTC with a diameter >5 mm. In an attempt to detect S-MTC or the index cases of MTC/MEN2 families before surgery, the European Thyroid Association (ETA) recommends that serum Ct should be routinely measured in patients with thyroid nodules and clinical risk factors for MTC (20). This procedure can benefit some people, as they are able to better plan their surgery.

MTC diagnosed after thyroid surgery. In approximately 10–15% of cases of MTC, diagnosis is obtained by pathological analysis after thyroidectomy for a thyroid nodule (29). Since neck dissection is performed for positive or suspicious lymph nodes, and also in well-differentiated thyroid carcinomas, reoperation should not be the first step considered in this difficult situation. Investigation should begin with serum basal Ct level, neck ultrasound, and analysis of RET proto-oncogene mutation. A normal Ct level indicates that there is a very low chance of residual MTC, and no other treatment is necessary. Standard follow-up is sufficient in these cases.

Elevated postsurgical basal Ct levels indicate persistent disease (15), and there is a trend for Ct levels to correlate with disease stages (17). Tiny thyroid tissue amounts left behind, most frequently undetectable, can result in Ct levels <40 pg/ml. Ct levels >400 pg/ml probably indicate distant metastases (15).

A diligent search for metastases in the neck, mediastinum, bones, lung, and liver is accomplished by ultrasound and computed tomography (CT) of these segments. Suspicious nodules should be further examined by ultrasound or CT-guided fine needle aspiration biopsy with cytological study. Immunocytochemistry analysis for Ct, and Ct measurements in the washout, are the next steps to be considered in cases with a negative cytology sample. Patients whose examinations are normal are carefully followed up with basal Ct and neck ultrasound. If a rise in Ct is noticed, a further CT is helpful to establish the disease staging (15).

Parathyroid glands. High priority must be given to preserving parathyroid function (15). Normal parathyroid glands should be left *in situ* with an adequate vascular pedicle whenever possible. Accidentally resected or devascularized normal parathyroid glands must be immediately autografted in the neck of MTC patients who

are *RET* negative, and in MEN2B and FMTC patients. In contrast, in patients with MEN2A, the parathyroid glands should be routinely autografted to a heterotopic site in the neck or forearm. Furthermore, the location for implantation of the excised parathyroid tissue is determined by the type of *RET* mutation present. Patients with a strong family history of HPT or those harboring a *RET* mutation associated with an increased risk of HPT (i.e., at codon 634) should have the parathyroid implant placed in the forearm. If the MTC patient has MEN2B, FMTC, or a mutation with a low risk of HPT, the graft can be placed in the sternocleidomastoid muscle (23).

Surgical neck exploration to remove a parathyroid adenoma is indicated only after secure localization of the enlarged gland. Normal glands are left *in situ*. Excision of the four glands is indicated only if all glands are clearly abnormal.

Prophylactic treatment of HPT is not usually performed in all academic centers, as HPT is absent in cases of FMTC and MEN2B, although it occurs in 20–30% of MEN2A patients. Moreover, HPT associated with MEN2A frequently presents as a single parathyroid adenoma that, in many instances, can be localized by image studies such as ultrasound and/or sestamibi scintigraphy (5).

Follow-up. Long-term postoperative follow-up is recommended in MTC, either to confirm biochemical cure or monitor the patient for persistent or recurrent MTC disease.

Due to the high sensitivity and specificity of the methods for Ct measurements, persistently undetectable basal levels of Ct (<2 pg/ml) indicate absence or remission of MTC, whereas detectable Ct levels usually indicate the presence of MTC disease.

However, up to 5% of MTC cases with undetectable basal Ct levels who undergo TT may show abnormally high calcium-stimulated Ct values (>80 pg/ml). These latter cases cannot be considered to be cured, and they should be followed up carefully. Accordingly, recurrence may occasionally occur 5–7 years after the initial surgical treatment, even though there was a prolonged period in which Ct remained undetectable (<2 pg/ml) (5).

During follow-up, a neck ultrasound can identify suspicious lymph node metastases. A negative ultrasound eliminates the risk of neck metastasis, and indicates that a search for distant metastases may be needed. It is worthwhile pointing out that several conditions other than MTC may be associated with increased Ct levels, and these conditions should be ruled out (19).

As there is a correlation between basal Ct levels and MTC disease staging, chest and abdominal CT are indicated to search for distant metastases in cases with basal Ct levels >400 pg/ml. MTC disease may be frequently difficult to locate, and all suspicious lymph nodes should be routinely sampled by fine-needle aspiration biopsy followed by immunocytochemistry analysis for Ct. The complete set of recommended investigations is given in the ATA guidelines (15).

Experience from an academic center

Briefly, our long-term accumulated experience with MTC/MEN2 patients comes from a single academic center: the Hospital das Clínicas, University of São Paulo (7,8,16,19,23,28,30–36). The medical and scientific collaboration of the head and neck team together with the Endocrine

Genetics Unit in the Department of Endocrinology began in the early 1990s (30,31) and has continued up to the present day (28,36). Here, we would like to briefly mention our observation in a large family with FMTC from the north-east area Brazil, with more than 35 affected individuals harboring the germline heterozygous *RET* Cys620Arg mutation. So far, in this family, we have obtained persistent biochemical remission (Ct <2 pg/ml) in 14 *RET*-positive carriers who underwent TT before or at 12 years of age, although *RET* 620 codon mutation carriers should be ideally undergo TT by the age of 5 years (5,15). Partial data obtained from this family have been published previously, as part of an international consortium on *RET* exon 10 mutation (28).

In conclusion, we have briefly reviewed some specific aspects of the surgical approaches to MTC, mostly those recommended for young asymptomatic children carrying a germline *RET* mutation.

ACKNOWLEDGMENTS

FUNDING: SPAT is a recipient of a CNPq fellowship (401990/2010-9), TS is a recipient of a FAPESP doctoral fellowship (11942/2009), and RAT is a recipient of FAPESP post-doctoral fellowship (2009/15386-6).

AUTHOR CONTRIBUTIONS

Tavares MR is the main author and was responsible for the treatment of patients, manuscript revision and manuscript writing. Toledo SPA was responsible for the diagnoses of patients, manuscript writing and revision, bibliography and translation. Montenegro FLM, Moyses RA, Toledo RA were responsible for the manuscript revision and bibliography. Cernea CR was responsible for manuscript revision, bibliography and translation revision. Brandão LG and Sekyia T were responsible for the manuscript revision.

REFERENCES

- Eng C, Clayton D, Schuffenecker I, Lenoir G, Cote G, Gagel RF, et al. The relationship between specific *RET* proto-oncogene mutations and disease phenotype in multiple endocrine neoplasia type 2. International *RET* mutation consortium analysis. *JAMA*. 1996;276(19):1575–9.
- Thakker RV. Multiple endocrine neoplasia – syndromes of the twentieth century. *J Clin Endocrinol Metab*. 1998;83(8):2617–20, <http://dx.doi.org/10.1210/jc.83.8.2617>.
- Lourenço DM Jr, Toledo RA, Coutinho FL, Margarido LC, Siqueira SA, dos Santos MA, et al. The impact of clinical and genetic screenings on the management of the multiple endocrine neoplasia type 1. *Clinics*. 2007;62(4):465–76, <http://dx.doi.org/10.1590/S1807-59322007000400014>.
- Toledo RA, Lourenço DM, Coutinho FL, Quedas E, Mackowiack I, Machado MC, et al. Novel MEN1 germline mutations in Brazilian families with multiple endocrine neoplasia type 1. *Clin Endocrinol (Oxf)*. 2007;67(3):377–84, <http://dx.doi.org/10.1111/j.1365-2265.2007.02895.x>.
- Brandi ML, Gagel RF, Angeli A, Bilezikian JP, Beck-Peccoz P, Bordi C, et al. Guidelines for diagnosis and therapy of MEN type 1 and type 2. *J Clin Endocrinol Metab*. 2001;86(12):5658–71, <http://dx.doi.org/10.1210/jc.86.12.5658>.
- Eng C. Mendelian genetics of rare – and not so rare – cancers. *Ann N Y Acad Sci*. 2010;1214:70–82, <http://dx.doi.org/10.1111/j.1749-6632.2010.05789.x>.
- Toledo SP, dos Santos MA, Toledo RA, Lourenço DM Jr. Impact of *RET* proto-oncogene analysis on the clinical management of multiple endocrine neoplasia type 2. *Clinics*. 2006;61(1):59–70, <http://dx.doi.org/10.1590/S1807-59322006000100011>.
- Correia-Deur JE, Toledo RA, Imazawa AT, Lourenço DM Jr, Ezabella MC, Tavares MR, et al. Sporadic medullary thyroid carcinoma: clinical data from a university hospital. *Clinics*. 2009;64(5):379–86, <http://dx.doi.org/10.1590/S1807-59322009000500002>.
- Lips CJ, Höppener JW, Van Nesselrooij BP, Van der Luijt RB. Counselling in multiple endocrine neoplasia syndromes: from individual experience to general guidelines. *J Intern Med*. 2005;257(1):69–77, <http://dx.doi.org/10.1111/j.1365-2796.2004.01429.x>.
- Machens A, Dralle H. Multiple endocrine neoplasia type 2: achievements and current challenges. *Clinics*. 2012;67(S1):113–8, [http://dx.doi.org/10.6061/clinics/2012\(Sup01\)19](http://dx.doi.org/10.6061/clinics/2012(Sup01)19).

11. Hundahl SA, Fleming ID, Fremgen AM, Menck HR. A National Cancer Data Base report on 53,856 cases of thyroid carcinoma treated in the US, 1985-1995. *Cancer*. 1998;83(12):2638-48, [http://dx.doi.org/10.1002/\(SICI\)1097-0142\(19981215\)83:12<2638::AID-CNCR31>3.0.CO;2-1](http://dx.doi.org/10.1002/(SICI)1097-0142(19981215)83:12<2638::AID-CNCR31>3.0.CO;2-1).
12. Frank-Raue K, Buhr H, Dralle H, Klar E, Senninger N, Weber T. Long-term outcome in 46 gene carriers of hereditary medullary thyroid carcinoma after prophylactic thyroidectomy: impact of individual RET genotype. *Eur J Endocrinol*. 2006;155(2):229-36, <http://dx.doi.org/10.1530/eje.1.02216>.
13. Pelizzo MR, Boschin IM, Bernante P, Toniato A, Piotto A, Pagetta C, et al. Natural history, diagnosis, treatment and outcome of medullary thyroid cancer: 37 years experience on 157 patients. *Eur J Surg Oncol*. 2007;33(4):493-7, <http://dx.doi.org/10.1016/j.ejso.2006.10.021>.
14. de Groot JW, Links TP, Plukker JT, Lips CJ, Hofstra RM. RET as a diagnostic and therapeutic target in sporadic and hereditary endocrine tumors. *Endocr Rev*. 2006;27(5):535-60, <http://dx.doi.org/10.1210/er.2006-0017>.
15. American Thyroid Association Guidelines Task Force, Kloos RT, Eng C, Evans DB, Francis GL, Gagel RF, Gharib H, et al. Medullary thyroid cancer: management guidelines of the American Thyroid Association. *Thyroid*. 2009;19(6):565-612, <http://dx.doi.org/10.1089/thy.2008.0403>.
16. Tavares MR, Michaluart P Jr, Montenegro F, Arap S, Sodre M, Takeda F, et al. Skip metastases in medullary thyroid carcinoma: a single-center experience. *Surg Today*. 2008;38(6):499-504, <http://dx.doi.org/10.1007/s00595-007-3664-8>.
17. Machens A, Lorenz K, Dralle H. Individualization of lymph node dissection in RET (Rearranged During Transfection) carriers at risk for medullary thyroid cancer: value of pre-therapeutic calcitonin levels. *Ann Surg*. 2009;250(2):305-10, <http://dx.doi.org/10.1097/SLA.0b013e3181ae333f>.
18. Schlumberger M, Massicotte MH, Nascimento CL, Chougnet C, Baudin E, Leboulleux S. Kinase inhibitors for advanced medullary thyroid carcinoma. *Clinics*. 2012;67(S1):125-9, [http://dx.doi.org/10.6061/clinics/2012\(Sup01\)21](http://dx.doi.org/10.6061/clinics/2012(Sup01)21).
19. Toledo SP, Lourenço DM Jr, Santos MA, Tavares MR, Toledo RA, Correia-Deur JE. Hypercalcitoninemia is not pathognomonic of medullary thyroid carcinoma. *Clinics*. 2009;64(7):699-706, <http://dx.doi.org/10.1590/S1807-59322009000700015>.
20. Costante G, Filetti S. Early diagnosis of medullary thyroid carcinoma: is systematic calcitonin screening appropriate in patients with nodular thyroid disease? *Oncologist*. 2011;16(1):49-52, <http://dx.doi.org/10.1634/theoncologist.2010-0344>.
21. Erlic Z, Rybicki L, Peczkowska M, Golcher H, Kann PH, Brauckhoff M, et al. Clinical predictors and algorithm for the genetic diagnosis of pheochromocytoma patients. *Clin Cancer Res*. 2009;15(20):6378-85, <http://dx.doi.org/10.1158/1078-0432.CCR-09-1237>.
22. Sherman SI, Angelos P, Ball DW, Byrd D, Clark OH, Daniels GH, et al. Thyroid carcinoma. *J Natl Compr Canc Netw*. 2007;5(6):568-621.
23. Tincani AJ, Teixeira GV, Tavares MR, Hojaij FC, Araújo PPC, Maia AL, et al. Diretrizes Clínicas na Saúde Suplementar. Assoc. Med. Brasileira Agência Nacional de Saúde Suplementar. Câncer Medular de Tireoide: Tratamento. http://www.projetodiretrizes.org.br/ans/diretrizes/cancer_medular_de_tireoide-tratamento.pdf.
24. Rohmer V, Vidal-Trecan G, Bourdelot A, Niccoli P, Murat A, Wemmeau JL, et al. Prognostic factors of disease-free survival after thyroidectomy in 170 young patients with a RET germline mutation: a multicenter study of the Groupe Français d'Etude des Tumeurs Endocrines. *J. Clin Endocrinol Metab*. 2011;96(3):E509-18, <http://dx.doi.org/10.1210/jc.2010-1234>.
25. Wada N, Duh QY, Sugino K, Iwasaki H, Kameyama K, Mimura T, et al. Lymph node metastasis from 259 papillary thyroid microcarcinomas: frequency, pattern of occurrence and recurrence, and optimal strategy for neck dissection. *Ann Surg*. 2003;237(3):399-407, <http://dx.doi.org/10.1097/01.SLA.0000055273.58908.19>.
26. Carty SE, Cooper DS, Doherty GM, Duh QY, Kloos RT, Mandel SJ, et al. Consensus statement on the terminology and classification of central neck dissection for thyroid cancer. *Thyroid*. 2009;19(11):1153-8, <http://dx.doi.org/10.1089/thy.2009.0159>.
27. Skinner MA, Moley JA, Dilley WG, Owzar K, Debenedetti MK, Wells SA Jr. Prophylactic thyroidectomy in multiple endocrine neoplasia type 2A. *New Engl J Med*. 2005;353(11):1105-13, <http://dx.doi.org/10.1056/NEJMoa043999>.
28. Frank-Raue K, Rybicki LA, Erlic Z, Schweizer H, Winter A, Milos I, et al. Risk profiles and penetrance estimations in multiple endocrine neoplasia type 2A caused by germline RET mutations located in exon 10. *Hum Mutat*. 2011;32(1):51-8, <http://dx.doi.org/10.1002/humu.21385>.
29. Ahmed SR, Ball DW. Clinical review: Incidentally discovered medullary thyroid cancer: diagnostic strategies and treatment. *J Clin Endocrinol Metab*. 2011;96(5):1237-45, <http://dx.doi.org/10.1210/jc.2010-2359>.
30. Toledo SP, Ferraz AR. Multiple endocrine type II neoplasm. *Rev Hosp Clin Fac Med Sao Paulo*. 1990;45(1):1-2.
31. Ezabella MC, Hayashida CY, Bisi H, Leite MO, Borelli A, Abelin NM, et al. Early detection of medullary thyroid carcinoma in multiple endocrine neoplasia type II. *Rev Hosp Clin Fac Med Sao Paulo*. 1990;45(3):105-9.
32. Hayashida CY, Alves VA, Kanamura CT, Ezabella MC, Abelin NM, Nicolau W, et al. Immunohistochemistry of medullary thyroid carcinoma and C-cell hyperplasia by an affinity-purified anti-human calcitonin antiserum. *Cancer*. 1993;72(4):1356-63, [http://dx.doi.org/10.1002/1097-0142\(19930815\)72:4<1356::AID-CNCR2820720434>3.0.CO;2-0](http://dx.doi.org/10.1002/1097-0142(19930815)72:4<1356::AID-CNCR2820720434>3.0.CO;2-0).
33. Nunes AB, Ezabella MC, Pereira AC, Krieger JE, Toledo SP. A novel Val648Ile substitution in RET protooncogene observed in a Cys634Arg multiple endocrine neoplasia type 2A kindred presenting with an adrenocorticotropin-producing pheochromocytoma. *J Clin Endocrinol Metab*. 2002;87(2):5658-61, <http://dx.doi.org/10.1210/jc.2002-020345>.
34. Santos MA, Nunes AB, Abelin N, Ezabella MC, Toledo RA, Lourenço DM Jr, et al. Genetic screening of multiple endocrine neoplasia type 2: experience of the USP Endocrine Genetics Unit. *Arq Bras Endocrinol Metabol*. 2006;50(1):7-16, <http://dx.doi.org/10.1590/S0004-27302006000100003>.
35. Santos MA, Quedas EP, Toledo Rde A, Lourenço DM Jr, Toledo SP. Screening of RET gene mutations in multiple endocrine neoplasia type-2 using conformation sensitive gel electrophoresis (CSGE). *Arq Bras Endocrinol Metabol*. 2007;51(9):1468-76, <http://dx.doi.org/10.1590/S0004-27302007000900009>.
36. Toledo RA, Wagner SM, Coutinho FL, Lourenço DM Jr, Azevedo JA, Longuini VC, et al. High penetrance of pheochromocytoma associated with the novel C634Y/Y791F double germline mutation in the RET protooncogene. *J Clin Endocrinol Metab*. 2010;95(3):1318-27, <http://dx.doi.org/10.1210/jc.2009-1355>.