

REVIEW

Head and neck paragangliomas: clinical and molecular genetic classification

Christian Offergeld,^I Christoph Brase,^{II} Svetlana Yaremchuk,^{III} Irina Mader,^{IV} Hans Christian Rischke,^V Sven Gläsker,^{VI} Kurt W Schmid,^{VII} Thorsten Wiech,^{VIII} Simon F Preuss,^{IX} Carlos Suárez,^X Tomasz Kopeć,^{XI} Attila Patocs,^{XII,XIII} Nelson Wohllk,^{XIV} Mahdi Malekpour,^{XV,XVI} Carsten C Boedeker,^I Hartmut PH Neumann^{XVII}

^IDepartment of Otorhinolaryngology, University Medical Center, Albert-Ludwigs-University, Freiburg, Germany. ^{II}Department of Otorhinolaryngology, Friedrich-Alexander-University of Erlangen-Nürnberg, Erlangen, Germany. ^{III}Institute of Otolaryngology of the Academy of Medical Science of Ukraine, Kiev, Ukraine. ^{IV}Department of Neuroradiology, University Medical Center, Albert-Ludwigs-University, Freiburg, Germany. ^VDepartment of Nuclear Medicine, University Medical Center, Albert-Ludwigs-University, Freiburg, Germany. ^{VI}Department of Neurosurgery, University Medical Center, Albert-Ludwigs-University, Freiburg, Germany. ^{VII}Institute of Pathology and Neuropathology, University Hospital of Essen, University of Duisburg-Essen, Essen, Germany. ^{VIII}Institute of Pathology, University Hospital Freiburg, Albert-Ludwigs-University, Freiburg, Germany. ^{IX}Department of Otorhinolaryngology, University of Cologne, Cologne, Germany. ^XDepartment of Otolaryngology, Hospital Universitario Central de Asturias, Oviedo, Spain. ^{XI}Poznan University of Medical Sciences, Department of Otolaryngology, Poznan, Poland. ^{XII}2nd Department of Medicine, Semmelweis-University, Budapest, Hungary. ^{XIII}Molecular Medicine Research Group, Hungarian Academy of Sciences, Semmelweis-University, Budapest, Hungary. ^{XIV}Department of Endocrinology, Hospital del Salvador, University of Chile, Santiago de Chile, Chile. ^{XV}Department of Otorhinolaryngology, Tehran University of Medical Sciences, Tehran, Iran. ^{XVI}Department of Medicine, Vanderbilt University Medical Center, Nashville, TN, USA. ^{XVII}Department of Nephrology and General Medicine, University Medical Center, Albert-Ludwigs-University, Freiburg, Germany.

Head and neck paragangliomas are tumors arising from specialized neural crest cells. Prominent locations are the carotid body along with the vagal, jugular, and tympanic glomus. Head and neck paragangliomas are slowly growing tumors, with some carotid body tumors being reported to exist for many years as a painless lateral mass on the neck. Symptoms depend on the specific locations. In contrast to paraganglial tumors of the adrenals, abdomen and thorax, head and neck paragangliomas seldom release catecholamines and are hence rarely vasoactive. Petrous bone, jugular, and tympanic head and neck paragangliomas may cause hearing loss. The internationally accepted clinical classifications for carotid body tumors are based on the Shamblin Class I–III stages, which correspond to postoperative permanent side effects. For petrous-bone paragangliomas in the head and neck, the Fisch classification is used. Regarding the molecular genetics, head and neck paragangliomas have been associated with nine susceptibility genes: *NF1*, *RET*, *VHL*, *SDHA*, *SDHB*, *SDHC*, *SDHD*, *SDHAF2* (*SDH5*), and *TMEM127*. Hereditary HNPs are mostly caused by mutations of the *SDHD* gene, but *SDHB* and *SDHC* mutations are not uncommon in such patients. Head and neck paragangliomas are rarely associated with mutations of *VHL*, *RET*, or *NF1*. The research on *SDHA*, *SDHAF2* and *TMEM127* is ongoing. Multiple head and neck paragangliomas are common in patients with *SDHD* mutations, while malignant head and neck paraganglioma is mostly seen in patients with *SDHB* mutations. The treatment of choice is surgical resection. Good postoperative results can be expected in carotid body tumors of Shamblin Class I and II, whereas operations on other carotid body tumors and other head and neck paragangliomas frequently result in deficits of the cranial nerves adjacent to the tumors. Slow growth and the tendency of hereditary head and neck paragangliomas to be multifocal may justify less aggressive treatment strategies.

KEYWORDS: Paraganglioma; Susceptibility Genes; Shamblin Classification; Fisch Classification.

Offergeld C, Brase C, Yaremchuk S, Mader I, Rischke HC, Gläsker S, et al. Head and neck paragangliomas: clinical and molecular genetic classification. Clinics. 2012;67(S1):19-28.

E-mail: hartmut.neumann@uniklinik-freiburg.de

Tel.: +49 761 270 35780

INTRODUCTION

Head and neck paragangliomas (HNPs) are tumors of the autonomic system. They arise from chromaffin cells of the

parasympathetic paraganglia of the skull base and neck, and are also called glomus tumors (1–5). Most well known is the tumor of the glomus caroticum, the carotid body tumor (CBT). HNP surgery is a challenge to the surgeon because of the tumor's location in the vicinity of important blood vessels and cranial nerves. As well as pre-operative impairment of nerve function, surgery may result in deficits of cranial nerves VII, VIII, IX, X, XI, and XII.

In this review, we present an overview of the clinical presentation and radiologic imaging of HNPs, topographical classification of HNPs, and recent advances in the

This is an Open Access article distributed under the terms of the Creative Commons Attribution Non-Commercial License (<http://creativecommons.org/licenses/by-nc/3.0/>) which permits unrestricted noncommercial use, distribution, and reproduction in any medium, provided the original work is properly cited.

No potential conflict of interest was reported.

genetics of HNPs in the context of nine susceptibility genes predisposing to tumors of the paraganglial system. These genetic data not only enrich our understanding of HNPs, but also provide us with a tool for risk assessment of tumors outside the head and neck region.

PREVALENCE

HNPs are rare tumors, representing less than 0.5% of all head and neck tumors. Approximately 3% of paragangliomas occur in the head and neck area (4); other estimates suggest that 1 in 30,000 head and neck tumors are HNPs (5).

TOPOGRAPHY

Most HNPs arise in the bifurcation of the carotid artery (i.e. CBTs). Vagal paragangliomas arise from the autonomic nervous part of the vagal nerve (cranial nerve X). HNPs arising in the petrous bone originate from the tympanic glomus or the jugular glomus. When these tumors cannot be differentiated, they are referred to as jugulotympanic paragangliomas. Given the extensive spreading of the autonomic nervous structure, HNPs can arise at other locations, such as the ciliary glomus or laryngeal glomus.

SIGNS AND SYMPTOMS

HNPs are space-occupying tumors. Signs and symptoms are induced by the topography of the anatomical structures from which the tumors originate. In contrast to extra-adrenal, abdominal, and thoracic pheochromocytomas, HNPs rarely secrete active substances. Only 1–3% of HNPs are vasoactive and associated with elevated catecholamines. Such tumors can induce tachycardia, hypertension and sweating attacks.

Carotid body tumors (CBTs)

CBTs arise from paraganglia located within the covering of the carotid artery in the neck. CBTs often remain clinically silent before presenting as a painless, slowly enlarging mass in the lateral neck (1,6,7). Approximately 60–70% of all CBTs take this route of clinical presentation (6,7). The initial symptoms can also be a pulsating mass in the neck. CBTs can be moved horizontally rather than vertically, a finding known as a positive Fontaine's sign (1). Large CBTs may induce dysfunction of the vagal nerve and, less frequently, of cranial nerves IX, XI, and XII. Occasionally, Horner's syndrome or deficits of the facial nerve may result from extremely large tumors (1,6). Sometimes a carotid bruit or a pulsating mass can be detected.

Vagal paragangliomas

Vagal paragangliomas (VPs) are located more cephalad in the neck, between the jugular vein and the internal carotid artery, sometimes extending to the base of the skull through the jugular foramen or posterior to the mastoid tip (8). The symptoms of a VP depend on the location of the tumor along the vagal nerve from the skull base to the lower neck (8). Most VPs arise from the glomus nodosum, that is, the inferior ganglion. Typically, VPs present with an asymptomatic neck mass behind the angle of the mandible. Other symptoms of VPs are pulsatile tinnitus or ringing in the ear heard with each heartbeat (9). At times, this can be heard by placing the stethoscope over the ear. Less than 50% of VPs present with deficits of cranial nerves, which manifest as hoarseness (X), dysphagia (IX), shoulder drop (XI), nasal reflux of fluids, aspiration and hemiatrophy of the tongue

(XII) (10,11). Intracranial extension, which is the main cause of death, occurs in 22% of the cases (4). Oropharyngeal involvement caused by bulging of the pharyngeal wall into the pharyngeal lumen and medial displacement of the tonsil, may occasionally be observed.

Temporal paragangliomas

Temporal paragangliomas entail tympanic and jugular paragangliomas. They arise from structures in close vicinity and are sometimes summarized in one group.

Tympanic paragangliomas

Tympanic paragangliomas (TPs) are mostly small-sized tumors originating in the middle ear. These tumors become symptomatic as pulsatile tinnitus in the vast majority of patients. Hearing loss is initially present in about half of patients (1,3–5,12). Most TPs are visible as a vascular middle ear mass. They are diagnosed by careful examination of the tympanic membrane and identification of the tumor through the translucent eardrum. Introducing positive pressure in the ear canal stops the pulsations of the tumor. Frequently, it is impossible to visualize the entire tumor clinically, thus computed tomography (CT) or magnetic resonance imaging (MRI) scans are diagnostic.

Jugular paragangliomas

Jugular paragangliomas (JPs) arise from paraganglia in or around the jugular bulb (12,13). Occlusion of venous flow happens when these tumors increase in size. Consequently, venous blood from the brain shifts toward the unaffected sigmoid sinus and jugular bulb. Symptoms are similar to those of TP. Pulsatile tinnitus is a frequent symptom. A bruit can be heard by placing a stethoscope over the ear. Conductive hearing loss is seen with progression of the tumor, which either causes impairment of vibration of the ossicles or invades the bones behind the eardrum. Sensorineural hearing loss and/or dizziness is reported by patients when the tumor has invaded the inner ear. Occasionally, JPs can cause deficits of other cranial nerves and create dysfunctional swallowing and huskiness of the voice. However, due to the relatively slow growth, the swallowing mechanism and vocal cord function of the opposite side may initially compensate and mask the disease symptoms. When these tumors grow, they can also invade the facial nerve leading to facial paralysis, or they can encompass the hypoglossal nerve, leading to paralysis of half of the tongue. Further growth can lead to compression of the brain and/or brainstem.

RADIOLOGY

B-mode sonography and color duplex sonography are inexpensive, noninvasive diagnostic tools that are often used as the first imaging step for cervical HNPs (1,14). A CBT is usually sonographically seen as a solid, well-defined, hypoechoic mass with a splaying of the carotid bifurcation (1). The external carotid artery (ECA) is usually displaced anteromedially, and the internal carotid artery (ICA) is typically displaced posterolaterally (15).

VPs tend to displace both the ECA and the ICA anteriorly. The internal jugular vein is typically compressed and displaced posteriorly (15). In large VPs there may also be a splaying of the carotid bifurcation, thereby mimicking a CBT.

In color duplex sonography scans, cervical HNPs present as hypervascular tumors in most cases. It is important to

mention, however, that absence of hypervascularity does not exclude a cervical HNP (16). In a study on 18 CBTs, 15 (83.3%) presented as a hypervascular mass in color duplex sonography scans (16).

Carotid, tympanic, and jugular paragangliomas are easily detected using CT and MR angiography. They contain many arterio-venous shunts and show strong enhancement with CT-angiography. Using time-resolved contrast-enhanced MR-angiography, they are detected in the early arterial phase (Figure 2D). Tympanic paragangliomas are seen on high resolution CT images of the petrous bone as a focal soft-tissue mass in the tympanon (17). CT is superior for the detection of bone destruction in the temporal bone (18). For jugular paragangliomas both MR (17) and CT (19) are recommended. CT-angiography depicts the anatomy more accurately than MR-angiography because of the better spatial resolution (19). However, contrast-enhanced MR-angiography is better suited for screening and detection of multiple lesions. Both cross-sectional methods can be used for operative navigation. Pre-operative embolization of the paragangliomas aims for a reduction of blood loss during operation, but the literature is controversial (7,20).

NUCLEAR MEDICINE IMAGING

HNP typically show avid uptake with different functional imaging techniques, namely 18F-fluorodihydroxyphenylalanine (18F-FDOPA) positron emission tomography/computed tomography (PET/CT); 18F-fluorodopamine (18F-FDA) PET/CT and 123I-metaiodobenzylguanidine (123I-MIBG) scintigraphy; the latter is paraganglioma specific. Furthermore, somatostatin receptor imaging has a sensitivity of greater than 90% for HNP (21) using 111In-octreotide scintigraphy. Positron emitting somatostatin receptor imaging agents, such as 68Ga-DOTA-peptides [e.g. 68Ga-DOTA-TATE (DOTA-Tyr3-Thr8-octreotide)] have shown promising sensitivities in small series (22). It offers an additional

advantage in identifying patients likely to benefit from therapy with 90Y-labelled DOTA-TATE. 18F-FDOPA PET, in particular, has been proved to be highly sensitive in different series and may be considered a good imaging technique for HNPs (23) but may perform poorly in SDHB-associated metastatic disease; under these conditions, 18F-FDG-PET/CT provides higher sensitivities (24).

CLINICAL CLASSIFICATION OF CAROTID BODY TUMORS

CBTs are usually classified using the criteria described by Shamblin and co-workers (25).

Shamblin classification

Shamblin Class I CBTs are localized tumors with splaying of the carotid bifurcation, but little attachment to the carotid vessels. Complete surgical resection is generally possible with only minimal risk of vascular or cranial nerve complications (1).

Shamblin Class II CBTs partially surround the carotid vessels and complete resection is more challenging.

Shamblin class III CBTs intimately surround the carotid. Complete resection is very challenging, and often requires temporary interruption of the cerebral circulation for vascular reconstruction. The risk of permanent vascular and neural defects is significantly higher than for Class I and Class II tumors (26). Figure 1A–C demonstrates three Shamblin classes of CBTs.

CLINICAL CLASSIFICATION OF TEMPORAL PARAGANGLIOMAS

CT is almost crucial to evaluate temporal paragangliomas. The extent of temporal bone destruction is used to classify these tumors according to the Fisch classification (Table 1) (27).

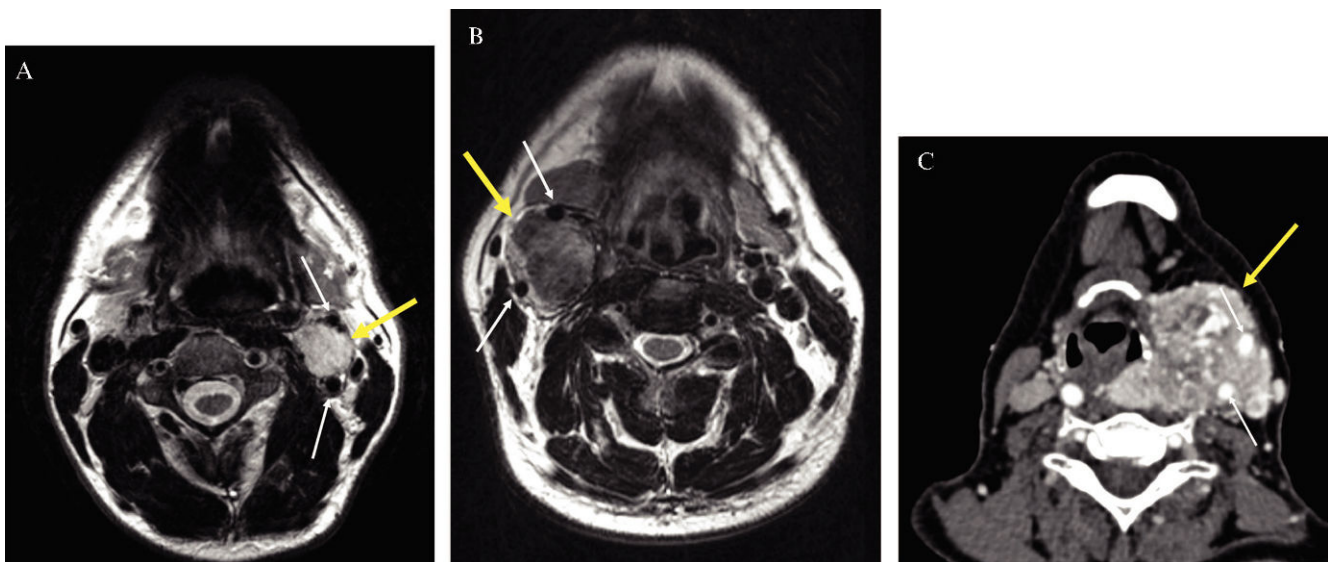


Figure 1 - Shamblin classification. The Shamblin classification is based on involvement of the carotid arteries, which are shown by white arrows in A–C. The tumors are indicated by yellow arrows. (A) CBT (class I): the axial T2-weighted MRI shows a CBT in a typical location. Bulging of the left carotid bifurcation without any encasement of the carotid vessels. (B) CBT (class II): axial T2-weighted MRI showing a right-sided CBT with a partial encasement of the internal and external carotid artery. (C) CBT (class III): an axial slice of CT-angiography reveals a huge left-sided CBT with a complete encasement of the carotid vessels. In this case, bone destruction of the skull base, attributed to the enormous CBT, was also detected by CT (not shown).

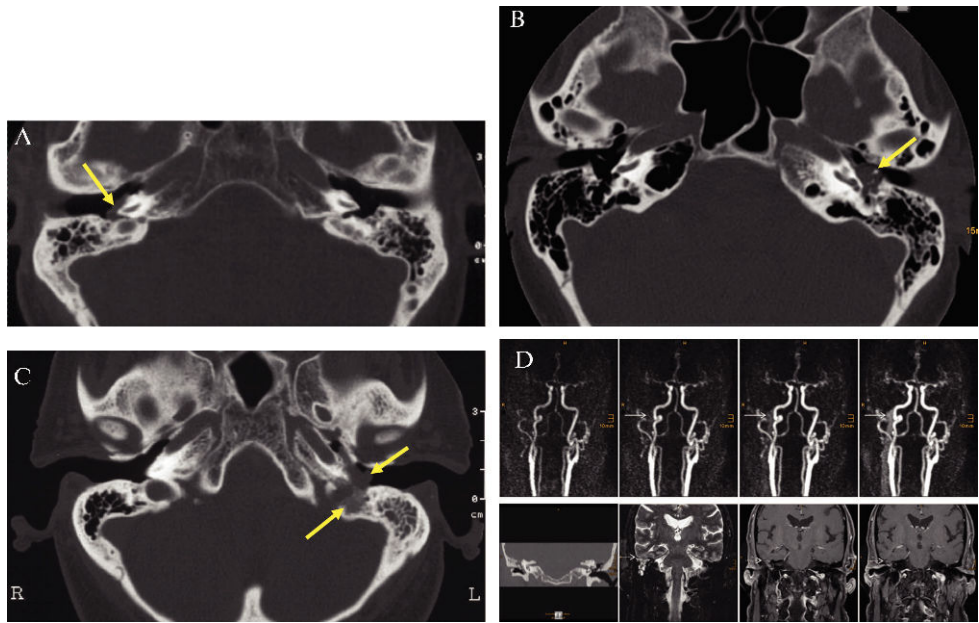


Figure 2 - Fisch classification. The tumors are indicated by yellow arrows. (A) Tympanic paraganglioma (Fisch class A): axial CT scan of a tympanic paraganglioma (bone window) on the right promontory. Note the absence of any bony erosion. (B) Tympanic paraganglioma (Fisch class B): the axial CT scan reveals a left-sided tympanic paraganglioma surrounding and partially destroying the ossicles. The malleus and stapes could not be discriminated. The tumor had also invaded the hypotympanon. There was no destruction of the bone wall to the jugular bulb. (C) Jugular paraganglioma (Fisch class C): axial CT scan showing a left-sided jugular paraganglioma. Note the bone destruction between the jugular bulb and the soft tissue tumor in the hypotympanon. (D) Tympanic paraganglioma (Fisch class D): time-resolved contrast-enhanced MR-angiography (upper row) depicts an early venous drainage attributed to arterio-venous fistulas within this tympanic paraganglioma (solid arrows). Coronal CT (lower row left) of the petrous bone shows a soft tissue tumor with encasement of the ossicles within the whole tympanon, and destruction of the tegmen tympani. Coronal T2-weighted and contrast enhanced T1-weighted images show a small, but distinct, intracranial but extradural tumor growth on the lateral skull base (dotted arrows, lower row).

Fisch classification

TPs arise from paraganglia along the tympanic plexus on the promontory (table 2, figure 2). Fisch class A tumors are limited to the promontory and the mesotympanon. In Fisch class B tumors, there is an invasion of the hypotympanon. Class B paragangliomas often surround, and frequently destroy, the ossicles. In TPs, the bone over the jugular bulb is intact. JPs arise from paraganglia in, or around, the jugular bulb. There is bone destruction around the jugular bulb in all patients with JPs. Fisch class C tumors are further classified into subgroups C1–C4 according to the extent of bone erosions around the carotid foramen, the carotid canal and the foramen lacerum. Patients with Fisch class D tumors have intracranial extension of the paraganglioma. Further subclassification is based on the extradural versus intradural extension and the depth of intracranial invasion. It is important to note that for JPs, Fisch class D cannot be used separately without also using the subclassification for class C. In paragangliomas with intracranial extension, the D classification should always be accompanied by a C classification (e.g. C3Di₂). Fisch classification before surgery is essential as the operative approach is determined by the tumor stage.

MOLECULAR GENETICS CLASSIFICATION

Current genetic classification is still incomplete and merits revision. To date, nine different susceptibility genes have been identified for tumors of the paraganglial system. The six relevant genes and associated syndromes are summarized in Table 3. It is important to note that some genes are frequently, and others rarely, mutated. The succinate dehydrogenase subunit D (*SDHD*) gene was first recognized as the susceptibility gene of paraganglioma syndrome type 1 (PGL 1) in 2000 (28). Subsequently, mutations of the B and C subunit genes (*SDHB* and *SDHC*) were described in patients with paraganglioma syndromes that were later designated as PGL type 3 and type 4 (29,30). The susceptibility gene for PGL 2 was identified nine years later (22). The *SDHAF2* gene, also called *SDH5*, affects flavination of *SDHA*. In 2010, the *SDHA* gene was identified as a tumor suppressor gene associated with paraganglial tumors (31). Also in 2010, a gene called *TMEM127* was found to be mutated in pheochromocytomas, i.e. exclusively adrenal paraganglial tumors (32). Meanwhile, it became evident that the spectrum of *TMEM127* mutations extends to HNPs (33). Rarely, mutations of the well-known genes causing multiple

Table 1 - The Shamblin classification of carotid body tumors.

Class	Tumor characteristics
I	Splicing of the carotid bifurcation with little attachment to the carotid vessels; complete resection with very little morbidity
II	Partial surrounding of internal and external carotid artery; complete resection more challenging
III	Complete surrounding of the carotid vessels; complete resection often requires major vessel reconstruction

endocrine neoplasia type 2 (MEN2), von Hippel-Lindau disease, and neurofibromatosis type 1 (*VHL*, *RET*, and *NF1*) may also predispose to HNPs.

The molecular pathomechanisms leading to the development of paraganglial tumors is still largely unknown. Various processes, including activation of hypoxia-inducible factor 1 α (HIF1 α)-related neoangiogenesis pathways (in von Hippel-Lindau and in SDHx-associated paraganglioma syndromes), as well as activation of the *Ras* oncogene pathways (in MEN2 and neurofibromatosis type 1) have been suggested. However, in HNP, the major pathomechanism may stem from the impaired function of mitochondria, manifesting either as activation of the pseudo-hypoxia pathway as a result of accumulation of succinate (which inhibits HIF- α prolyl hydroxylases; PHD), leading to stabilization and activation of HIF-1 α (34) or as increased oxidative stress and genomic instability (35,36). Systematic evaluation of genes involved in regulation of these pathways may reveal additional susceptibility genes. However, mutation analysis of PHD genes in patients with pheochromocytoma/paraganglioma and renal cell carcinoma showed no alterations (30).

The likelihood of identifying germline mutations in patients with HNP has been addressed by several studies. Our study, published in 2009 (37), with 598 patients with HNP, found SDHx germline mutations in 31% of patients (52% SDHD, 34% SDHB, and 14% SDHC). Predictors for a positive mutation test included family history, previous adrenal or extra-adrenal pheochromocytoma, multiple HNPs, age ≤ 40 years and male gender. The prevalence of germline mutations of the *VHL*, *RET*, and *NF1* genes among patients with HNP has also been evaluated by our group through extensive collaboration (38). Twelve patients were found to have hereditary non-SDHx HNPs out of a total of 809 patients with HNP and 2084 with VHL: 11 with germline *VHL* mutations and one with a *RET* mutation. The prevalence of hereditary HNP was 5 out of 1,000 in patients with VHL and nine out of 1,000 in patients with non-SDHx HNP. A comprehensive literature review revealed HNPs in five von Hippel-Lindau, two MEN2 and one neurofibromatosis type 1 patients, who previously had symptoms characteristic for von Hippel-Lindau disease, MEN2 or neurofibromatosis type 1. Thus far, the number of cases associated with mutations in *SDHA* gene is unknown.

This issue could be addressed from the other end, i.e. the prevalence of HNPs in carriers of SDHB and SDHD mutations. This has been recently investigated by a group from Birmingham in the UK (39), who compared the penetrance for HNP for mutation carriers of SDHB and

SDHD, and showed that the penetrance for SDHD was about twice as high as that of SDHB carriers. SDHD mutations induced HNPs about 20 years earlier compared with SDHB mutations.

A thorough genotype-phenotype study for different HNP loci is currently lacking in the literature. What we currently know is that patients with mutations of SDHB, SDHC, and SDHD genes may develop tumors in the carotid body and the vagal, jugular, and tympanic paraganglia (23,28). Patients with germline mutations of the SDHAF2 gene have been studied in detail by a Dutch and Spanish group in 2010 (40). So far, only a single mutation has been identified, and potentially all patients are relatives. CBTs have been shown in a patient with a TMEM127 germline mutation (33). More patients and details may be expected in forthcoming similar reports.

SURGICAL TREATMENT OF HNP

Surgery of carotid body tumors

In general, treatment options for HNPs comprise surgical resection, as well as irradiation therapy, stereotactic radiosurgery and permanent embolization (1,7,41). If necessary and promising, a combined treatment strategy could be used. The majority of cases of HNP should undergo complete surgical resection as this is the only therapeutic option potentially offering a cure for the patient and is therefore the treatment of choice (1,6–8,42).

CBTs are the most common type of HNPs, which are categorized according to the Shamblin classification discussed above (25). The principal goal of any surgical attempt concerning CBT is complete tumor resection via a transcervical approach (1,7,41). With complete surgical resection, the tumor is controlled locally in 89–100% of cases (1,43,44). However, the probability of postoperative cranial nerve dysfunction has to be taken into consideration, even in cases of successful surgical removal of CBT (1,7). In a large study on postoperative outcome in 1,181 patients with CBT, Anand et al. found permanent cranial nerve deficit in 21.8% of cases (26). Obviously, complication rates are directly related to tumor size. Therefore, the Shamblin classification is not only essential for description of tumor characteristics, but also for the estimation of risks concerning any kind of surgical removal. As the tumor class in the Shamblin classification increases (i.e. from I to III), surgical removal of CBT is expected to become more difficult and challenging. In cases with Shamblin Class III-rated CBTs, not only does the possibility of cranial nerve deficits increase but also permanent vascular and neural defects are frequently seen, as a result of the need for

Table 2 - Classification of jugulotympanic paragangliomas according to Fisch and Mattox.

Class	Location and extension of paraganglioma
A	Paragangliomas that arise along the tympanic plexus on promontory
B	Paragangliomas with invasion of the hypotympanon; cortical bone over jugular bulb intact
C ₁	Paragangliomas with erosion of the carotid foramen
C ₂	Paragangliomas with destruction of the vertical carotid canal
C ₃	Paragangliomas with involvement of the horizontal portion of the carotid canal; foramen lacerum intact
C ₄	Paragangliomas with invasion of the foramen lacerum and cavernous sinus
De _{1/2}	Paragangliomas with intracranial but extradural extension; De _{1/2} according to displacement of the dura (De ₁ = less than 2 cm, De ₂ = more than 2 cm)
Di _{1/2/3}	Paragangliomas with intracranial and intradural extension; Di _{1/2/3} according to depth of invasion into the posterior cranial fossa (Di ₁ = less than 2 cm, Di ₂ = between 2 and 4 cm, Di ₃ = more than 4 cm)

intra-operative interruption of the cerebral circulation for complete tumor resection (1,6).

Surgery of vagal paragangliomas

Similar to CBTs, most authorities prefer surgical resection of VPs (6–8,42,45). If surgical removal of VP is successfully performed, local tumor control can be achieved in up to 100% of cases (43,44,46). Postoperative cranial nerve dysfunction is considered a major complication of transcranial surgical resection of these tumors (7,8). Unfortunately, in most cases of VP, it is necessary to sacrifice the vagal nerve intra-operatively (47). A promising study by Miller et al. demonstrated higher preservation rates of the vagal nerve by microsurgical techniques during surgical removal (8). As for CBTs, the rate of surgical complications in VP also increases with tumor size, but, unlike CBT, there exists no generally accepted classification system for VP (1). Therefore, estimation of possible postoperative complications is solely dependent on the surgeon's experience and pre-operative imaging.

Surgery of skull base paragangliomas

Paragangliomas of the temporal bone are usually differentiated into TPs and JPs, based on the Fisch classification (27). Using this classification, the feasibility of (complete) surgical resection can be estimated by the surgeon. Whenever possible, surgical resection is the treatment of choice for patients with TP or JP, depending on tumor size, patient age, and other possibly intervening individualized factors. TPs are usually categorized as Fisch A and B. Surgical removal is the treatment of choice. Major postoperative complications such as cranial nerve deficits are usually not expected, but minor complications such as postoperative conductive hearing loss may occur (45). In cases categorized as Fisch A and B, a transmeatal approach or a surgical approach via mastoidectomy, including posterior tympanotomy and exposure of the facial nerve, may be adequate (14). In some cases of TP categorized as class B, a juxtacondylar approach might be necessary (14,48).

There is an ongoing debate on treatment modalities when it comes to JP (1,48). These masses are categorized as Fisch C and D tumors (1,7,41). Thanks to development and implementation of microsurgical techniques, it is possible to resect these tumors completely, and local tumor control can be achieved in 80–90% of cases (41,49,50). JP (Fisch classification C and D) are usually resected via an infratemporal approach. Tumors classified as Fisch C₁, C₂ and De, Di_{1/2} may demand a variant of the juxtacondylar approach (14). It is important to note that because these tumors are adherent and occasionally invade cranial nerves IX–XII, a higher complication risk concerning cranial nerve deficits is anticipated for the postoperative outcome. Patients may therefore experience problems, including swallowing, voice, articulation, and shoulder weakness (7). Consequently, further surgical procedures in an attempt to correct these complications may be necessary in these patients (1,7). In general, tumors classified as Fisch Di_{1/2} should be resected in a two-stage, team-approach procedure involving neurosurgeons. This therapeutic option is not available for patients categorized as Fisch Di₃. In these cases, palliative radiotherapy is advocated (14). Current literature shows that the long-term success rate following surgical therapy of JP is 72–95%; however, it should be noted that

comparison of results emerging from different studies is difficult because parameters such as Fisch classification and follow-up intervals are not consistent between studies (14).

NEUROSURGICAL ASPECTS OF SKULL BASE PARAGANGLIOMAS

Skull base paragangliomas are rare tumors, even in major referral neurosurgical centers, and they remain challenging, due to their vascularized nature and deep intra-/extra-cranial location. These tumors may involve the jugular bulb, middle ear, petrous apex, clivus, carotid artery, infratemporal and posterior fossa. Despite their benign nature in the majority of cases, these tumors tend to invade adjacent structures, which may sometimes preclude complete resection of these lesions. In order to achieve a good clinical outcome, close collaboration between ear, nose, and throat (ENT) surgeons, neurosurgeons, and interventional neuroradiologists is of paramount importance.

The surgical approach is determined by the size and anatomical location of the tumor. After careful analysis of MRI and thin-section CT, the surgical approach is planned with collaborative teamwork to address all aspects of the tumor. The approach should be wide, as these tumors bleed profusely on manipulation. The possibility of severe blood loss needs to be considered in pre-operative planning. Pre-operative embolization is generally recommended, especially for larger tumors. This will allow for safer surgery as a result of less intraoperative blood loss and better visualization of the structures.

Small tumors in the jugular bulb may be removed by a transjugular approach. Other approaches include the transmastoid and combined approaches (51). The intracranial part of larger tumors is frequently best removed by an infratemporal approach.

Intraoperative neuromonitoring is mandatory and should include at least electromyography of the involved cranial nerves. For tumors with major intracranial extension, motor, sensory and auditory evoked potentials may become necessary. The anesthesiologist needs to be informed about this, and plan accordingly (no gas, no long-acting muscle relaxants). The introduction of intra-operative neuromonitoring has significantly improved postoperative outcome, particularly in sparing the facial nerve during skull-base surgery (52).

HISTOPATHOLOGY

The HNPs described above have a similar histopathologic appearance. Under the microscope, two types of cells displaying typical nest-like or alveolar architectural pattern are seen. Type I cells, or chief cells, are epithelioid cells often with enlarged hyperchromatic nuclei and arranged in solid groups called "Zellballen". These groups of chief cells are surrounded by a flattened layer of type II cells or sustentacular cells, which can be visualized by immunohistochemical staining for S-100 protein (Figure 3). Type I and type II cells characteristically lie within a dense network of capillaries.

Chief cells may be quite uniform or may display pronounced nuclear pleomorphism, such as bizarre and huge multinucleated cells. They are immunohistochemically positive for chromogranins (HNP shows strong expression of chromogranin B, whereas chromogranin A is expressed

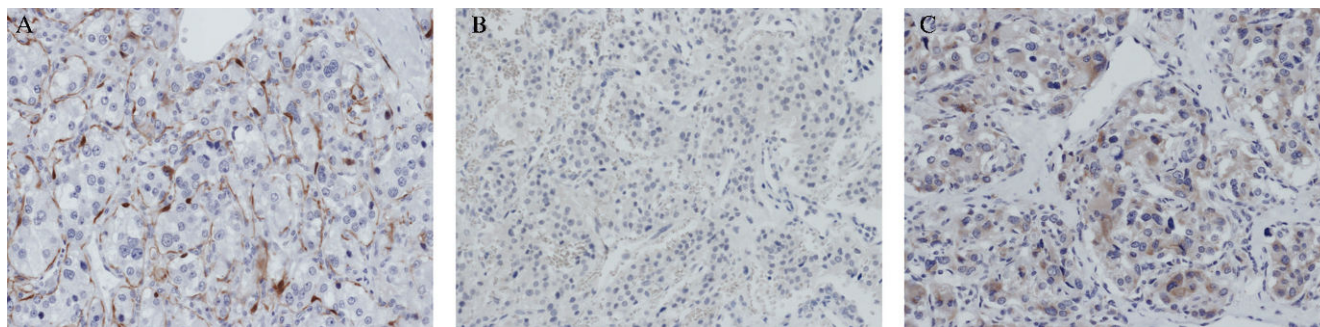


Figure 3 - Histology and immunostaining of head and neck paragangliomas. (A) Demonstration of sustentacular cells by S-100 protein in an HNP. The delicate net of sustentacular cells is surrounding the so-called Zellballen of chief cells (x200). (B) Complete immunohistochemical negativity for SDHB strongly suggesting a SDHB germline mutation (x200). (C) Immunohistochemical demonstration of SDHB protein in tumor cells, virtually excluding a germline mutation in *SDHB* (x200).

to a much lesser degree (53) and synaptophysin, yet are negative to cytokeratin, in contrast to some pheochromocytomas and paragangliomas of the filum terminale. Unfortunately, nuclear pleomorphism, mitotic activity, necrosis, or vascular or perineural invasion cannot predict the biological behavior, as all these features may also be found in benign HNPs.

Several attempts have been made to histologically distinguish benign tumors from the rare malignant paraganglial tumors. These are based on scoring systems that have been introduced for pheochromocytomas and paragangliomas of the retroperitoneum, although no scoring system has been generally accepted as yet. The most popular scoring system has been suggested by Thompson

Table 3 - Molecular classification of head and neck paragangliomas (HNPs).

Syndrome	VHL	PGL1	PGL2	PGL3	PGL4	TMEM127
MIM ID	193300	168000	60650	605373	115310	613903
Inheritance	Autosomal Dominant	Autosomal Dominant with parent-of-origin effect	Autosomal Dominant with parent-of-origin effect	Autosomal Dominant	Autosomal Dominant	Autosomal dominant
Gene name	VHL	SDHD	SDHAF2	SDHC	SDHB	TMEM127
Protein function	An ubiquitin ligase protein; it plays a role in the oxygen-sensing pathway	One of two membrane-anchoring subunits of complex II (SDH)	Mitochondrial assembly factor for complex II—interacts directly with SDHA	One of two membrane-anchoring subunits of complex II (SDH)	The iron-sulfur protein that form together with SDHA, the main catalytic domain of complex II	Endosomal trafficking?; mTOR regulation?
Locus	3p25-26	11q23	11q13.1	1q21	1p36	2q11
Age at diagnosis of Pheochromocytoma mean and range, in years	22 (5–67)	27 (5–65)	unknown	Extremely rare	34 (12–66)	43 (34–54)
Exons (n)/amino acids (n)	3/213	4/159	4/166	6/169	8/280	3/238
HNP (%)	0.5	41	73–86	100	8	1–2
Age at diagnosis HNP Median (range, in years)	23 (7–39)	40 (12–74)	45 (15–65)	46 (13–73)	42 (9–75)	34
Pheo risk (%)	10–34	53	0	<3	28	25
PG Abdominal extraadrenal (%)	17	59	0	0	62	1–2
Multifocality (%)	56	55	0	9	11	33
Malignant (%)	4%	0	0	0	32	5
Clinical Phenotype	Sympathetic Noradrenergic	Parasympathetic, occasionally noradrenergic	Parasympathetic	Parasympathetic	Noradrenergic	Sympathetic Noradrenergic
Associated tumors	Eye and CNS hemangioblastomas, clear cell renal cancer, islet cell tumors, endolymphatic sac tumors of the inner ear	Rarely Papillary thyroid cancer, GIST	GIST	GIST	Rarely renal cell cancer GIST	

Adapted from Bausch et al. (73), Hensen et al. (74) and Neumann and Eng (75).

CNS = central nervous system; GIST = gastrointestinal stromal tumor, mTOR = mammalian target of rapamycin; PGL = Paraganglioma syndrome; SDHAF2 = succinate dehydrogenase complex assembly factor 2; TMEM127 = transmembrane protein 127.

(54), and includes a variety of criteria, such as cellular and nuclear features, growth patterns, or occurrence of necrosis. It has to be emphasized that only the occurrence of lymph node and/or distant metastases are the ultimate criteria for malignancy. Morphologic demonstration of tumor invasion to adjacent structures including bone does not indicate biologic malignancy. Isolated tumor nodules in the vicinity of the main tumor may represent multicentricity of the HNP. Such tumor nodules can only be interpreted as lymph node metastases if they are embedded into (remnants of) lymphatic tissue.

Immunohistochemical staining with antibodies against SDHB protein has been found to be associated with germline mutations of the *SDHB*, *SDHC*, and *SDHD* genes (Figures 3A and B) (55). As a result, immunostaining has become a screening method to select patients for subsequent molecular genetic testing. The value of immunostaining against SDHB and other proteins is currently under investigation, and the importance for routine histopathology and genetics will be corroborated in expected additional analyses (56).

OUTCOME AND CHALLENGES

Management of head and neck paragangliomas is challenging for every physician, especially in cases of multiple paragangliomas or tumors in an advanced stage. The outcome mainly depends on the stage of tumor at initial presentation.

For Shamblin type I and type II CBTs, the peri- and postoperative risk of neurovascular complications is low (57). Complication rate increases strongly for Shamblin type III CBTs (57,58). The current literature shows serious postoperative complications only in 0–2.3% of patients with Shamblin type I and II tumors, while this figure increases to 7–35.7% for patients with a Shamblin type III tumor (57–59).

For JP, surgical control is achieved in about 70–86% of patients, even in Fisch class C and D tumors (45,60–62). Although postoperative functional deficit of the cranial nerves occurs, patients seem to be able to cope with the new limitations within two years and get back to a normal social life (60). While total resection of the tumors should be performed as a curative treatment for paragangliomas (62,63), a subtotal removal may be required to preserve cranial nerve function. In such cases, subtotal tumor resection, combined with gamma-knife surgery or radiation therapy, has proved to be a safe and effective treatment modality (61,64–66). In the elderly, it is important to weigh up the possible disabilities after surgical therapy, so a more conservative treatment concept might be preferred (61,67). The outcome after surgical removal of TP (Fisch type A) is normally very good, with preservation of hearing in more than 90% of cases (63,68–70); therefore, surgical resection of these tumors is the therapy of choice (63,68,70).

VPs are special. They originate from the vagus nerve, so surgical removal of these tumors will be associated with a loss of vagal nerve function in the vast majority of cases (39,71,72) despite the fact that the nerve is kept anatomically intact (72). The immediate consequences would be hoarseness, dysphagia, and aspiration. The situation is even worse for extensive VPs, where additional cranial nerve deficits (in about 50–60% of patients) are seen because of the close proximity of the tumor in the jugular foramen to cranial nerves IX, XI, and XII (39,71,72). Bradshaw and Jansen described a group of 40 patients with VPs, in whom a

wait-and-scan policy was chosen (39). Only three of these patients developed cranial nerve palsy during an average follow-up of 8.5 years. It should be kept in mind that the morbidity of a cranial nerve palsy caused by surgery is higher than the morbidity caused by slow fading of the nerve function through the tumor (72). Hence, surgical removal of VPs should be weighed against the patient's age, size of the tumor, predicted tumor growth and cranial nerve function (72).

ACKNOWLEDGMENTS

This work is funded, in part, by the German Cancer Foundation (Deutsche Krebshilfe Grant 107995 to HPHN).

AUTHOR CONTRIBUTIONS

Offergeld C, Brase C, Yaremchuk S, Preuss SF, Suarez C, Kopeć T, Malekpour M, Boedeker CC, Schmid KW, Wiech T wrote the sections "Signs and symptoms", "Clinical classification" and "Surgery". Mader I wrote the section "Radiology". Rischke HC wrote the section "Nuclear imaging". Gläsker S wrote the section "Neurosurgery". Patocs A, Wohlhik N, Neumann HPH wrote the section "Molecular genetics". Neumann HPH coordinated the work. All authors edited the text and approved the final version.

REFERENCES

- Boedeker CC, Ridder GJ, Schipper J. Paragangliomas of the head and neck: diagnosis and treatment. *Fam Cancer*. 2005;4(1):55-9, <http://dx.doi.org/10.1007/s10689-004-2154-z>.
- Jackson CG, Glasscock ME, 3rd, Harris PF. Glomus Tumors. Diagnosis, classification, and management of large lesions. *Arch Otolaryngol*. 1982;108(7):401-10.
- Kollert M, Minovi A, Mangold R, Hendus J, Draf W, Bockmuhl U. [Paraganglioma of the head and neck—tumor control, functional results and quality of life]. *Laryngorhinootologie*. 2006;85(9):649-56. Paragangliome des Kopf-Hals-Bereiches—Tumorkontrolle, funktionelle Ergebnisse und Lebensqualität nach Operation.
- Sykes JM, Ossoff RH. Paragangliomas of the head and neck. *Otolaryngol Clin North Am*. 1986;19(4):755-67.
- Wasserman PG, Savargaonkar P. Paragangliomas: classification, pathology, and differential diagnosis. *Otolaryngol Clin North Am*. 2001;34(5):845-62, v-vi, [http://dx.doi.org/10.1016/S0030-6665\(05\)70351-0](http://dx.doi.org/10.1016/S0030-6665(05)70351-0).
- Patetsios P, Gable DR, Garrett WV, Lamont JP, Kuhn JA, Shutze WP, et al. Management of carotid body paragangliomas and review of a 30-year experience. *Ann Vasc Surg*. 2002;16(3):331-8, <http://dx.doi.org/10.1007/s10016-001-0106-8>.
- Persky MS, Setton A, Niimi Y, Hartman J, Frank D, Berenstein A. Combined endovascular and surgical treatment of head and neck paragangliomas: a team approach. *Head Neck*. 2002;24(5):423-31, <http://dx.doi.org/10.1002/hed.10068>.
- Miller RB, Boon MS, Atkins JP, Lowry LD. Vagal paraganglioma: the Jefferson experience. *Otolaryngol Head Neck Surg*. 2000;122(4):482-7, [http://dx.doi.org/10.1016/S0194-5998\(00\)70088-X](http://dx.doi.org/10.1016/S0194-5998(00)70088-X).
- Gehrking E, Gliemroth J, Missler U, Rimmert S. [Main symptom: "pulse-synchronous tinnitus"]. *Laryngorhinootologie*. 2000;79(9):510-6. Hauptsymptom: "Pulssynchrones Ohrgeräusch", <http://dx.doi.org/10.1055/s-2000-6944>.
- Urquhart AC, Johnson JT, Myers EN, Schechter GL. Glomus vagale: paraganglioma of the vagus nerve. *Laryngoscope*. 1994;104(4):440-5.
- Heinrich MC, Harris AE, Bell WR. Metastatic intravagal paraganglioma. Case report and review of the literature. *Am J Med*. 1985;78(6 Pt 1):1017-24, [http://dx.doi.org/10.1016/0002-9343\(85\)90226-8](http://dx.doi.org/10.1016/0002-9343(85)90226-8).
- Jackson CG. Glomus tympanicum and glomus jugulare tumors. *Otolaryngol Clin North Am*. 2001;34(5):941-70, vii, [http://dx.doi.org/10.1016/S0030-6665\(05\)70356-X](http://dx.doi.org/10.1016/S0030-6665(05)70356-X).
- Rosenwasser H. Glomus jugulare tumors. I. Historical background. *Arch Otolaryngol*. 1968;88(1):1-40.
- Boedeker CC. [Paragangliomas and paraganglioma syndromes]. *Laryngorhinootologie*. 2011;90(Suppl 1):S56-82. Paragangliome und Paragangliomasyndrome, <http://dx.doi.org/10.1055/s-0030-1270447>.
- Alkadhi H, Schuknecht B, Stoeckli SJ, Valavanis A. Evaluation of topography and vascularization of cervical paragangliomas by magnetic resonance imaging and color duplex sonography. *Neuroradiology*. 2002;44(1):83-90.
- Stoeckli SJ, Schuknecht B, Alkadhi H, Fisch U. Evaluation of paragangliomas presenting as a cervical mass on color-coded Doppler

- sonography. *Laryngoscope*. 2002;112(1):143-6, <http://dx.doi.org/10.1097/00005537-200201000-00025>.
17. HR. H. Glomus Tympanicum Paraganglioma. In: Harnsberger HR, ed. *Diagnostic Imaging Head and Neck* Altona Manitoba, Canada. Amirsys Inc., Salt Lake City, UT, USA, I-82-83 2005.
 18. van den Berg R. Imaging and management of head and neck paragangliomas. *Eur Radiol*. 2005;15(7):1310-8, <http://dx.doi.org/10.1007/s00330-005-2743-8>.
 19. Christie A, Teasdale E. A comparative review of multidetector CT angiography and MRI in the diagnosis of jugular foramen lesions. *Clin Radiol*. 2010;65(3):213-7, <http://dx.doi.org/10.1016/j.crad.2009.11.006>.
 20. Zeitler DM, Glick J, Har-El G. Preoperative embolization in carotid body tumor surgery: is it required? *Ann Otol Rhinol Laryngol*. 2010;119(5):279-83.
 21. Kwekkeboom DJ, van Urk H, Pauw BK, Lamberts SW, Kooij PP, Hoogma RP, et al. Octreotide scintigraphy for the detection of paragangliomas. *J Nucl Med*. 1993;34(6):873-8.
 22. Naji M, Zhao C, Welsh SJ, Meades R, Win Z, Ferrarese A, et al. (68)Ga-DOTA-TATE PET vs. (123)I-MIBG in Identifying Malignant Neural Crest Tumours. *Mol Imaging Biol*. 2011;13(4): 769-75, <http://dx.doi.org/10.1007/s11307-010-0396-8>.
 23. Neumann HP, Pawlu C, Peczkowska M, Bausch B, McWhinney SR, Muresan M, et al. Distinct clinical features of paraganglioma syndromes associated with SDHB and SDHD gene mutations. *JAMA*. 2004;292(8): 943-51, <http://dx.doi.org/10.1001/jama.292.8.943>.
 24. Havekes B, King K, Lai EW, Romijn JA, Corssmit EP, Pacak K. New imaging approaches to pheochromocytomas and paragangliomas. *Clin Endocrinol (Oxf)*. 2010;72(2):137-45, <http://dx.doi.org/10.1111/j.1365-2265.2009.03648.x>.
 25. Shamblyn WR, ReMine WH, Sheps SG, Harrison EG Jr. Carotid body tumor (chemodectoma). Clinicopathologic analysis of ninety cases. *Am J Surg*. 1971;122(6):732-9, [http://dx.doi.org/10.1016/0002-9610\(71\)90436-3](http://dx.doi.org/10.1016/0002-9610(71)90436-3).
 26. Anand VK, Alemar GO, Sanders TS. Management of the internal carotid artery during carotid body tumor surgery. *Laryngoscope*. 1995;105 (3 Pt 1):231-5, <http://dx.doi.org/10.1288/00005537-199503000-00001>.
 27. Fisch U MD. Microsurgery of the skull base. Stuttgart: Thieme; 1988.
 28. Schiavi F, Boedeker CC, Bausch B, Peczkowska M, Gomez CF, Strassburg T, et al. Predictors and prevalence of paraganglioma syndrome associated with mutations of the SDHC gene. *JAMA*. 2005;294(16):2057-63, <http://dx.doi.org/10.1001/jama.294.16.2057>.
 29. Niemann HP, Muller U. Mutations in SDHC cause autosomal dominant paraganglioma, type 3. *Nat Genet*. 2000;26(3):268-70.
 30. Astuti D, Ricketts CJ, Chowdhury R, McDonough MA, Gentle D, Kirby G, et al. Mutation analysis of HIF prolyl hydroxylases (PHD/EGLN) in individuals with features of pheochromocytoma and renal cell carcinoma susceptibility. *Endocr Relat Cancer*. 2010;18(1):73-83, <http://dx.doi.org/10.1677/ERC-10-0113>.
 31. Burnichon N, Briere JJ, Libe R, Vescovo L, Riviere J, Tissier F, et al. SDHA is a tumor suppressor gene causing paraganglioma. *Hum Mol Genet*. 2010;19(15):3011-20, <http://dx.doi.org/10.1093/hmg/ddq206>.
 32. Yao L, Schiavi F, Cascon A, Qin Y, Ingla-Perez L, King EE, et al. Spectrum and prevalence of FP/TMEM127 gene mutations in pheochromocytomas and paragangliomas. *JAMA*. 2010;304(23):2611-9, <http://dx.doi.org/10.1001/jama.2010.1830>.
 33. Neumann HP, Sullivan M, Winter A, Malinoc A, Hoffmann MM, Boedeker CC, et al. Germline mutations of the TMEM127 gene in patients with paraganglioma of head and neck and extraadrenal abdominal sites. *J Clin Endocrinol Metab*. 2011;96(8):E1279-82.
 34. Selak MA, Armour SM, MacKenzie ED, Boulahbel H, Watson DG, Mansfield KD, et al. Succinate links TCA cycle dysfunction to oncogenesis by inhibiting HIF- α prolyl hydroxylase. *Cancer Cell*. 2005;7(1):77-85, <http://dx.doi.org/10.1016/j.ccr.2004.11.022>.
 35. Ishii T, Yasuda K, Akatsuka A, Hino O, Hartman PS, Ishii N. A mutation in the SDHC gene of complex II increases oxidative stress, resulting in apoptosis and tumorigenesis. *Cancer Res*. 2005;65(1):203-9.
 36. Slane BG, Aykin-Burns N, Smith BJ, Kalen AL, Goswami PC, Domann FE, et al. Mutation of succinate dehydrogenase subunit C results in increased O₂•, oxidative stress, and genomic instability. *Cancer Res*. 2006;66(15):7615-20, <http://dx.doi.org/10.1158/0008-5472.CAN-06-0833>.
 37. Neumann HP, Erlic Z, Boedeker CC, Rybicki LA, Robledo M, Hermesen M, et al. Clinical predictors for germline mutations in head and neck paraganglioma patients: cost reduction strategy in genetic diagnostic process as fall-out. *Cancer Res*. 2009;69(8):3650-6, <http://dx.doi.org/10.1158/0008-5472.CAN-08-4057>.
 38. Boedeker CC, Erlic Z, Richard S, Kontny U, Gimenez-Roqueplo AP, Cascon A, et al. Head and neck paragangliomas in von Hippel-Lindau disease and multiple endocrine neoplasia type 2. *J Clin Endocrinol Metab*. 2009;94(6):1938-44, <http://dx.doi.org/10.1210/jc.2009-0354>.
 39. Ricketts CJ, Forman JR, Rattenberry E, Bradshaw N, Lalloo F, Izatt L, et al. Tumor risks and genotype-phenotype-proteotype analysis in 358 patients with germline mutations in SDHB and SDHD. *Hum Mutat*. 2010;31(1):41-51, <http://dx.doi.org/10.1002/humu.21136>.
 40. Bayley JP, Kunst HP, Cascon A, Sampietro ML, Gaal J, Korpershoek E, et al. SDHAF2 mutations in familial and sporadic paraganglioma and pheochromocytoma. *Lancet Oncol*. 2010;11(4):366-72, [http://dx.doi.org/10.1016/S1470-2045\(10\)70007-3](http://dx.doi.org/10.1016/S1470-2045(10)70007-3).
 41. Foote RL, Pollock BE, Gorman DA, Schomberg PJ, Stafford SL, Link MJ, et al. Glomus jugulare tumor: tumor control and complications after stereotactic radiosurgery. *Head Neck*. 2002;24(4):332-8, <http://dx.doi.org/10.1002/hed.10005>.
 42. Wang SJ, Wang MB, Barauskas TM, Calcatera TC. Surgical management of carotid body tumors. *Otolaryngol Head Neck Surg*. 2000;123(3):202-6, <http://dx.doi.org/10.1067/mhn.2000.106709>.
 43. Hinerman RW, Mendenhall WM, Amdur RJ, Stringer SP, Antonelli PJ, Cassisi NJ. Definitive radiotherapy in the management of chemodectomas arising in the temporal bone, carotid body, and glomus vagale. *Head Neck*. 2001;23(5):363-71, <http://dx.doi.org/10.1002/hed.1045>.
 44. Hodge KM, Byers RM, Peters LJ. Paragangliomas of the head and neck. *Arch Otolaryngol Head Neck Surg*. 1988;114(8):872-7, <http://dx.doi.org/10.1001/archotol.1988.01860200056018>.
 45. Gstottnner W, Matula C, Hamzavi J, Kornfehl J, Czerny C. Long-term results of different treatment modalities in 37 patients with glomus jugulare tumors. *Eur Arch Otorhinolaryngol*. 1999;256(7):351-5, <http://dx.doi.org/10.1007/s004050050162>.
 46. Biller HF, Lawson W, Som P, Rosenfeld R. Glomus vagale tumors. *Ann Otol Rhinol Laryngol*. 1989;98(1 Pt 1):21-6.
 47. Thabet MH, Kotob H. Cervical paragangliomas: diagnosis, management and complications. *J Laryngol Otol*. 2001;115(6):467-74.
 48. Schipper J, Spetzger U, Tagatiga M, Rosahl S, Neumann HP, Boedeker CC, et al. Juxtacondylar approach in temporal paraganglioma surgery: when and why? *Skull Base*. 2009;19(1):43-7, <http://dx.doi.org/10.1055/s-0028-1103129>.
 49. Ivan ME, Sughrue ME, Clark AJ, Kane AJ, Aranda D, Barani JJ, et al. A meta-analysis of tumor control rates and treatment-related morbidity for patients with glomus jugulare tumors. *J Neurosurg*. 2011;114(5):1299-305.
 50. Powell S, Peters N, Harmer C. Chemodectoma of the head and neck: results of treatment in 84 patients. *Int J Radiat Oncol Biol Phys*. 1992;22(5):919-24.
 51. Liu JK, Sameshima T, Gottfried ON, Couldwell WT, Fukushima T. The combined transmastoid retro- and infralabyrinthine transjugular transcondylar transtuberular high cervical approach for resection of glomus jugulare tumors. *Neurosurgery*. 2006;59(1 Suppl 1):ONS115-25.
 52. Leonetti JP, Brackmann DE, Prass RL. Improved preservation of facial nerve function in the infratemporal approach to the skull base. *Otolaryngol Head Neck Surg*. 1989;101(1):74-8.
 53. Schmid KW, Schroder S, Dockhorn-Dworniczak B, Kirchmair R, Totsch M, Bocker W, et al. Immunohistochemical demonstration of chromogranin A, chromogranin B, and secretogranin II in extra-adrenal paragangliomas. *Mod Pathol*. 1994;7(3):347-53.
 54. Thompson LD. Pheochromocytoma of the Adrenal gland Scaled Score (PASS) to separate benign from malignant neoplasms: a clinicopathologic and immunophenotypic study of 100 cases. *Am J Surg Pathol*. 2002;26(5):551-66, <http://dx.doi.org/10.1097/0000478-200205000-00002>.
 55. van Nederveen FH, Gaal J, Favier J, Korpershoek E, Oldenburg RA, de Bruyn EM, et al. An immunohistochemical procedure to detect patients with paraganglioma and pheochromocytoma with germline SDHB, SDHC, or SDHD gene mutations: a retrospective and prospective analysis. *Lancet Oncol*. 2009;10(8):764-71, [http://dx.doi.org/10.1016/S1470-2045\(09\)70164-0](http://dx.doi.org/10.1016/S1470-2045(09)70164-0).
 56. Span PN, Rao JU, Oude Ophuis SB, Lenders JW, Sweep FC, Wesseling P, et al. Overexpression of the natural antisense hypoxia-inducible factor-1 α transcript is associated with malignant pheochromocytoma/paraganglioma. *Endocr Relat Cancer*. 2011;18(3):323-31, <http://dx.doi.org/10.1530/ERC-10-0184>.
 57. Lim JY, Kim J, Kim SH, Lee S, Lim YC, Kim JW, et al. Surgical treatment of carotid body paragangliomas: outcomes and complications according to the shamblyn classification. *Clin Exp Otorhinolaryngol*. 2010;3(2):91-5, <http://dx.doi.org/10.3342/ceo.2010.3.2.91>.
 58. Plukker JT, Brongers EP, Vermey A, Krikke A, van den Dungen JJ. Outcome of surgical treatment for carotid body paraganglioma. *Br J Surg*. 2001;88(10):1382-6, <http://dx.doi.org/10.1046/j.0007-1323.2001.01878.x>.
 59. Makeieff M, Raingeard I, Alric P, Bonafe A, Guerrier B, Marty-Ane C. Surgical management of carotid body tumors. *Ann Surg Oncol*. 2008;15(8):2180-6, <http://dx.doi.org/10.1245/s10434-008-9977-z>.
 60. Briner HR, Linder TE, Pauw B, Fisch U. Long-term results of surgery for temporal bone paragangliomas. *Laryngoscope*. 1999;109(4):577-83, <http://dx.doi.org/10.1097/00005537-199904000-00011>.
 61. Huy PT, Kania R, Duet M, Dessard-Diana B, Mazeran JJ, Benhamed R. Evolving concepts in the management of jugular paraganglioma: a comparison of radiotherapy and surgery in 88 cases. *Skull Base*. 2009;19(1):83-91, <http://dx.doi.org/10.1055/s-0028-1103125>.
 62. Sanna M, Jain Y, De Donato G, Rohit, Lauda L, Taibah A. Management of jugular paragangliomas: the Gruppo Otologico experience. *Otol Neurotol*. 2004;25(5):797-804, <http://dx.doi.org/10.1097/00129492-200409000-00025>.

63. Sanna M, Fois P, Pasanisi E, Russo A, Bacciu A. Middle ear and mastoid glomus tumors (glomus tympanicum): an algorithm for the surgical management. *Auris Nasus Larynx*. 2010;37(6):661-8, <http://dx.doi.org/10.1016/j.anl.2010.03.006>.
64. Fayad JN, Keles B, Brackmann DE. Jugular foramen tumors: clinical characteristics and treatment outcomes. *Otol Neurotol*. 2010;31(2):299-305, <http://dx.doi.org/10.1097/MAO.0b013e3181be6495>.
65. Miller JP, Semaan M, Einstein D, Megerian CA, Maciunas RJ. Staged Gamma Knife radiosurgery after tailored surgical resection: a novel treatment paradigm for glomus jugulare tumors. *Stereotact Funct Neurosurg*. 2009;87(1):31-6, <http://dx.doi.org/10.1159/000195717>.
66. Saringer W, Kitz K, Czerny C, Kornfehl J, Gstottner W, Matula C, et al. Paragangliomas of the temporal bone: results of different treatment modalities in 53 patients. *Acta Neurochir (Wien)*. 2002;144(12):1255-64, <http://dx.doi.org/10.1007/s00701-002-1016-4>.
67. Cosetti M, Linstrom C, Alexiades G, Tessema B, Parisier S. Glomus tumors in patients of advanced age: a conservative approach. *Laryngoscope*. 2008;118(2):270-4, <http://dx.doi.org/10.1097/MLG.0b013e318158194b>.
68. Durvasula VS, De R, Baguley DM, Moffat DA. Laser excision of glomus tympanicum tumours: long-term results. *Eur Arch Otorhinolaryngol*. 2005;262(4):325-7, <http://dx.doi.org/10.1007/s00405-004-0822-0>.
69. Papaspyrou K, Mann WJ, Amedee RG. Management of head and neck paragangliomas: review of 120 patients. *Head Neck*. 2009;31(3):381-7, <http://dx.doi.org/10.1002/hed.20967>.
70. Papaspyrou K, Mewes T, Toth M, Schmidtmann I, Amedee RG, Mann WJ. Hearing results after hypotympanotomy for glomus tympanicum tumors. *Otol Neurotol*. 2011;32(2):291-6, <http://dx.doi.org/10.1097/MAO.0b013e3182001edb>.
71. Netterville JL, Jackson CG, Miller FR, Wanamaker JR, Glasscock ME. Vagal paraganglioma: a review of 46 patients treated during a 20-year period. *Arch Otolaryngol Head Neck Surg*. 1998;124(10):1133-40.
72. Zanoletti E, Mazzoni A. Vagal paraganglioma. *Skull Base*. 2006;16(3):161-7, <http://dx.doi.org/10.1055/s-2006-949519>.
73. Bausch B, Borozdin W, Neumann HP. Clinical and genetic characteristics of patients with neurofibromatosis type 1 and pheochromocytoma. *N Engl J Med*. 2006;354(25):2729-31, <http://dx.doi.org/10.1056/NEJMc066006>.
74. Hensen EF, Bayley JP. Recent advances in the genetics of SDH-related paraganglioma and pheochromocytoma. *Fam Cancer*. 2011;10(2):355-63, <http://dx.doi.org/10.1007/s10689-010-9402-1>.
75. Neumann HP, Eng C. The approach to the patient with paraganglioma. *J Clin Endocrinol Metab*. 2009;94(8):2677-83, <http://dx.doi.org/10.1210/jc.2009-0496>.