

LETTER TO THE EDITOR

EXPECTORATION OF LARGE BRONCHIAL CASTS SECONDARY TO THE TREATMENT OF CHRONIC HEPATITIS C WITH PEGYLATED INTERFERON AND RIBAVIRIN

doi: 10.1590/S1807-59322010000700016

Evaldo Stanislau Affonso de Araújo, Aleia Faustina Campos, Juliana Yamashiro, Evandro Sobrosa Mello, Teresa Takagaki, Antonio Alci Barone

INTRODUCTION

Infections caused by the hepatitis C virus (HCV) are currently a serious public health problem. It is estimated that 3 to 4 million new cases occur worldwide every year. Of the individuals with acute HCV infections, 55% to 85% will be chronically infected and will thus be at risk of liver damage, cirrhosis and hepatocellular carcinoma.^{1,2} In total, more than 170 million people (i.e., $\approx 2\%$ of the world's population) are infected with HCV. The best treatment currently available is a combination of pegylated interferon and ribavirin.²⁻⁶

Interferons are potent cytokines with antiviral, antiproliferative and immunomodulatory activities.⁷ Interferons are linked to cell surface receptors and cause a cascade of intracellular events, including the induction of the transcription of genes that inhibit cell growth and of genes that alter cell differentiation, oncogene expression and the expression of antigens on the cell surface. In turn, these effects increase macrophage phagocytosis and the cytotoxicity of lymphocytes in relation to target cells and hinder mechanisms of viral replication in parasitic cells. The treatment of hepatitis C has various limitations: cost, efficacy and, principally, adverse effects. The numerous side effects observed range from the trivial, such as influenza-like symptoms, anorexia, fatigue, headache, nausea myalgia, diarrhea, local reactions to the application of the medication, alopecia and pruriginous rash, to the severe, such as psychiatric symptoms, cytopenias and respiratory symptoms (cough and dyspnea). Among the rarest and most potentially deleterious adverse manifestations are pancreatitis, profound

medullary depression and cardiotoxicity, which can lead to cardiac failure and sudden death.^{2,3,8,9} Finally, it has been suggested that interferon alpha therapy is associated with the development and exacerbation of autoimmune diseases.³

Severe lung toxicity is associated with interferon alpha monotherapy as well as combination therapies involving ribavirin and conventional or pegylated interferon alpha. There have also been reported cases of interstitial pneumonia,^{2,10} bronchiolitis obliterans organizing pneumonia (BOOP), sarcoidosis and severe profiles of asthma exacerbation.⁹ For example, Kuno et al. described three cases involving patients with chronic hepatitis C who developed interstitial pneumonitis during treatment with interferon alpha and presented complete resolution of the symptoms after discontinuation of the medication.¹¹ Nevertheless, pulmonary complications associated with interferon alpha therapy are rare. In the literature, the pathology most commonly associated with interferon alpha therapy is interstitial pneumonitis, followed by sarcoidosis-like conditions leading to the formation of noncaseating granulomas.^{3,7,8}

Ribavirin is a purinic nucleoside analog with a modified base and a D-ribose sugar. Although the mechanisms of ribavirin action continue to be the object of speculation, it is possible that ribavirin acts as an immunostimulating antiviral agent and has recently been proposed to be a stimulator of inducible interferon genes.¹² When combined with interferon alpha, ribavirin contributes greatly to obtaining a sustained virological response (SVR) and to reducing recurrence. Ribavirin side effects are hemolytic anemia, fatigue, rash and cough. However, there have been no reports of severe cases or cases with pronounced symptoms.

CASE REPORT

A 53-year-old white man who was a former intravenous

DMIP-LIM-47, Hospital das Clínicas, Faculdade de Medicina, Universidade de São Paulo - São Paulo/SP, Brazil.
Tel.: 55 11 3085-1601
Email: evaldostanislau@uol.com.br

drug user and who had a history of stable diabetes mellitus and smoking (82 pack-years) sought treatment after having recently been diagnosed with chronic hepatitis C. A hepatic biopsy, conducted in February of 2006, revealed histological alterations consistent with cirrhosis (METAVIR fibrosis score and activity score, F4 and A3). Virological tests at baseline showed infection with genotype 3a and a viral load of 780,203 IU/mL (COBAS Amplicor®; Roche Molecular Diagnostics, Basel, Switzerland). In July of 2006, treatment with a combination of pegylated interferon alpha-2a (Pegasys®; Roche) and ribavirin (180 µg/week and 1000 mg/day, respectively) was initiated. After 12 weeks of treatment, the patient presented dyspnea on extreme exertion, with episodes of cough followed by voluminous expectoration consisting of large pieces (up to 8.0 cm in length) of mucus-like material mimicking bronchial casts (Figs. 1a and 1b). Expectoration occurred daily, mainly during the night, and was exacerbated by a cold environment. The patient did not present fever, night sweats, orthopnea or paroxysmal nocturnal dyspnea. Considering the good virological response to the treatment (HCV RNA not detected at week 12 of therapy, which is

indicative of complete early virological response (cEVR)) and the severity of the hepatic impairment, together with the willingness of the patient to continue, we opted for not interrupting the treatment. Empirically, we employed anti-inflammatory treatment with prednisone (40 mg/day). Partial improvement was obtained, and the dose was tapered to the lowest possible level that would suppress the symptoms, being increased when necessary. Therefore, there was no symptom progression, and the exacerbations were controlled. Despite the pulmonary profile and the cEVR, but given the use of high doses of prednisone, the severity of the hepatic histological lesion and the high baseline viral load, we decided to maintain the therapy with pegylated interferon alpha and ribavirin for 48 weeks. Immediately after the use of pegylated interferon and ribavirin was discontinued, there was complete remission of the respiratory complaints, and the patient remains in remission at this writing (3 years). Six months after the discontinuation of the therapy, the patient achieved an SVR.

Tests conducted for the purpose of diagnosing and evaluating pulmonary function revealed minimum alterations. A high-resolution computed tomography scan of the chest showed signs of diffuse, possibly chronic, bronchial disease, with extensive thickening of the bronchial walls (Fig. 2). Bronchoscopy revealed normal morphology up to the subsegmental bronchi. Cytology of bronchoalveolar lavage fluid revealed abundant cellularity: 95% pneumocytes/alveolar macrophages and 5% lymphocytes. Direct testing, as well as cultures for mycobacteria and fungi, yielded negative results. Double immunodiffusion and counterimmunoelectrophoresis for *Paracoccidioides brasiliensis* and *Aspergillus fumigatus* were negative. Transbronchial biopsy showed preserved

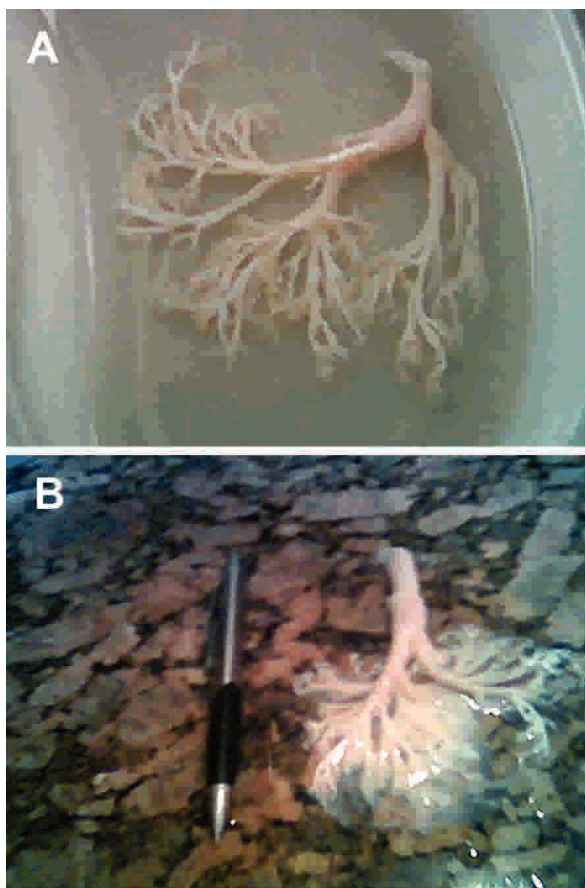


Figure 1 - Expectoration by the patient on two distinct occasions. Note the aspect that mimics a bronchial segment cast (A) and the mucoid characteristics of the material (B).

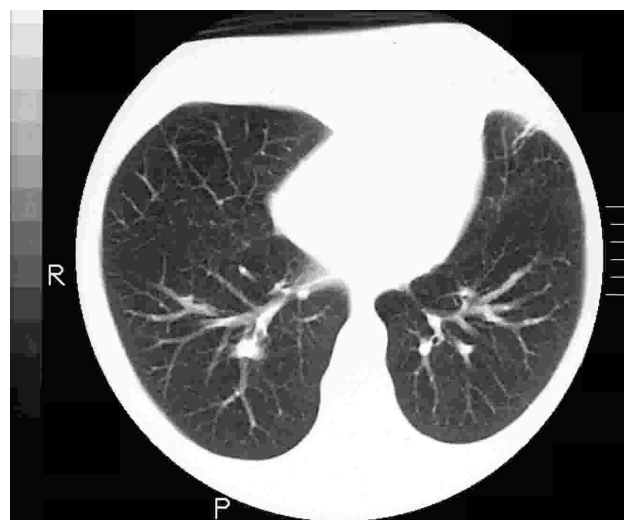


Figure 2 - Tomographic slice: signs of diffuse, possibly chronic, bronchial disease with diffuse thickening of the bronchial walls.

alveolar walls with no fibrosis or significant inflammation and few alveolar macrophages. There was no histological evidence of chronic pulmonary disease, nor were there any granulomas or signs of neoplasms (Fig. 3). Arterial blood gas analysis results revealed a PaO_2 of 79 mmHg, and the results of pulmonary function testing were within the limits of normality (FEV_1 , 83% of predicted). We concluded that there were no chronic pulmonary diseases or other associated pulmonary diagnoses that would explain the profile. Therefore, the established cause-and-effect relationship, together with the lack of factors other than the use of the pegylated interferon-ribavirin combination, brought us to the conclusion that the effects observed in this case were induced by the therapy against HCV.

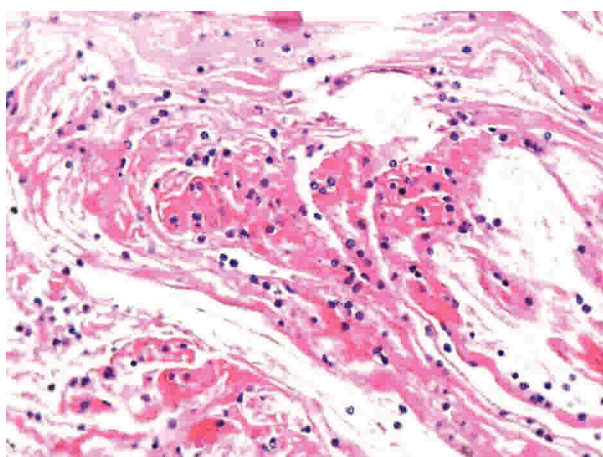


Figure 3 - Transbronchial biopsy (Hematoxylin-Eosin $\times 100$): preserved alveolar walls without fibrosis or significant inflammation having only a few alveolar macrophages. No histological evidence of chronic lung disease, granulomas or neoplasms.

DISCUSSION

Case reports that attribute pulmonary symptoms and signs to the use of interferon alpha and ribavirin have shown that these effects appear 2 to 12 weeks after the initiation of treatment. Most of the reported complaints are of fever, progressive dyspnea and cough. Radiological imaging studies detect diffuse interstitial infiltrates and opacities consistent with a ground-glass pattern. Pulmonary biopsies reveal interstitial pneumonitis, idiopathic pulmonary fibrosis, BOOP and sarcoidosis. In all the reported cases of pulmonary complications during therapy with interferon alpha (with the exception of a case of acute respiratory distress syndrome), the symptoms regressed after the discontinuation of the treatment.^{3-6,8,11}

Our patient also presented symptom onset after the twelfth week of treatment. The predominant feature was cough with abundant expectoration containing bronchial

casts. Among the hypotheses considered in the differential diagnosis were alveolar proteinosis and allergic bronchial aspergillosis. After complementary tests, such diagnoses were ruled out. Therefore, we considered the possibility of a late hypersensitivity reaction to interferon alpha, and that the reaction was restricted to the lungs, more specifically to the tracheobronchial tree, and involved the formation of mucous plugs. Some authors have stated that the process of interferon-induced exacerbation of bronchospasm symptoms is similar to that of asthma, with the formation of bronchial casts and improvement after corticosteroid therapy.

Considering that the pathogenesis of the side effects associated with pegylated interferon remains unclear, two possibilities must be considered. One is the direct toxicity of the drug to the lung, and the other is the activation of indirect toxicity mechanisms that involve immunological pathways (e.g., autoimmune pathways). Interferons inhibit suppressor T cells, alter cytotoxic T cells and induce pro-inflammatory cytokines. Interferons also cause the overproduction of fibrogenic cytokines, such as platelet-derived growth factor and transforming growth factor beta, thereby potentially inducing pulmonary fibrosis. In cases in which immunogenic mediation is the principal cause of the exacerbation of bronchospasm symptoms, there is an increase in the Th1-type lymphocytic response and a consequent increase in the production of interferon gamma and interleukin-2. We also speculated that the stimulation of other cells or cytokines triggered an inflammatory cascade. In cases of interstitial pneumonia, the mechanism remains poorly understood. The suggested treatment has been the discontinuation of interferon alpha. However, corticosteroid therapy can also suppress the symptoms.

In the case described, considering the good EVR and the severity of the hepatic impairment, together with the consent of the patient, we opted to not interrupt the hepatitis C therapy. Empirically, corticosteroid therapy was employed at the lowest effective dose and only until the symptoms were controlled to avoid any possible immune alterations driven by prednisone. As a result, there was no progression of the symptoms, and the exacerbations were controlled. Immediately after the use of pegylated interferon and ribavirin was discontinued, there was complete remission of the respiratory complaints, and the patient remains in remission at this writing. By six months after the discontinuation of the therapy, the patient achieved an SVR.

This case illustrates an unexpected pulmonary-related adverse effect associated with the use of pegylated interferon and ribavirin for the treatment of hepatitis C. Despite being rare and reversible, the potential severity of this type of adverse effect suggests that the signs and symptoms of lung disease should be carefully evaluated in patients

under treatment with pegylated interferon and ribavirin. Especially in cases involving patients with a history of chronic lung disease, asthma or relevant smoking, we recommend that the initial evaluation include at least one chest X-ray and pulmonary function tests. When facing an adverse and unexpected manifestation, one should consider the use of corticosteroid therapy to contain the exacerbated inflammatory response and allow the maintenance of the

therapy against HCV, while emphasizing that total adhesion to the established dose schedule is of extreme importance for achieving an SVR. This case and the accumulation of pulmonary-related adverse events described during therapy with the pegylated interferon-ribavirin combination underscore the need for pharmacovigilance, as well as the need to establish minimum therapeutic parameters for the appropriate management of such cases.

REFERENCES

1. Kamisako T, Adachi Y, Chihara J, Yamamoto T. Interstitial pneumonitis and interferon-alfa. *Br Med J*. 1993;306:896.
2. Midturi J, Sierra-Hoffman M, Hurley D, Winn R, Beissner R, Carpenter J. Spectrum of pulmonary toxicity associated with the use of interferon therapy for hepatitis c: case report and review of the literature. *Clin Infect Dis*. 2004;39:1724-9.
3. Abi-Nassif S, Mark EJ, Fogel RB, Hallisey RK. Pegylated interferon and ribavirin-induced interstitial pneumonitis with ARDS. *Chest*. 2003;124:406-10.
4. Kumar KS, Russo MW, Borczuk AC, Brown M, Esposito SP, Lobritto SJ, et al. Significant pulmonary toxicity associated with interferon and ribavirin therapy for hepatitis C. *Gastroenterology*. 2002;97:2432-40.
5. Bruno R, Sacchi P, Ciappina V, Zochetti C, Patruno S, Maiocchi L, et al. Viral dynamics and pharmacokinetics of peginterferon alpha-2a and peginterferon alpha-2b in naive patients with chronic hepatitis C: A randomized, controlled study. *Antivir Ther*. 2004;9:491-7.
6. Fuhrmann V, Kramer L, Bauer E, Laferl H, Tucek G, Dekan G, et al. Severe interstitial pneumonitis secondary to pegylated interferon α -2b and ribavirin treatment of hepatitis c infection. *Dig Dis Sci*. 2004;49:1966-70.
7. Manns MP, McHutchison JG, Gordon SC, Rustgi VK, Shiffman M, Reindollar R, et al. International Hepatitis Interventional Therapy Group: Peginterferon alfa-2b plus ribavirin compared with interferon alfa-2b plus ribavirin for initial treatment of chronic hepatitis C: A randomised trial. *Lancet*. 2001;358:958-65.
8. Ogata K, Koga T, Yagawa K. Interferon-related bronchiolitis obliterans organizing pneumonia. *Chest*. 1994;994:612-3.
9. Fuhrmann V, Kramer L, Bauer E, Laferl H, Tucek G, Dekan G, et al. Severe interstitial pneumonitis secondary to pegylated interferon α -2b and ribavirin treatment of hepatitis C infection. *Dig Dis Sci*. 2004;49:1966-70.
10. Lauer GM, Walker BD. Hepatitis C virus infection. *N Engl J Med*. 2001;345:41-52.
11. Chin K, Tabata C, Sataka N, Nagai S, Moriyasu F, Kuno K. Pneumonitis associated with natural and recombinant interferon alfa therapy for chronic hepatitis C. *Chest*. 1994;105:939-41.
12. Feld JJ, Nanda S, Huang Y, Chen W, Cam M, Pusek SN, et al. Hepatic gene expression during treatment with Peginterferon and ribavirin: identifying molecular pathways for treatment response. *Hepatology*. 2007;46:1548-63.