



Actas Urológicas Españolas

www.elsevier.es/actasuro



CASUISTRY

Delayed bleeding after partial nephrectomy. Management with selective embolization[☆]

A. Ciudin^{*}, J. Huguet, A. García-Larrosa, M. Musquera, J.R. Alvarez-Vijande, M. José Ribal, A. Alcaraz

Servicio de Urología, Instituto Clínico de Nefrología y Urología, Hospital Clínic, Barcelona, Spain

KEYWORDS

Partial nephrectomy;
Pseudoaneurysm;
Renal hemorrhage;
Selective vascular
embolization

Abstract

Introduction: Bleeding after partial nephrectomy can be immediate or delayed and may have severe consequences. The incidence of this complication is low. The most frequent cause of delayed bleeding is arterial pseudoaneurysm. Superselective embolization is a feasible therapeutic option that has shown good results.

Objective: To evaluate treatment and outcomes of delayed bleeding in our series of patients with partial nephrectomy.

Material and methods: We performed a retrospective study of our database of partial nephrectomies. Patients who developed delayed bleeding (after discharge) were identified. Clinical histories were reviewed and data on presentation, diagnosis, treatment and outcomes were analyzed.

Results: Among our series of patients undergoing partial nephrectomy, three developed delayed bleeding (1.3%). Symptom onset occurred 17–25 days after surgery and consisted of hematuria or lumbar pain. Diagnosis was provided through ultrasound, abdominal computed tomography and renal angiography. In all three patients, a complicated pseudoaneurysm was diagnosed and all patients underwent renal artery catheterization with selective renal artery embolization. In all patients, immediate control of bleeding was achieved. Outcome after a follow-up of 61–92 months was favorable.

Conclusions: Selective vascular embolization is the treatment of choice of renal pseudoaneurysm after partial nephrectomy in hemodynamically stable patients.

© 2011 AEU. Published by Elsevier España, S.L. All rights reserved.

[☆] Please cite this article as: Ciudin A, et al. Sangrado diferido después de nefrectomía parcial. Manejo mediante embolización selectiva. Actas Urol Esp. 2011;35:615–619.

^{*} Corresponding author.

E-mail address: alexciudin@yahoo.com (A. Ciudin).

PALABRAS CLAVE

Nefrectomía parcial;
Pseudoaneurisma;
Hemorragia renal;
Embolización
vascular selectiva

Sangrado diferido después de nefrectomía parcial. Manejo mediante embolización selectiva

Resumen

Introducción: El sangrado después de una nefrectomía parcial es una complicación con posibles consecuencias graves. Puede ser inmediato o diferido y su incidencia es baja. La causa más frecuente del sangrado diferido es el pseudoaneurisma arterial. La embolización supraseductiva vascular es una opción terapéutica posible que ha demostrado buenos resultados.

Objetivo: Evaluar la evolución y el tratamiento del sangrado diferido en nuestra serie de pacientes con nefrectomías parciales.

Material y métodos: Realizamos un estudio retrospectivo de nuestra base de datos de nefrectomías parciales. Identificamos los pacientes que presentaron sangrado diferido (después del alta). Se revisó la historia clínica, analizando datos sobre la presentación, el diagnóstico, el tratamiento y la evolución de los pacientes.

Resultados: De nuestra serie de nefrectomías parciales tres pacientes presentaron sangrado diferido (1,3%). La clínica se inició después de 17 a 25 días de la cirugía por la aparición de hematuria o dolor lumbar. El diagnóstico se realizó mediante ecografía, TAC abdominal y angiografía renal. En todos los pacientes se diagnosticó un pseudoaneurisma arterial complicado, siendo sometidos a cateterismo arterial renal con embolización selectiva del mismo. La evolución fue correcta en todos los pacientes con control inmediato del sangrado. Documentamos un seguimiento posterior favorable de 61 a 92 meses.

Conclusiones: La embolización selectiva vascular es el tratamiento de elección del pseudoaneurisma renal sintomático después de nefrectomía parcial en el paciente hemodinámicamente estable.

© 2011 AEU. Publicado por Elsevier España, S.L. Todos los derechos reservados.

Introduction

Partial nephrectomy (PN) is the technique of choice in the treatment of renal tumors in clinical stage T1a (≤ 4 cm), and also in selected cases in stage T1b.^{1,2} Currently, laparoscopic PN is considered a good alternative to open surgery, showing the same oncological results in some long series, reducing the morbidity and complications of the surgical wound.³

The complications of PN have been extensively described in the literature. Postoperative hemorrhage is a complication with potentially serious consequences. It is estimated that, including immediate and delayed bleeding, its incidence is between 4 and 6% after laparoscopic PN, and about 1.6% after open PN.^{3,4} There are few studies focusing on the diagnosis and performance for delayed bleeding, the one that occurs after the patient's discharge. In this work, we analyze the patients in our PN series who had delayed bleeding.

Material and methods

We performed the retrospective study of the clinical histories of the patients in our PN database who had a delayed bleeding as a postoperative complication. We defined delayed bleeding as the one occurred after discharge. We analyzed its presentation, diagnosis, treatment, and evolution.

Results

Between 1992 and December 2009, 230 PN were performed at our center. In 136 cases (59.1%), we used the open

approach, and in 94 (40.8%), the laparoscopic one. We identified three patients (1.3%), all male, who had a delayed bleeding after PN. All had undergone, without incidents, a PN for tumors between 2 and 3.5 cm (Table 1).

They came to casualty with hematuria or lumbar pain between 17 and 25 days after surgery, all requiring blood transfusion (Table 2). The diagnosis was made by abdominal ultrasound and/or computed tomography (CT). Given the clinical and radiological suspicion of the existence of active bleeding, a selective arteriography was performed on the three patients. In all of them, the bleeding was attributed to the presence of an aneurysmal dilation at the level of an arterial branch (Figs. 1 and 2). Superselective embolization of the arterial branch got the immediate control of the bleeding in all the patients.

Discussion

Delayed bleeding after PN is rare, and it is usually attributed to the presence of artery pseudoaneurysms (AP).⁵ The incidence of symptomatic AP is over 0.43% after open PN,⁶ and 1.7–7.5% after laparoscopic PN.^{7,8} However, we consider that most of the AP do not get to produce clinical manifestations, so it is estimated that their real incidence is much higher.⁹ AP related to closed or penetrating renal trauma, extracorporeal lithotripsy, after placement of nephrostomy, and percutaneous nephrolithotomy^{10–15} have been reported. In the international literature so far, less than 30 AP have been reported.¹⁶

The appearance of AP after PN is attributed to the persistence in the surgical site of arterial vessels, partially or completely open not fully sutured during the intervention.^{9,17,18} This would create an intraparenchymal

Table 1 Characteristics of the patients undergoing partial nephrectomy and having delayed bleeding.

	Age and sex	Tumor		Surgery		Pathological anatomy	Discharge
		Size	Location	Type	Bleeding		
Patient 1	49 ♂	29 mm	Upper pole, peripheral	Open	250 ml	pT1a Fuhrmann 2 CCC	7 days
Patient 2	57 ♂	35 mm	Mesorenal, central	Open	400 ml	pT1a Fuhrmann 2 CCC	7 days
Patient 3	65 ♂	20 mm	Upper pole, peripheral	LPS	320 ml	pT1a cromophobe carcinoma	4 days

CCC: clear cell carcinoma; LPS: laparoscopy.

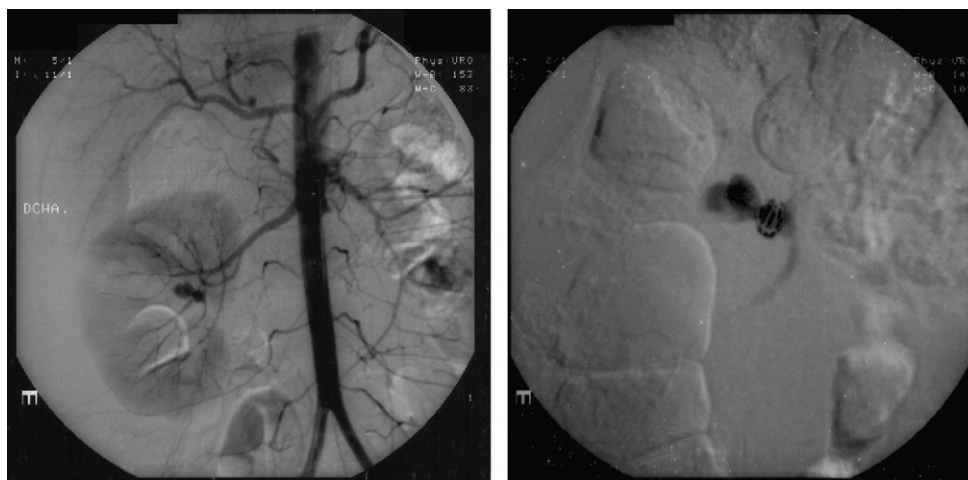
Table 2 Presentation, diagnosis, and treatment of patients with delayed bleeding after partial nephrectomy.

P	Symptoms and transfusion	Time after SI	Diagnosis			Hospital stay	Follow-up
			Ultrasound	TC	Angiography		
1	Lumbar pain, hematuria, 3 PRBC	23 days	Doppler signal cystic image	No	25 mm × 11 mm RAP; 4th order artery; 2 coil embolization	4 days	82 months
2	Lumbar pain, 2 PRBC	25 days	Unclear image	Active arterial bleeding, RAP	23 mm × 20 mm RAP; 3rd order artery; 2 coil embolization	5 days	92 months
3	Hematuria, 2 PRBC	17 days	Doppler signal cystic image	Active arterial bleeding, RAP	15 mm × 11 mm RAP; 3rd order artery; 1 coil embolization	4 days	61 months

PRBC: packed red blood cells; P: patient; RAP: renal artery pseudoaneurysm.

hemorrhage, which is initially contained by the vascular adventitia, renal parenchyma and Gerota's fascia, being able to develop even a fibrous capsule.¹⁰ Finally, bleeding originates coinciding with the increased activity of the patient, of their blood pressure, or due to migration of an arterial suture.^{9,18} Higher incidence of pseudoaneurysms after laparoscopic PN (1.7%) than after an open procedure (0.43%) is explained in some series by the occlusive effect of the pneumoperitoneum on bleeding points, and the lowest possible tension that

can be applied to hemostatic sutures.⁹ The intraoperative use of hemostatic products appears not to decrease the likelihood of AP onset.^{5,19} Most of the arteries involved in this type of injuries are third or fourth order.^{9,11,20} Bleeding due to AP can progress to the retroperitoneal space or the collecting system, determining the appearance of a retroperitoneal hematoma or hematuria.⁶ Abdominal or lumbar pain and hemodynamic instability may occur.^{6,20} Most bleedings described in the literature appear between the second and the fourth week

**Figure 1** (A) Central pseudoaneurysm, depending on a third-order branch. (B) Image with the embolized pseudoaneurysm with two coils.

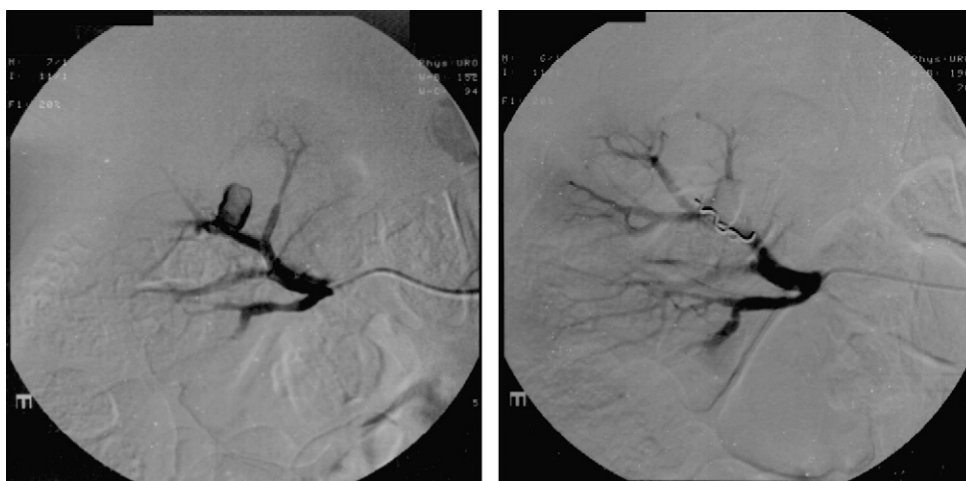


Figure 2 Pseudoaneurysm before (A) and after (B) coil embolization.

after the surgery.^{5,9,17,18} However, there are cases that have manifested clinically from 3 to 5 months after the intervention.⁶

The initial diagnostic test of choice for the diagnostic suspicion of a delayed bleeding after PN is CT with intravenous contrast. The CT helps (in cases with non-specific clinical manifestations) to set the cause of the process as urological, to identify active bleeding, and to describe the morphology of the AP.^{11,17,21} Diagnostic confirmation is made by renal arteriography. The involved artery catheterization allows for the performance of the diagnosis and the treatment of the AP in the same event. Superselective embolization has been consolidating for years as the treatment of choice for delayed bleeding after PN, most of the patients showing satisfactory results. The control of the bleeding is achieved, as well, preserving most of the renal parenchyma practicable.^{22,23} In our series, endovascular treatment was effective in the three cases. Conservative management is accepted as a potential initial treatment; however, most of the published cases with initial conservative management required further angiographic treatment for persistence or worsening of the symptoms.^{5,6,17,18}

The attitude toward the accidental diagnosis of an AP during the follow-up of a patient undergoing PN is usually expectant.⁶ The location next to the pyelocaliceal system, a clear growth in the subsequent imaging, and associated anticoagulant or antiplatelet therapy are risk factors that can make opt for interventionist actions for an asymptomatic AP. There is no consensus on the size from which the asymptomatic AP is at increased risk of bleeding and should be treated.

Conclusions

Selective vascular embolization is the treatment of choice for symptomatic renal pseudoaneurysm after partial nephrectomy in the hemodynamically stable patient, showing good long-term evolution.

Conflict of interest

The authors declare that they have no conflict of interest.

References

1. Ljungberg B, Cowan NC, Hanbury DC, Hora M, Kuczyk MA, Merseburger AS, et al. EAU guidelines on renal cell carcinoma: the 2010 update. *Eur Urol*. 2010;58:398–406.
2. Peycelon M, Hupertan V, Comperat E, Renard-Penna R, Vaessen C, Conort P, et al. Long-term outcomes after nephron sparing surgery for renal cell carcinoma larger than 4 cm. *J Urol*. 2009;181:35–41.
3. Gill IS, Kavoussi LR, Lane BR, Blute ML, Babineau D, Colombo Jr JR, et al. Comparison of 1,800 laparoscopic and open partial nephrectomies for single renal tumors. *J Urol*. 2007;178:41–6.
4. Ramani AP, Desai MM, Steinberg AP, Ng CS, Abreu SC, Kaouk JH, et al. Complications of laparoscopic partial nephrectomy in 200 cases. *J Urol*. 2005;173:42–7.
5. Montag S, Rais-Bahrami S, Seideman CA, Rastinehad AR, Vira MA, Kavoussi LR, et al. Delayed haemorrhage after laparoscopic partial nephrectomy: frequency and angiographic findings. *BJU Int*. 2011;107:1460–6.
6. Albani JM, Novick AC. Renal artery pseudoaneurysm after partial nephrectomy: three case reports and a literature review. *Urology*. 2003;62:227–31.
7. Inci K, Cil B, Yazici S, Peynircioglu B, Tan B, Sahin A, et al. Renal artery pseudoaneurysm: complication of minimally invasive kidney surgery. *J Endourol*. 2010;24:149–54.
8. Nadu A, Kleinmann N, Laufer M, Dotan Z, Winkler H, Ramon J. Laparoscopic partial nephrectomy for central tumors: analysis of perioperative outcomes and complications. *J Urol*. 2009;181:42–7.
9. Singh D, Gill IS. Renal artery pseudoaneurysm following laparoscopic partial nephrectomy. *J Urol*. 2005;174:2256–9.
10. Saad DF, Gow KW, Redd D, Rausbaum G, Wulkan ML. Renal artery pseudoaneurysm secondary to blunt trauma treated with micro-coil embolization. *J Pediatr Surg*. 2005;40:e65–7.
11. Cura M, Elmerhi F, Bugnogne A, Palacios R, Suri R, Dal-saso T. Renal aneurysms and pseudoaneurysms. *Clin Imaging*. 2011;35:29–41.

12. Miller DC, Forauer A, Faerber GJ. Successful angioembolization of renal artery pseudoaneurysms after blunt abdominal trauma. *Urology*. 2002;59:444.
13. Rudnick DM, Dretler SP. Intrarenal pseudoaneurysm following ureterorenoscopy and electrohydraulic lithotripsy. *J Urol*. 1998;159:1290-1.
14. Kessaris DN, Bellman GC, Pardalidis NP, Smith AG. Management of hemorrhage after percutaneous renal surgery. *J Urol*. 1995;153:604-8.
15. Richstone L, Reggio E, Ost MC, Seideman C, Fossett LK, Okeke Z, et al. Hemorrhage following percutaneous renal surgery: characterization of angiographic findings. *J Endourol*. 2008;22:1129-35.
16. Povo-Martin IJ, Gallego-Vilar D, Rodrigo-Aliaga M, Garcia-Vila J. Renal artery pseudoaneurysm after partial nephrectomy. Diagnosis, treatment and literature review. *Actas Urol Esp*. 2010;34:647-51.
17. Wright JL, Porter JR. Renal artery pseudoaneurysm after laparoscopic partial nephrectomy. *Urology*. 2005;66:1109.
18. Negoro H, Kawakita M, Koda Y. Renal artery pseudoaneurysm after laparoscopic partial nephrectomy for renal cell carcinoma in a solitary kidney. *Int J Urol*. 2005;12:683-5.
19. Gill IS, Ramani AP, Spaliviero M, Xu M, Finelli A, Kaouk JH, et al. Improved hemostasis during laparoscopic partial nephrectomy using gelatin matrix thrombin sealant. *Urology*. 2005;65:463-6.
20. Zorn KC, Starks CL, Gofrit ON, Orvieto MA, Shalhav AL. Embolization of renal-artery pseudoaneurysm after laparoscopic partial nephrectomy for angiomyolipoma: case report and literature review. *J Endourol*. 2007;21:763-8.
21. Cohenpour M, Strauss S, Gottlieb P, Peer A, Rimon U, Stav K, et al. Pseudoaneurysm of the renal artery following partial nephrectomy: imaging findings and coil embolization. *Clin Radiol*. 2007;62:1104-9.
22. Schwartz MJ, Smith EB, Trost DW, Vaughan Jr ED. Renal artery embolization: clinical indications and experience from over 100 cases. *BJU Int*. 2007;99:881-6.
23. Mohsen T, El-Assmy A, el-Diasty T. Long-term functional and morphological effects of transcatheter arterial embolization of traumatic renal vascular injury. *BJU Int*. 2008;101:473-7.