

Actas Urológicas Españolas

www.elsevier.es/actasuro



Review – Voiding dysfunction

Update on pudendal nerve entrapment syndrome: an approach anatomic-surgical, diagnostic and therapeutic

F. Itza Santos^{a,*}, J. Salinas^b, D. Zarza^c, F. Gómez Sancha^d, and A. Allona Almagro^e

^aPain Unit, Clínica del Dolor, Madrid, Spain

^bUrology Service, Hospital Clínico San Carlos, Madrid, Spain

^cNeurophysiology Service, Hospital NISA Pardo de Aravaca, A Coruña, Spain

^dUrology Service, Clínica del Rosario, Madrid, Spain

^eUrology Service, Rúber Internacional, Madrid, Spain

ARTICLE INFORMATION

Article history:

Received 21 February, 2010

Accepted 11 March, 2010

Keywords:

Pudendal nerve (PN)

Pudendal nerve entrapment syndrome (PNES)

Pelvic floor neuropathic pain

Pelvic floor myofascial syndrome

Pudendal nerve decompression

ABSTRACT

Introduction: The syndrome of pudendal nerve entrapment (PNES) is widely unknown and often misdiagnosed or confused with other diseases. It was first described by Amarencio in 1987. The classic clinical manifestation is pudendal neuralgia, a neuropathic pain in the genital area.

Objectives: To make known its existence to the urology professionals through a systematic review of existing literature and its potential for diagnosis and treatment.

Materials and methods: We performed a literature search through the database “Pubmed” using the terms “Pudendal nerve”, “Pudendal nerve entrapment syndrome,” “Pelvic floor neuropathic pain”, “Pelvic floor myofascial syndrome,” “Pudendal nerve decompression”. Also, selected works in English, Spanish and French, also reviewing the articles relate this work.

Results: We develop the highlights of the syndrome: anatomy, etiology, pathophysiology, clinical diagnosis, ecodoppler of internal pudendal artery, electrophysiological studies, diagnostic criteria, medical therapy, physical therapy treatments and surgery.

Conclusion: It is an uncommon cause of pain in the pelvic floor and greatly affects quality of life of patients. Today, we have diagnostic and therapeutic tools that allow us to treat this disabling syndrome with good results.

© 2010 AEU. Published by Elsevier España, S.L. All rights reserved.

*Author for correspondence.

E-mail: fitza@arrakis.es (F. Itza Santos).

Actualización del síndrome de atrapamiento del nervio pudendo: enfoque anatómico-quirúrgico, diagnóstico y terapéutico

R E S U M E N

Palabras clave:

Nervio pudendo (NP)

Atrapamiento del nervio pudendo (SANP)

Dolor neuropático del suelo pélvico
Síndrome miofascial de suelo
pélvico

Descompresión del nervio pudendo

Introducción: El síndrome de atrapamiento del nervio pudendo (SANP) es un gran desconocido y suele ser mal diagnosticado o confundido con otras patologías. Fue descrito por primera vez por Amarenco en 1987. La manifestación clínica clásica es la neuralgia del pudendo, un dolor neuropático del área genital.

Objetivos: Dar a conocer su existencia a los profesionales de la urología a través de una revisión sistemática de la bibliografía existente y sus posibilidades de diagnóstico y tratamiento.

Material y método: Realizamos una búsqueda bibliográfica a través de la base de datos «Pubmed» utilizando los términos «Pudendal nerve», «Pudendal nerve entrapment syndrome», «Pelvic floor neuropathic pain», «Pelvic floor myofascial syndrome», «Pudendal nerve decompression». Asimismo, seleccionamos los trabajos en lengua inglesa, española y francesa, revisando también los artículos que dichos trabajos refieren.

Resultados: Se desarrollan los aspectos más destacados del síndrome: anatomía, etiología, fisiopatología, diagnóstico clínico, ecodoppler de la arteria pudenda interna, estudios electrofisiológicos, criterios diagnósticos, terapéutica médica, tratamiento con fisioterapia y tratamiento quirúrgico.

Conclusión: Es una causa poco frecuente de dolor en el suelo pélvico y afecta en gran medida la calidad de vida de los pacientes. Hoy, disponemos de herramientas diagnósticas y terapéuticas que nos permiten tratar este síndrome invalidante con buenos resultados.

© 2010 AEU. Publicado por Elsevier España, S.L. Todos los derechos reservados.

Introduction

Pudendal nerve entrapment syndrome (PNES) was first described in 1987 by the neurologist Dr. Amarenco after a cyclist visited his office complaining of neuralgia in the pudendal nerve territory. He used several electrophysiologic tests to define the disorder. He first called it perineal paralysis of cyclists¹.

Shortly afterwards, in 1991, Dr. Shafik described a technique to decompress the pudendal nerve. The procedure is simple and ambulatory, and takes 5-10 minutes in expert hands; there are no complications except for infection, small hematomas and postoperative pain².

The main complaint leading to the doctor's visit is pain in the anal and perineal areas that characteristically appears when sitting, is alleviated when standing, and disappears when lying down. It has neuropathic features such as hypoesthesia, numbness, perianal tingling, and even intense shooting pain³.

In a retrospective study, Benson points out that this is a condition that few professionals consider. Thus, patients visit many practitioners before they are correctly diagnosed. Sometimes the neurophysiologic findings are within normal limits, which makes the problem even more difficult⁴.

There are many similarities between PNES and pelvic floor myofascial pain syndrome. Sometimes the two conditions coexist, and sometimes one leads to the other; there may be an overlap of the characteristic pain, or one type of pain may be more intense than others; all this makes diagnosis and subsequent treatment difficult⁵.

Few epidemiologic data are found in literature.

The mean time to diagnosis is 4 years, with a range of 1-15 years. The number of physicians consulted before diagnosis ranges between 10 and 30. Gender is relevant, as the condition affects more women than men: seven out of ten patients are women.

The actual incidence is unknown.

Objectives: To make urologists aware of this condition through a systematic literature review, including the diagnostic and therapeutic options.

Material and method: We conducted a bibliographic search in the Pubmed database for the terms "Pudendal nerve", "Pudendal nerve entrapment syndrome", "Pelvic floor neuropathic pain", "Pelvic floor myofascial syndrome", and "Pudendal nerve decompression". We selected articles in English, Spanish, and French, and reviewed the articles referenced therein. We finally selected the studies that best define the profile of PNES, and discarded subsequent manuscripts by the same authors and articles that did not add relevance to the topic.

Pathophysiology of nerve entrapment

Three main factors in the development of a nervous system condition can be identified: vascular, ionic, and mechanic. There is disagreement as to which factor is more important, especially in the early stages of compression; however, it is currently thought that the vascular factors predominate²³.

To function normally, nerve fibers depend on an uninterrupted blood supply. There is a series of pressure gradients in the nerve and surrounding tissues and fluids. The importance of this pressure gradient in the development of entrapment neuropathy is a fact²⁴.

Sunderland detailed three progressive stages caused by higher pressures in the entrapped zone: hypoxia, edema, and fibrosis²³. Nerve metabolism is weakened due to venous stasis and hypoxia. Nerve ischemia is a source of pain and other symptoms like paresthesia. With continuous hypoxia, the lesion in the capillary endothelium results in extravasation and protein-rich edema.

Nerve ischemia translates into blocked nerve transmission. There are three causes for this:

- excessive traction,
- minimal traction in areas with adhesions, and
- mechanical compression.

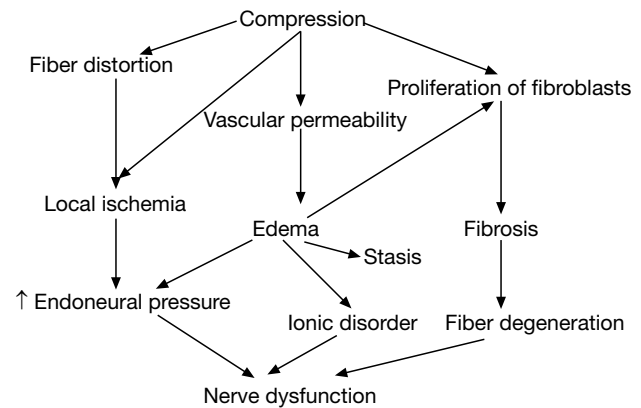
These abnormalities develop as follows:

- obstructed venous obstruction causing congestion or venous stasis,
- direct anoxic lesion that increases permeability, and
- edema in the endoneural tissue with increased pressure in the intrafascicular space, which augments the effects of the original compression.

If compression increases or the edema persists for a long period of time, there is a proliferation of fibroblasts within the nerve, with a prior demyelization process in place. If the cause persists, fibrosis can cause anoxia in nerve segments, as circulation and the exchange between the vascular plexus and the nerve fibers are impaired. When a part of the axon is ischemic, just a 30-50% decrease in blood flow results in a decreased oxidative phosphorylation and ATP production, which decreases the efficacy of the Na pump, the axoplasmic transport system, and the integrity of the cell membrane, resulting in a decrease or loss of transmission through the nerve fiber.

Nutrients are provided by two anterograde axoplasmic transport mechanisms, and catabolites are collected by a retrograde axoplasmic transport mechanism. An interruption in synthesis or abnormalities in transport in either direction seems to account for the phenomenon of double or multiple compression ("double-crash"), which means that a nerve with conduction abnormalities at one level is more likely to experience a conduction disorder in a second or third location: Initially it was observed that proximal neural pathologies predispose to distal disorders; it has become clear that primary distal abnormalities also favor the development of proximal disorders²⁴.

General outline. Pathophysiology of nerve entrapment.



Clinical diagnosis of entrapment

History

- Pelvic pain when sitting; it may be less intense in the morning and increase throughout the day. Symptoms may decrease when standing or lying down. Pain may be perineal, rectal, or in the area of the clitoris or penis; it can be unilateral or bilateral.
- Sexual dysfunction. In women and men it manifests as pain or decreased sensitivity in the genitals, perineum, or rectum (**hypoesthesia**). Pain can occur with or without friction. It may cause anorgasmia. In men the dysfunction takes the form of painful erections, difficulty in maintaining erections, or pain during or after ejaculation.
- Urination/defecation difficulty. Patients may experience urinary frequency and urgency. Postvoid discomfort. Bowel movements may be painful. Pain after defecation. Constipation is common. Sensation of a golf ball in the rectum. There may be varying degrees of urinary and fecal incontinence.
- On the other hand, the condition may resemble chronic prostatitis, prostatodynia, or interstitial cystitis.
- We now know that the most common cause of the old concept of prostatodynia is myofascial pelvic dysfunction. According to Shafik, this is a condition characterized by persistent perineal pain accompanied by urinary frequency, urgency, dysuria, and urinary flow disorders. In his article, the author proposes decompression of the PN²⁵.

Presentation

For simplification purposes, the following presentations can be observed from the clinical and practical point of view.

- Pain only.
- Pain and urinary symptoms.
- Pain and defecation problems.
- Pain and erectile and ejaculatory dysfunction.
- Any combination of the above.
- Functional disorders without pain.

Shafik reports two series of patients without pain but with erectile dysfunction and penile, perineal and scrotal hypoesthesia or anesthesia. Bulbocavernosus and pudendal nerve terminal motor latencies (PNTML) were prolonged. Decompression of the PN was effective to treat ED and the accompanying symptomatology. It has been suggested also that the most likely cause in this case is chronic constipation leading to subluxation of the levator ani muscle with subsequent compression of the PN in the pudendal canal²⁶.

Loeser, a pain expert, points out that entrapment neuropathies cause focal neurologic deficit, local and irradiated pain, and paresthesia. All three components may or may not be present. For this reason, there may be no correlation between the clinical and the electrophysiologic findings²⁷.

Physical examination

- Tender, contractured, shortened muscles with trigger points, taut bands, and increased tone are usually found.
- The pudendal canal exit is tender upon palpation. Beco et al used a scale to determine whether the pain elicited by palpating the canal is significant or not; they defined pain as significant if it was moderate-severe with Tinel's sign (reproduction of pain and paresthesia by pressing the nerve trunk)²⁸.
- The skin rolling test is often positive; it consists of pinching and rolling the skin and subcutaneous tissue from the anus toward the pubis over the branches of the pudendal nerve. This maneuver reproduces the pain in the innervated area.
- There is decreased sensitivity in the perineal and anal regions²⁸.

Doppler ultrasonography of the pelvic and perineal vessels

This diagnostic method is innovative, not invasive, easy to perform, and not too uncomfortable for the patient. Mollo et al published an interesting study comparing the efficacy of intracavitary Doppler ultrasound and the traditional electromyographic and electroneurographic tests, diagnostic criteria and surgical outcomes²⁹.

Electrophysiologic tests

Those who wish to clearly understand the neurophysiology of the pelvic floor are directed to a Spanish study conducted by Dr. Hernández-Hidalgo³².

Additionally, it must be understood that the neurophysiologic assessment of the pudendal nerve includes motor, sensory, and vegetative nerves; thus, techniques are intended for observing the condition of this pathway from the functional point of view, and learning the extension and severity of the nerve damage; for this purpose, specific tests are done for each of the aspects examined³⁰:

• Motor pathway study (pudendal nerve distal motor latency).

This is a motor nerve conduction test. It does not assess the extent of the lesion. A specific electrode was developed at St. Mark's London Hospital (Drs. Kiff and Swash)³¹ to measure conduction time. It measures the time it takes for an electric stimulus to travel from a distal portion of the pudendal nerve to the external anal sphincter. It is a system consisting of a bipolar stimulator on the distal end of a gloved index finger and two register electrodes located at approximately 3 cm. The stimulator is directed through the rectum toward the ischial spine, and the register electrode is placed in the external anal sphincter. The normal latency observed with this method is 2 msec (fig. 2).

• Somatic sensory pathway assessment.

- **Sensory thresholds:** Using an increasing electrical stimulation on the dorsal nerve of the penis or the clitoris, the perception and pain thresholds are determined and compared to those of normal subjects.
- **Evoked sensory potentials of the pudendal nerve:** Assessment of the peripheral and spinal sensory pathway. Measures the time for an electrical stimulus to travel through the peripheral nerve, the posterior roots of the spinal cord until a brain parietal response is detected; in normal subjects this period is approximately 40 msec (fig. 3).

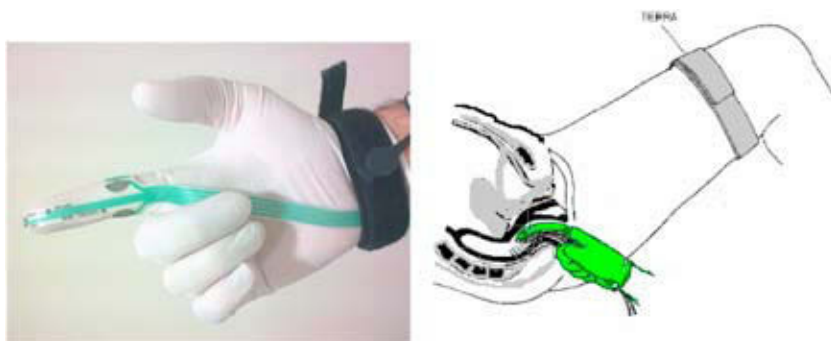

Figure 2 – St. Mark's glove electrode and its anal insertion.

- **Autonomic pathway assessment** (sympathetic skin response).
 - The sympathetic efferent path is assessed by stimulating skin reflexes and comparing the response in the hand and genitals with the sympathetic skin response (SSR); it measures the sudomotor reflex activity as a transient change in the electric potential of the skin (fig. 4).
- **Electromyography of PN-dependent muscles** (bulbocavernosus, external anal sphincter...).
By analyzing the activity of the muscle at rest and during voluntary activity, this technique determines whether there is denervation in the structure in question, and establishes whether this event is active or has become chronic. By studying various muscle groups, the topography of the lesion can be studied and a precise diagnosis made.

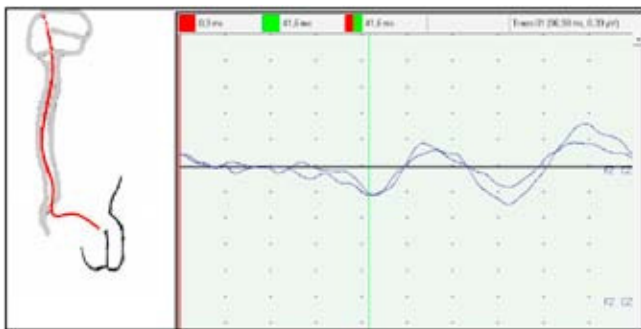


Figure 3 – Sensory evoked potentials of the pudendal nerve.




Figure 4 – Sympathetic skin response.

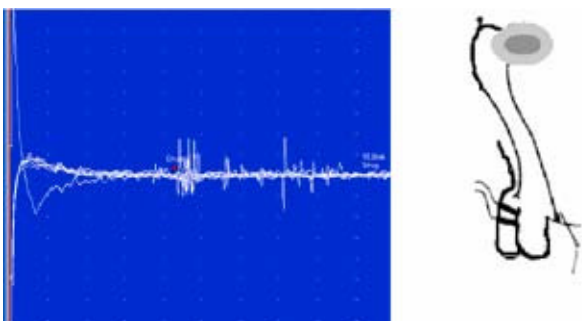


Figure 5 – Sacral reflex. All the figures, illustrations, photographs, and the table and diagram are our own; we authorize the journal to publish them.

• Sacral reflexes

This technique measures the time it takes to trigger a contraction of the bulbocavernosus muscle after electric stimulation of the dorsal nerve of the penis or clitoris. This technique permits the assessment of the motor and sensory fibers of the pudendal nerve, and the spinal roots and segments between S2 and S4. In normal subjects this reflex arc takes 30 to 40 min (fig. 5).

At the clinical research level, Bisschop described other sacral reflexes that help to delimit the exact site of entrapment³⁰.

Diagnostic criteria

A description and definition of the diagnostic criteria for a given pathology allows the physician a better approach to the problem.

This system has traditionally been used to enhance the understanding, teaching, diagnosis, and possible treatment of complex syndromes. PNES is no exception, and the following are the criteria¹¹. However, these criteria should be validated and approved by consensus at an ad hoc international conference.

1. major criterion + 2 minor criteria.
2. major criteria.

• Major criteria

1. Tender area at the end of the pudendal nerve.
2. Pain can be reproduced by pressing the trunk of the pudendal nerve (Tinel's sign equivalent).
3. Improvement for at least 12 hours after injection of lidocaine in specific anatomical sites on the trajectory of the pudendal nerve.

• Minor criteria

1. Neuropathic pain.
2. Existence of a painful and/or antalgic position (aggravated when sitting, improved when lying down).
3. Existence of an etiologic factor: trauma, surgery, labor, fall, sports, etc.
4. Absence of other causes for pelvic pain
 - Endometriosis.
 - Uterine myomas.
 - Uterine fibroma.

Treatment

As for any pathological condition, treatment should be sequential, starting with the least aggressive measures.

Medical treatment

- **Somatic pain treatment.** Several different drugs have been used with various degrees of response and efficacy for neuropathic pain, the main symptom. The most commonly used are antidepressants including amitriptyline, and the newer anticonvulsants gabapentin or pregabalin. Topical local anesthetics such as 5% lidocaine gel are also used³³.

Amitriptyline is the drug of first choice, as it has been used the most and has yielded better outcomes. For a long time these drugs have been considered the first choice of treatment for neuropathic pain. Pain alleviation seems to be the result of the inhibition of norepinephrine and serotonin uptake at the presynaptic terminals, which activates the inhibitory systems of endogenous pain in the brain that modulate the transmission of pain to the spinal cord cells.

Benzodiazepines are used to treat myofascial pain and PNES. The most useful is clonazepam.

Treatment is started with 0.25 mg/d and increased 0.25 mg/week up to a maximum of 5-20 mg/d. Treatment should not be considered ineffective until after four weeks. In a 60-day study of clonazepam for temporomandibular cervical disorder (myofascial syndrome), the assessment at 30 days showed a significant reduction in pain with the use of the anticonvulsant compared to placebo (Harkins, 1991)³⁴. In any case, the response to this type of conservative treatment is mild to moderate. A recent publication shows that gabapentin may induce a significant improvement alone or associated with amitriptyline³⁵.

- **Corticosteroid infiltration.** Perineural infiltration with corticosteroids and lidocaine/bupivacaine in the interligament space and in the pudendal canal under fluoroscopic or CT guidance³⁶ significantly improves symptoms, relaxes hypertonic sphincters, suppresses bladder symptoms, and normalizes sexual dysfunction. The effect lasts from several hours to weeks, and in some patients it is even curative. Symptomatic relief depends on the accuracy of the infiltration, given the highly variable anatomy. Sensory, motor, and autonomic improvement is variable. Infiltrations are given every 4-6 weeks, with a maximum of 3 infiltrations. If there is no adequate response, the possibility of doing a surgical decompression should be assessed³².
- **Physical therapy.** A prolonged contracture with the resulting muscular shortening leads to a lesion of the vascular-nervous bundle. The degree of lesion and entrapment depends on several factors already discussed. Stretching of the muscles in the pelvic floor by specialized physical therapists can yield surprisingly good outcomes. Improvement is not centered only in pain, and there is relief of other symptoms such as urinary frequency, erectile dysfunction, quality of life, libido, sensation of a golf ball in the rectum, etc.³⁷
- **Dry needling or local lidocaine infiltrations.** The following techniques can be used to release trigger points in the affected muscles of the pelvic floor and alleviate symptoms. Desensitization of the peripheral and central nervous system seems to be one of the bases for this effect³⁸.

Surgical treatment

The objective is to decompress the pudendal nerve. During surgery the following can be found³⁹:

- Hypertrophic ligaments, often with sharp edges and protuberances.
- Fused ligaments (funicular). Ligament bands passing through the nerve.
- Adhesions. Joining and compression against the sacrotuberous ligament.
- Proximal branching: inferior rectal branch penetrating the sacrospinous ligament.
- Main nerve trunk passing through the coccygeus muscle. Elongated ischial spine.

PN entrapment usually occurs³²:

- Between the sacrospinous and the sacrotuberous ligaments (interligament clamp, 70% of cases).
- In the pudendal canal, 20%.
- In the urogenital diaphragm (dorsal nerve).
- In 20% of cases there is simultaneous involvement of the space between ligaments and the pudendal canal.

Table 1 shows the various routes of surgical approach: transperineal, transgluteal, and transischioanal.

• Transperineal technique.

Described by Shafik in 1991, this is a simple technique; the ischioanal fossa is entered through a small perianal incision; the trajectory of the inferior rectal nerve is followed up to the entrance into the pudendal canal, which has a good access; a small cut is made with scissors in the fascia of the internal obturator muscle, which is detached with the index finger, thus releasing the entire compromised pudendal nerve trajectory. If necessary, the interligament space can be opened up. This is a brief surgical procedure (5-10 minutes each side). No ligament is cut.

The levator ani muscle is untouched. The procedure is done on an ambulatory basis, is safe, and has no significant complications. The main disadvantage is that it is a blind technique, difficult to teach and to learn.

If pain persists and the distal latencies remain high, this surgical technique can be used to release the clamp between the sacrospinous and sacrotuberous ligaments, yielding very good outcomes⁴⁰.

• Transgluteal technique.

This technique, described by Robert, is more invasive than the above, and requires hospitalization. A 10-cm transgluteal incision is done. The main objective is to cut the clamp formed by the sacrospinous and sacrotuberous ligaments on the PN. Robert asserts that after 400 interventions he has seen no major complications; after a four-year follow-up there is significant improvement, but he recognizes that other subsequent treatments such as physical therapy may be necessary.

A 2-day hospitalization is required. Return to work may take from 10 days to 3 months. Complete cure is possible, but so are complications like urinary retention in 5% of patients, which requires catheterization. Several weeks may be needed before the neurapraxia resolves completely⁴¹.

Table 1 – Surgical approaches

Approach	Transperineal	Transgluteal	Transvaginal or trasrectal (males)
Size of the incision	small	large (10 cm)	small
Visual control of the nerve	–	++	–
Access to the pudendal canal	+++	+	+
Access to the sacrospinous ligament	++	+++	+++
Opening of the clamp between the 2 ligaments	no	yes	yes (partial)
Gluteal muscle incision	no	yes	no
Effect on urinary and anal incontinence	yes	??	??
Disadvantages	Blind procedure. Difficult to teach and learn	Problems from sectioning the ligaments	Problems from sectioning the ligaments

• Transvaginal or transischioirectal technique.

Described by Bautrant, the technique is done transvaginally in women (thus the name), but in men it is done transischioirectally and is called transischioirectal technique³².

With the patient in the lithotomy position, three segments of the PN are accessed through the ischioirectal fossa or the vagina, and the avascular space can be reached. Dissection exposes the medial aspect of each side of the pelvis after retracting the rectum and the levator ani. The purpose is to decompress the compromised areas; there is therefore no neurolysis or dissection near the nerve.

Intense postoperative gluteal pain occurs in 38% of patients; the pain is different from that at admission and can be attributed to the sectioning of the sacrospinous ligament and the abundance of nerves in some patients. The pain decreases progressively over the first month, and eventually disappears altogether.

Decompression always begins by opening the canal under the piriformis muscle on the inferior edge of the sacrospinous ligament. The compressed area can be explored after the perineural adipose tissue is reached. In 90% of cases, the sacrospinous ligament is sectioned in order to release the clamp.

The operation can proceed caudally if necessary, cutting the fibers of the falciform process of the sacrotuberous ligament until the pudendal canal is entered. At this stage, the entire canal is explored with the fingers and the decompression is completed, ensuring that the entire pudendal canal is free.

Bruising can be prevented by routinely leaving a drain in the ischioirectal area for 48 hours.

Hospitalization for 3 or 4 days. This is followed by pain-relieving kinesiotherapy and perineal reeducation. Nerve regeneration can take 6 to 18 months.

The complications described for surgical decompression are minor:

- Infection: UTI (7%), abscess (2.5%) with evacuation and drainage.
- Hemorrhage: 2%, injury to the pudendal artery branch and secondary false aneurysm in the superior gluteal artery branch.

The theoretical destabilization and overload of the sacroiliac joint as a complication of sectioning the ligaments have not been demonstrated to date in the known publications³².

Published series

The first published series of surgical decompression are small groups of patients; as the diagnosis becomes more recognized, the number of patients undergoing surgical decompression has also increased; Robert⁴¹ has reported 400 surgeries since 1989, Bautrant³² reported 104 decompressions, Beco²⁸ reported 74, Mouchel⁴² 192, and Popeney³⁹ 58. The vast majority of interventions have been performed on this side of the Atlantic, except for Popeney's group.

Persisting pain after decompression

Persisting pain can have different causes, as Weiss⁴³ points out:

- Pelvic floor myofascial trigger points that were present before surgery and are aggravated by the surgical trauma.
- Tenderness of the subcutaneous tissue, an important perpetuator of postsurgical pain.
- Sacroiliac joint dysfunction caused by the sectioning of the sacrotuberous and sacrospinous ligaments. A myofascial dysfunction generating trigger points may be produced.
- Intrinsic pathology of the branches of the PN. This is the most common cause of pain, and the most refractory to treatment.
- Other factors such as stress, insomnia, hormones, and diet.
- Central sensitization.

Conclusion

This review shows that PN entrapment is more common than we think and diagnose, but the actual frequency is unknown.

The specialties involved (urology, gynecology, proctology, neurology, pain specialists...) should make an effort to disseminate their knowledge about this disabling and little-known syndrome.

The relationship between PNES and myofascial pain syndrome should not be overlooked; we often do not know which caused the other.

The outcomes of conservative and surgical treatments are acceptable, but the least invasive one should be attempted first.

Conflict of interest

The authors state that they have no conflicts of interest.

REFERENCES

- Amarenco G, Lanoe Y, Perrigot M, Goudal H. A new canal syndrome: compression of the pudendal nerve in alcock's canal or perineal paralysis of cyclists. *Presse Med*. 1987;16:399.
- Shafik A. Pudendal canal syndrome: description of a new syndrome and its treatment. Report of seven cases. *Coloproctology*. 1991;13:102-9.
- Robert, et al. Neuropathic pain: a tunnel syndrome. *Surg-Radiol Anat*. 1998;20:93.
- Benson JT, Griffis K. Pudendal neuralgia, a severe pain syndrome. *Am J Obstet Gynecol*. 2005;192:1663-8.
- Prendergast SA, Weiss JM. Physical therapy and pudendal nerve entrapment. *Advance*. 2004;15:47.
- Rouvière H. *Anatomia Humana*. vol. 2, tronco. Editorial Masson; 2005.
- Spinosa JP, De Bisschop E, Laurencon J, Kuhn G, Dubuisson JB, Riederer BM. Sacral staged reflexes to localize the pudendal compression: an anatomical validation of the concept. *Rev Med Suisse*. 2006;2:2416-8, 2420-1.
- Shafik A, Doss SH. Pudendal canal: surgical anatomy and clinical implications. *Amer Surg*. 1999;65:176-80.
- Robert R, Brunet C, Faure A, Lehur PA, Labat JJ, Bensignor M, et al. Surgery of pudendal nerve in various types of perineal pain: course and results. *Chirurgie*. 1993-94;119:535-9.
- Grigorescu BA, Lazarou G, Olson TR, Downie SA, Powers K, Greston WM, et al. Innervation of the levator ani muscles: description of the nerve branches to the pubococcygeus, iliococcygeus, and puborectalis muscles. *Int urogynecol J Pelvic Floor Dysfunct*. 2007.
- Sobotta. *Atlas de anatomía humana*. vol. 2. Putz R, Pabst R, editors. Editorial Panamericana; 2006.
- Bautrant E, De Bisschop E, Vaini-elies V, Massonnat J, Aleman I, Buntinx J, et al. La prise en charge moderne des névralgies pudendales. A partir d'une série de 212 patientes et 104 interventions de décompression. *J Gynecol Obstet Biol Reprod (Paris)*. 2003;32:705-12.
- Andersen KV, Bovim G. Impotence and nerve entrapment in long distance amateur cyclists. *Acta Neurol Scand*. 1997;95:233-40.
- Kiff ES, Barnes PR, Swash M. Evidence of pudendal neuropathy in patients with perineal descent and chronic straining at stool. *Gut*. 1984;25:1279-82.
- Shafik A. Pudendal canal descompression for the treatment of fecal incontinence in complete rectal prolapse. *Am Surg*. 1996;62:339-43.
- Shafik A. Pudendal canal syndrome as a cause of vulvodynia and its treatment by pudendal nerve decompression. *Eur J Obstet Gynecol Reprod*. 1998;80:215-20.
- Benson JT, McClellan E. The effect of vaginal dissection on the pudendal nerve. *Obstet Gynecol*. 1993;82:387-9.
- Antolak SJJ, Hough DM, Pawlina W, Spinner RJ. Anatomical basis of chronic pelvic pain syndrome: the ischial spine and pudendal nerve entrapment. *Med Hypotheses*. 2002;59:349-53.
- Pisani R, Stubinski R, Datti R. Entrapment neuropathy of the internal pudendal nerve. Report of two cases. *Scand J Urol Nephrol*. 1997;31:407-10.
- Pessis E, Drapé JL, Guérini H, Bach F, Feydy A, Chevrot A. Nerve and vascular entrapment in athletes. *J Radiol*. 2007;88(1 pt 2):156-71.
- Lien KC, Morgan DM, Delancey JO, Ashton-Miller JA. Pudendal nerve stretch during vaginal birth: a 3-d computer simulation. *Am J Obstet Gynecol*. 2005;192:1669-76.
- Soga H, Nagata I, Murakami G, Yajima T, Takenaka A, Fujisawa M, et al. A histotopographic study of the perineal body in elderly women: the surgical applicability of novel histological findings. *Int Urogynecol J Pelvic Floor Dysfunct*. 2007;18:1423-30.
- Sunderland S. *Nerves and injuries*. Ed. Churchill Livingstone; 1976.
- Butler DS. *Movilización del sistema nervioso*. Barcelona: Ed. Paidotribo; 2002.
- Shafik A. Pudendal canal syndrome. A new etiological factor in prostatodynia and its treatment by pudendal canal decompression. *Pain Digest*. 1998;8:32-6.
- Shafik A. Pudendal canal decompression in the treatment of erectile dysfunction. *Arch Androl*. 1994;32:141-9.
- Loeser J. *Terapéutica del dolor*. Bonica. vol. II. Ed. McGraw-Hill; 2003. p. 1858.
- Beco J, Klimov D, Bex M. Pudendal nerve decompression in perineology: a case series. *Bmc Surg*. 2004;30:15.
- Mollo M, Bautrant E, Rossi-Seignert A-K, Collet S, Boyer R, Thiers-Bautrant D. Evaluation of diagnostic accuracy of colour duplex scanning, compared to electromyography, diagnostic score and surgical outcomes, in pudendal neuralgia by entrapment: a prospective study on 96 patients. *Pain*. 2009;142:159-63.
- Bisschop E, Bautrant E. EMG: which one and why? Considerations regarding pudendal nerve terminal motor latencies (pntml). 31 Meeting Annual of the International Urogynecological Association (IUGA 2006). Available at: www.perineology.com/files/de-bisschop-athens2006.pdf.
- Kiff E, Swash M. Slowed conduction in the pudendal nerves in idiopathic (neurogenic) faecal incontinence. *Br J Surg*. 1984;71:614-6.
- González-Hidalgo M. Exploración neurofisiológica del suelo de la pelvis. *Rev Neurol*. 1998;26:432-8.
- Wallace JM. Update on pharmacotherapy guidelines for treatment of neuropathic pain. *Curr Pain Headache Rep*. 2007;11:208-14.
- Harkins S, Linford J, Cohen J, Kramer T, Cueva L. Administration of clonazepam in the treatment of tmd and associated myofascial pain: a double-blind pilot study. *J Craniomandib Disord*. 1991;5:179-86.
- Sator-katzenschlager SM, Scharbert G, Kress HG, Frickey N, Ellend A, Gleiss A, et al. Chronic pelvic pain treated with gabapentin and amitriptyline: a randomized controlled pilot study. *Wien klin wochenschr*. 2005;117:761-8.
- Kovacs P, Gruber H, Piegger J, Bodner G. New, simple, ultrasound-guided infiltration of the pudendal nerve: ultrasonographic technique. *Dis Colon Rectum*. 2001;44:1381-5.
- Anderson RU, Wise D, Sawyer T, Chan Ca. Sexual dysfunction in men with chronic prostatitis/chronic pelvic pain syndrome: improvement after trigger point release and paradoxical relaxation training. *J Urol*. 2006;176(4 pt 1): 1534-8; discussion 1538-9.

38. Hsieh YL, Kao MJ, Kuan TS, Chen SM, Chen JT, Hong CZ. Dry needling to a key myofascial trigger point may reduce the irritability of satellite mtrps. *Am J Phys Med Rehabil*. 2007;86:397-403.
39. Popeney C, Ansell V, Renney K. Pudendal entrapment as an etiology of chronic perineal pain: diagnosis and treatment. *Neurourol Urodyn*. 2007;26:820-7.
40. Shafik A. Pudendal canal syndrome: description of a new syndrome and its treatment. Report of seven cases. *Coloproctology*. 1991;13:102-9.
41. Robert R, Labat JJ, Bensignor M, Glemain P, Deschamps C, Raoul S, et al. Decompression and transposition of the pudendal nerve in pudendal neuralgia: a randomized controlled trial and long-term evaluation. *Eur Urol*. 2005;47:403-8.
42. Mouchel J, Mouchel T, Zaka P. Trans-perineal pudendal nerve decompression. 31 Meeting Annual of the International Urogynecological Association (IUGA 2006). Available at: www.perineology.com/files/mouchel-athens2006.pdf.
43. Weiss J. Treatment options for persistent pain following pudendal nerve decompression surgery. 31 Meeting annual of the international urogynecological association (iuga 2006). Available at: www.perineology.com/files/weiss-athens2006.pdf.