



## Image of the month

## Multifocal small bowel adenocarcinoma with liver metastasis based on a 16-year history of Crohn's disease

### Adenocarcinoma de intestino delgado Multifocal con metástasis hepática basado en una historia de enfermedad de Crohn de 16 años

Wei Yang,<sup>a</sup> Chendong He<sup>b,\*</sup>

<sup>a</sup> Department of Radiology, Jiangsu Province Hospital of Chinese Medicine & Affiliated Hospital of Nanjing University of Chinese Medicine, Nanjing 210029, Jiangsu, China

<sup>b</sup> Department of Radiology, the First Affiliated Hospital of Bengbu Medical University, Bengbu 233004, Anhui, China

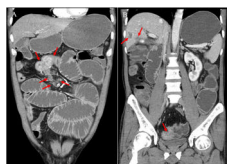


Fig. 1

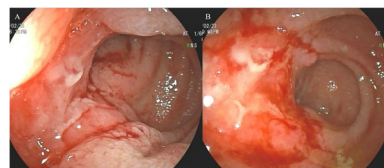


Fig. 2

A 49-year-old male patient with a 16-year history of Crohn's disease had been treated with mesalazine and infliximab. His abdominal pain intensified one year ago, and computed tomography revealed multi-segmental thickening of the small bowel and liver lesions (Fig. 1A & B). Endoscopy found multiple small bowel ulcers (Fig. 2A & B). Endoscopic biopsy and enterectomy specimens confirmed moderately differentiated adenocarcinoma, and liver biopsy confirmed metastatic adenocarcinoma.

Although rare, multifocal small bowel adenocarcinoma has significantly increased in frequency among patients with Crohn's disease, especially those with long disease courses and active stages. When the symptoms of Crohn's disease worsen, the possibility of malignant transformation should be considered.

#### Statement

All authors agree with the content of the manuscript. The content has not been published or submitted for publication elsewhere.

#### Ethics committee approval

N/A.

#### Funding

None.

#### Patient consent for publication

Written informed consent was obtained from the patient.

#### Declarations of interest

None.

\* Corresponding author.

E-mail address: [hcd1222@163.com](mailto:hcd1222@163.com) (C. He).

<http://dx.doi.org/10.1016/j.cireng.2024.01.007>

2173-5077/© 2024 AEC. Published by Elsevier España, S.L.U. All rights reserved.