



Image of the month

Arterioenteric fistula in a patient with pancreato-renal transplant[☆]

Fístula arterio-entérica en paciente con trasplante pancreato-renal

Renan Carlo Colombari,^{a,*} María Fernández Martínez,^a Fernando García Boyano,^b Álvaro Morales Taboada^a

^a Servicio de Cirugía General y Del Aparato Digestivo, Hospital General Universitario Gregorio Marañón, Madrid, Spain

^b Servicio de Cirugía Vascular, Hospital General Universitario Gregorio Marañón, Madrid, Spain

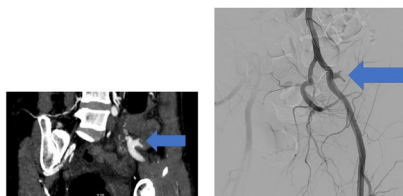


Fig. 1

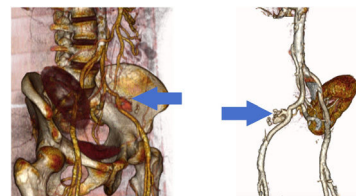


Fig. 2

A 50-year-old woman with a double kidney and pancreatic transplant due to complications of diabetes presented to the Emergency Department with hematochezia and syncope. CT angiography described an arterioenteric fistula (from arterial anastomosis to intestinal anastomosis of the pancreatic graft) with active bleeding. Since the arteriography did not show extravasation and the patient was still unstable, urgent surgery was decided on: resection of the pancreatic graft and middle ileum (fistula area) with ileo-ileal intestinal anastomosis, segmental resection of the left external iliac artery and ilio-iliac end-to-end bypass (Figs. 1 and 2).

Diagnosis: arterioenteric fistula from arterial anastomosis to intestinal anastomosis of pancreatic graft.

Funding

This study has not received any funding.

Ethics

The authors declare that they hold the patient's informed consent document.

The authors also declare that the study described has not been previously published (a poster of the clinical case is pending publication at the 24th National Surgery Meeting in Alicante from October 24th to 27th, 2023), that its publication is

authorised by all authors and expressly or tacitly by the competent authorities of the institution in which the study was carried out, and that, if accepted, it will not be published in any other medium in the same format, in English or any other language, including in electronic form, without the written consent of the copyright holder.

Conflict of interest

The authors declare no conflict of interest.

[☆] Please cite this article as: Colombari RC, Martínez MF, Boyano FG, Taboada ÁM. Fístula arterio-entérica en paciente con trasplante pancreato-renal. Cir Esp. 2024. <https://doi.org/10.1016/j.ciresp.2023.09.006>

* Corresponding author.

E-mail address: renancolombari@hotmail.com (R.C. Colombari).

<http://dx.doi.org/10.1016/j.cireng.2024.01.001>

2173-5077/© 2024 Published by Elsevier España, S.L.U. on behalf of AEC.