



Image of the month

Gallbladder duplication[☆]

Duplicidad vesicular

Natalia Morell,^{*} Vasile Veste, Ramon Masvidal

Cirugía General, Clínica Bofill, Girona, Spain

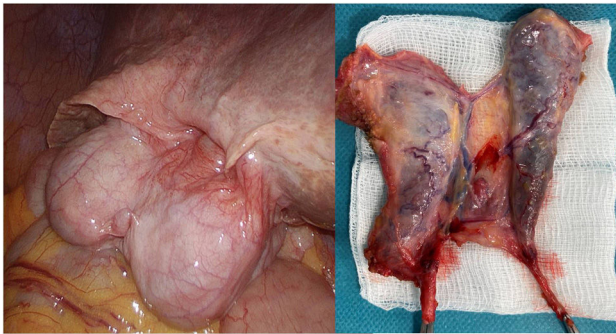


Fig. 1

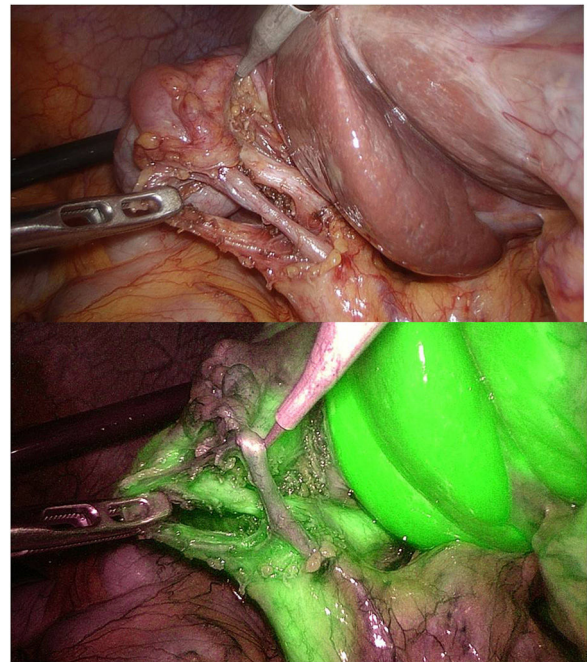


Fig. 2

A 78-year-old female patient was admitted due to acute cholecystitis with a probable mural abscess (detected by CT), and conservative treatment was initiated. The subsequent radiological study (ultrasound, MRCP) ruled out an abscess and revealed gallbladder duplication. Due to the persistence of pain and in order to plan the surgical intervention, another radiological study was performed (ultrasound, MRCP), finding choledocholithiasis. ERCP was performed with sludge extraction, and laparoscopic cholecystectomy with intraoperative ICG cholangiography was scheduled. Intraoperatively, we observed Boyden's type 2 gallbladder duplication with an H-shaped duct (Fig. 1). Standard cholecystectomy was performed, without incident (Fig. 2).

[☆] Please cite this article as: Morell N, Veste V, Masvidal R. Duplicidad vesicular. Cir Esp. 2024;102:118–118.

^{*} Corresponding author.

E-mail address: dramorell@clinicabofill.net (N. Morell).

<http://dx.doi.org/10.1016/j.cireng.2023.05.017>

2173-5077/© 2023 AEC. Published by Elsevier España, S.L.U. All rights reserved.