

Letters to the Editor

Do Simultaneous Colectomy and Nephrectomy in Synchronous Tumours Extend Hospital Stay?☆



¿Alarga la estancia la colectomía y nefrectomía simultánea en tumores sincrónicos?

To the Editor:

We have read with interest the study by Martín Arnau et al.¹ about simultaneous colectomy and nephrectomy in synchronous tumors. We recently had the occasion to treat a similar

case, and its exceptional nature has encouraged us to report it and to comment on some details of the Martín series.

A 57-year-old woman was being studied for iron deficiency anemia. Colonoscopy showed evidence of a rectal mass 7 cm

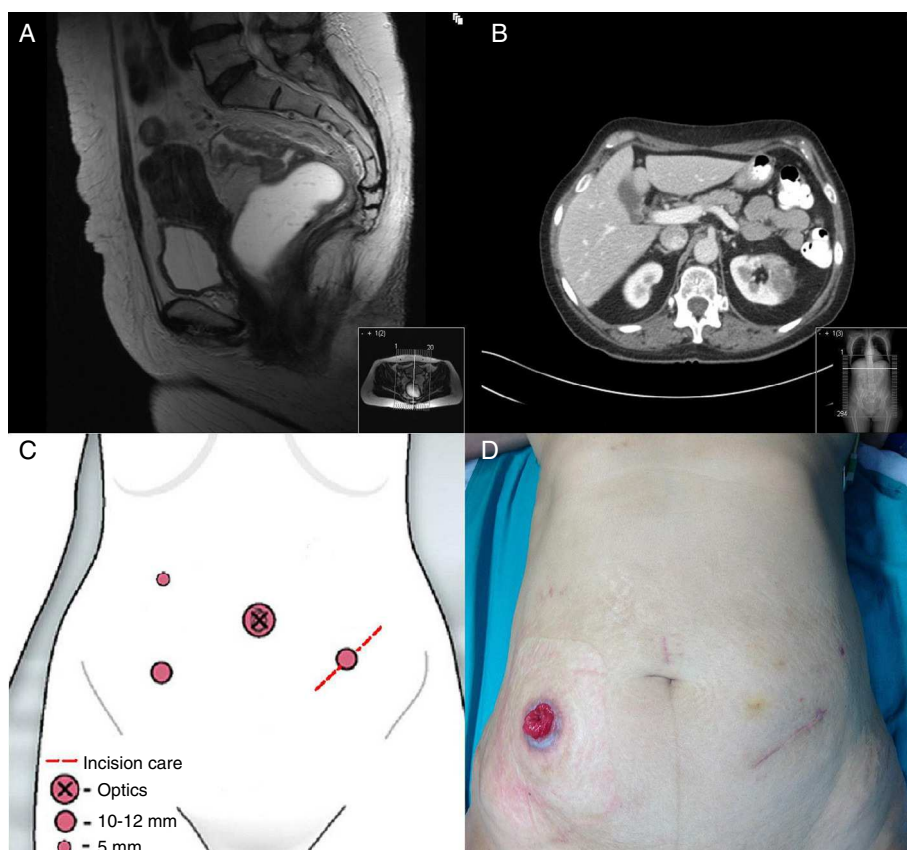


Fig. 1 – (A) Pelvic MRI demonstrating rectal mass that does not surpass the muscularis propria; (B) axial CT scan of the abdomen showing a left renal mass measuring 5 cm; (C) trocar placement used for nephrectomy and lower anterior resection; (D) image of the abdomen of the patient with protective ileostomy.

☆ Please cite this article as: Peña Ros E, Parra Baños PA, González Valverde FM, Albarracín Marín-Blázquez A. ¿Alarga la estancia la colectomía y nefrectomía simultánea en tumores sincrónicos? Cir Esp. 2015;93:269–270.

from the anal margin; local staging by pelvic MRI (Fig. 1A) and endorectal ultrasound was T2N0. Abdominal CT showed a mass in the left kidney suggestive of a primary neoplasm (Fig. 1B).

In coordination with the urology department, a laparoscopic approach was used with 4 trocars situated in order to serve both procedures (Fig. 1C), with the patient placed in Lloyd-Davies position. We began with complete mobilization of the splenic angle, leaving the renal fossa free in order to perform standard nephrectomy and bag extraction through a 6 cm incision in the left flank. We completed the lower anterior resection with mechanical end-to-end anastomosis and protective ileostomy (Fig. 1D). The patient progressed favorably and was discharged on the 5th day post-op. The pathology study reported a complete mesorectum with the distal margin at 2.8 cm and a free circumferential margin, with 18 isolated lymph nodes that were free of neoplastic infiltration and a clear cell renal cell carcinoma (TNMpT3).

The simultaneous laparoscopic approach is ideal in ipsilateral tumors, as indicated by the authors and coinciding with most published cases.^{2,3} Occasionally, it may be necessary to add an extra trocar or change the position to lateral decubitus to perform the nephrectomy, although this was not necessary in our case. When a contralateral (or bilateral) approach is necessary, the advantages decrease as the surgical time is longer and morbidity increases.^{1,4} The authors conclude that the simultaneous approach lengthens hospital stay; this datum needs to be confirmed statistically. In our case, hospitalization did not increase due to the combined procedures. Patient characteristics, age, comorbidities, tumor type and experience of the 2 surgical teams in advanced laparoscopic surgery can be determining factors in this regard. The reported mean hospitalization of 15 days is striking, although the conditioning factors are complex and the series is small. It would be interesting to know whether the results would be any better with an open approach.

We cannot agree with Dr. Martín when she states that this technique should be reserved for high-level hospitals and resources, as we are an experienced team that only has available the resources typical of a secondary-level hospital in the public healthcare system. We do concur, however, that an individual approach should be recommended for each patient.

Funding

The present study has received no funding.

The present study has not been previously presented at any congress.

REFERENCES

- Martín Arnau AB, Ochoa Vargas C, Peña González JA, Targarona Soler EM. Colectomía y nefrectomía simultánea en tumores sincrónicos. *Cir Esp*. 2014. <http://dx.doi.org/10.1016/J.CIRESP.2014.04.006>.
- Napolitano C, Santero GA, Valdano L, Salyati V, Martorano M. Simultaneous totally laparoscopic radical nephrectomy and laparoscopic left hemicolectomy for synchronous renal and sigmoid colon carcinoma: Report of a case. *Int J Colorectal Dis*. 2006;21:92–3.
- Nishiyama N, Yamamoto S, Matsuoka N, Fujimoto H, Moriya Y. Simultaneous laparoscopic descending colectomy and nephroureterectomy for descending colon carcinoma and left ureteral carcinoma: Report of a case. *Surg Today*. 2009;39:728–32.
- Veenstra GM, Fossion LM, de Laet K, Luijten AA. Synchronous laparoscopic radical nephrectomy left and contralateral right hemicolectomy during the same endoscopic procedure. *ISRN Surg*. 2011;2011:179456.

Emilio Peña Ros^{a,*}, Pedro A. Parra Baños^a,
Francisco Miguel González Valverde^a,
Antonio Albarracín Marín-Blázquez^{a,b}

^aServicio de Cirugía General y del Aparato Digestivo,
Hospital General Universitario Reina Sofía, Murcia, Spain

^bUniversidad Católica San Antonio, Murcia, Spain

*Corresponding author.

E-mail address: emilio.doctor@gmail.com (E. Peña Ros).

2173-5077/

© 2014 AEC. Published by Elsevier España, S.L.U. All rights reserved.

Indications for Anti-Reflux Surgery in Barrett's Esophagus[☆]



Indicaciones de la cirugía antirreflujo en pacientes con esófago de Barrett

Dear Editor,

In the Editorial from the May issue of *Cirugía Española*, Ruiz de Angulo et al. pose the question of whether surgical

indications should be extended in Barrett's esophagus after considering the recent publication in *JAMA* about the secondary effects of long-term proton pump inhibitor (PPI) use (particularly with regards to possible vitamin B₁₂ deficiency).^{1,2} In a very balanced manner, and based on the

[☆] Please cite this article as: Ortega Deballon P. Indicaciones de cirugía antirreflujo en el esófago de Barrett. *Cir Esp*. 2015;93:270–271.