



Image of the month

Giant Abdominal Pseudocyst: A Rare Complication of Incisional Hernia Repair With Mesh^{☆,☆☆}



Pseudoquiste gigante de pared abdominal: una complicación infrecuente de la eventroplastia con malla de sustitución

David Saavedra-Perez,^{*} Guerson Benarroch, Óscar Vidal, Juan Carlos Garcia-Valdecasas

Departamento de Cirugía General y Digestiva, Instituto de Enfermedades Metabólicas y Digestivas, Hospital Clínic de Barcelona, Barcelona, Spain

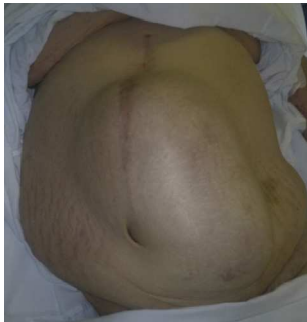

Fig. 1

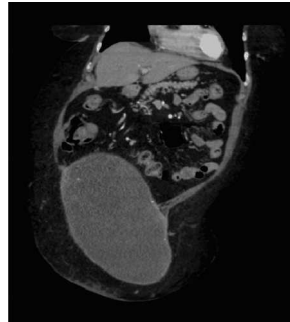


Fig. 2

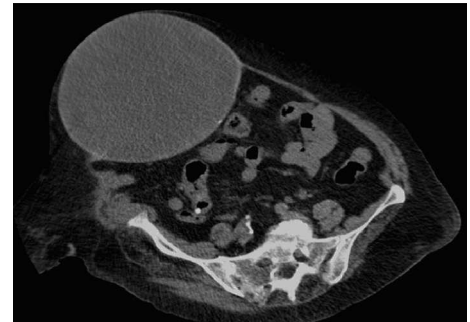


Fig. 3

A 79-year-old woman was referred to our department due to an abdominal wall tumor (Fig. 1). Her medical history included midline laparotomy in 1982 and strangulated incisional hernia repair (with polytetrafluoroethylene prosthesis) in 2006. Computed tomography showed a cyst measuring 31 cm × 19 cm × 17 cm on the right rectus abdominis muscle (Figs. 2 and 3). The lesion was completely resected, with primary closure of the defect and placement of polypropylene mesh. The pathology study showed evidence of granulation tissue with chronic inflammation (anterior wall), granulomatous reaction to a foreign body, fibrosis (posterior wall) and no malignancy. Pseudocyst is defined as a collection of fluid that is not covered by epithelium. There have been other denominations such as chronic seroma cyst and giant fibrous cyst, but the histology confirms the pseudocyst.

Conflict of Interests

The authors have no conflict of interests to declare.

All the authors participated in the writing of this text and the review of the images and accept their being presented for publication.

[☆] Please cite this article as: Saavedra-Perez D, Benarroch G, Vidal Ó, Garcia-Valdecasas JC. Pseudoquiste gigante de pared abdominal: una complicación infrecuente de la eventroplastia con malla de sustitución. Cir Esp. 2014;92:283.

^{☆☆} This paper was presented at the 12th National Congress of Abdominal Wall Surgery, May 23–24, 2013 in Barcelona, Spain.

^{*} Corresponding author.

E-mail address: dsaavedr@clinic.ub.es, seelowen@msn.com (D. Saavedra-Perez).

2173-5077/\$ – see front matter © 2013 AEC. Published by Elsevier España, S.L. All rights reserved.