

Image of the month

Intestinal Neurilemmoma[☆]

Neurilemmoma intestinal

René Santiago Borges Sandrino,^{*} Enia Ramón Musibay,
Ilionis Escobar Rojas, Wilfredo Ernesto Santiesteban Pupo

Servicio de Cirugía General, Hospital General Docente Dr. Carlos J. Finlay, La Habana, Cuba

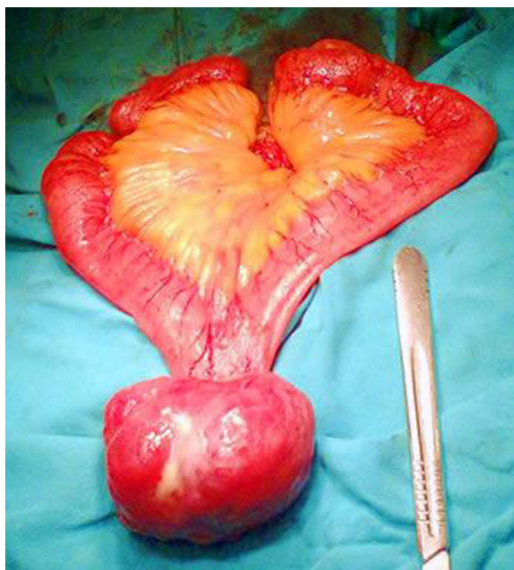

Fig. 1

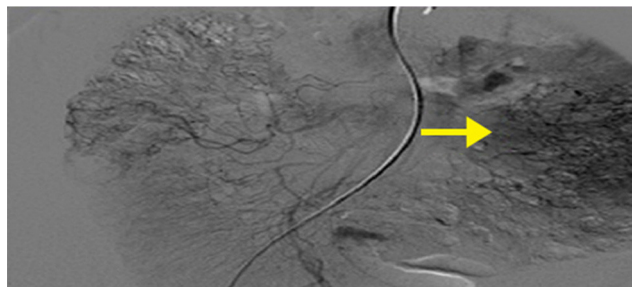


Fig. 2

The patient is a 53-year-old female that presented with multiple foul-smelling tarry stools. She was admitted with a diagnosis of gastrointestinal bleeding. Physical examination revealed a tumor in the mesogastrium that was irregular, painful and adhered to deep planes. Endoscopic study of the digestive tract and digital subtraction angiography of the superior mesenteric artery and the celiac trunk revealed the presence of a vascularized mass in the ileal branches. The mass was removed by laparotomy, and the pathological study (Figs. 1 and 2) reported it to be a small intestine neurilemmoma. The patient had an uneventful recovery and was discharged on the tenth day after surgery.

Conflict of interests

The authors of the study present no conflict of interests.

[☆] Please cite this article as: Borges Sandrino RS, Ramón Musibay E, Escobar Rojas I, Santiesteban Pupo WE. Neurilemmoma intestinal. Cir Esp. 2014;92:e5.

^{*} Corresponding author.

E-mail address: rborges@infomed.sld.cu (R.S. Borges Sandrino).

2173-5077/\$ – see front matter © 2013 AEC. Published by Elsevier España, S.L. All rights reserved.