

Liver Abscess Due to *Listeria monocytogenes*★

Absceso hepático por *Listeria monocytogenes*

Infections caused by *Listeria monocytogenes*, a mobile gram positive bacillus, are usually associated with immunosuppressed states. Most cases present as meningitis or primary bacteraemia. Other types of presentations are extremely rare.

We report the case of a 57 year old man, with a prior history of type 2 diabetes mellitus treated with oral anti-diabetic medication and cholecystectomy in 1990. He presented a 3-month history of general malaise and fever of up to 40°. He consulted 2 weeks after the start of the symptoms, due to persistence of malaise, intermittent fever, associated with myalgias, anorexia and weight loss. The first time he came to the emergency department he was treated with endovenous analgesia and was discharged. Subsequently, he consulted three different doctors and was finally admitted to complete the study of his symptoms. A CT scan of the abdomen and pelvis revealed 2 hypodense hepatic lesions of 25 mm in segment VIII and another two in segments VII and VI of 52 and 59 mm, respectively, displacing the portal vessels. In the mid third of the right

kidney a solid image of 25 mm maximum diameter was observed, compatible with a renal cell carcinoma. He was then transferred to the Hospital Militar in Santiago de Chile for management.

He was initially evaluated by urology, and a staging study of renal cancer was started. Blood tests revealed leukocytes 7.4 K/ μ L, neutrophils 11%, ESR 75 mm/h, alkaline phosphatase 195 U/L, AST 117 U/L.

A CT scan revealed a heterogeneous liver with the presence of ill-defined hypodense focal lesions in the VII y VIII segments (8 cm), caudate (2.5 cm) and VI and VII (8 cm), this last lesion presented a focal area of 9 mm that was more hypointense (Fig. 1). In the anterior aspect of the middle third of the right kidney a solid nodule of hypodense structure was revealed with a 2.7 cm diameter. The patient was evaluated by a digestive surgeon who decided hospitalization and treatment. Serologies for viral hepatitis were negative, blood cultures were negative, alfa fetoprotein and carcinoembryonic antigen were negative. Empiric antibiotic

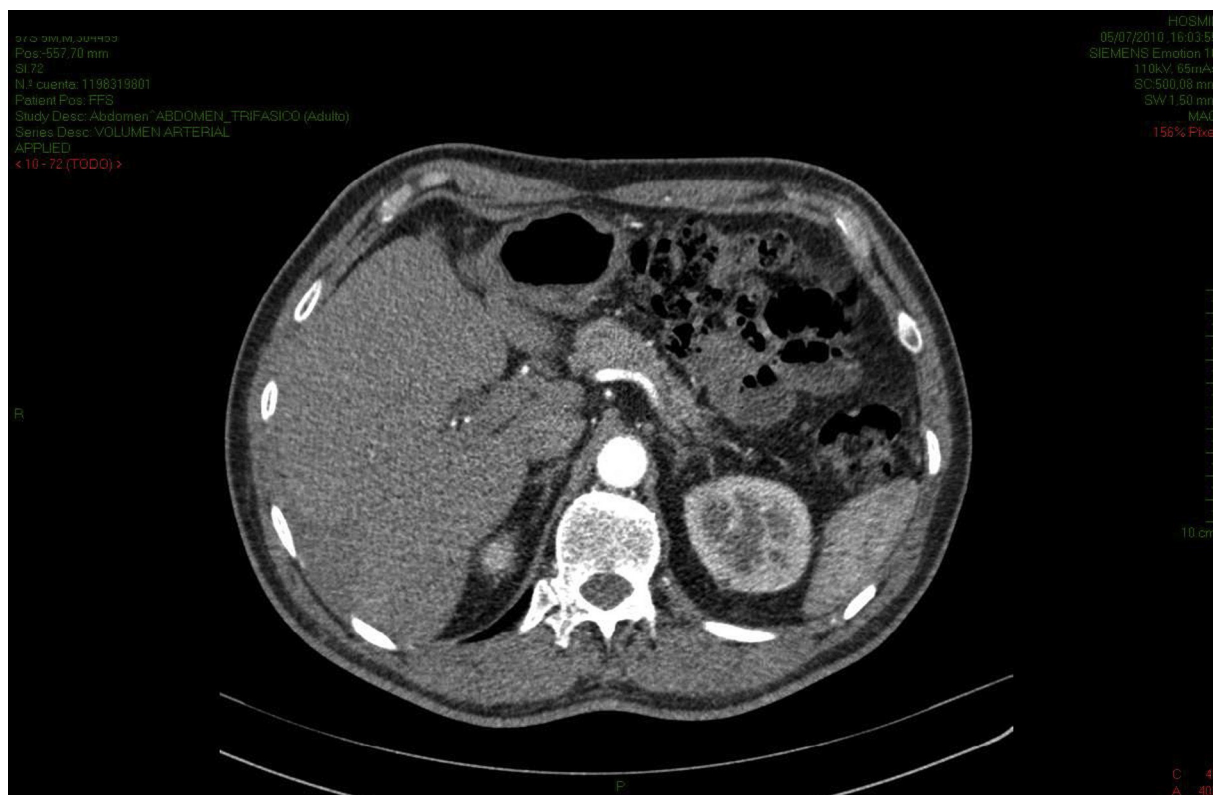

Fig. 1 – Abdominal and pelvic CT: heterogeneous liver with the presence of ill-defined hypodense focal lesions in the VII and VIII segments (8 cm), caudate (2.5 cm) and VI and VII (8 cm).

★ Please cite this article as: Onetto C, Ríos H, Domenech A, Schiappacasse G, Estay C. Absceso hepático por *Listeria monocytogenes*. Cir Esp. 2013;94:267-269.

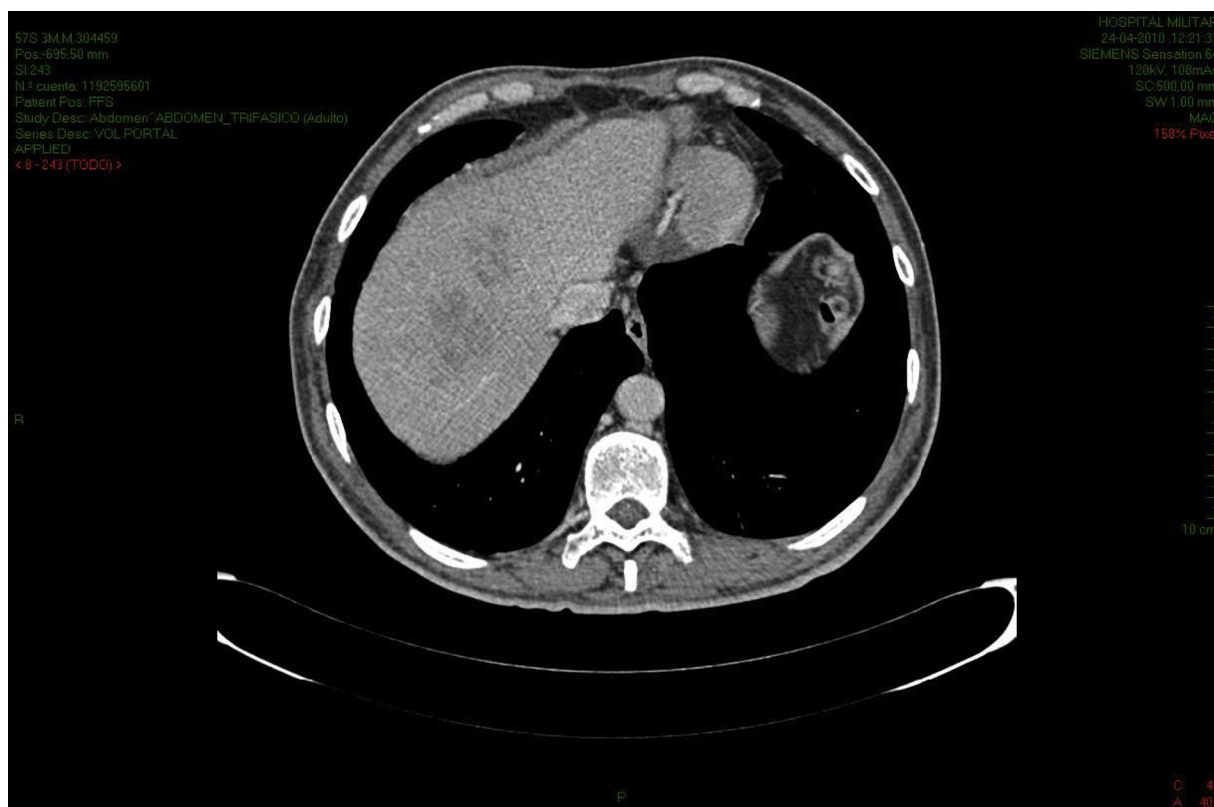


Fig. 2 – Control CT scan after 6 weeks of antibiotic treatment, progressive decrease of the liver lesions.

treatment was started using intravenous 2 g ceftriaxone/24 h and 500 mg metronidazol/8 h. A CT guided fine-needle aspiration of a liver lesion was performed, obtaining 15 ml of foul smelling purulent fluid. Aerobic and anaerobic cultures were performed, which were positive for *L. monocytogenes*. Antibiotic treatment was changed to ampicillin 1.000 mg and sulbactam 500 mg, 2 vials every 6 h for 3 days, ampicillin 3 g every 6 h for 16 days. Ten days after starting treatment a control CT scan was performed, and a partial regression of the focal lesions was seen, with the appearance of a subcapsular collection of 4 cm diameter in segment VI; a percutaneous drainage was performed and maintained for 5 days. Treatment was completed with oral amoxicillin 1 g every 8 h for four weeks. The patient responded favourable, without fever or symptoms, and the lesions progressively diminished on control scans (Fig. 2).

Liver infections caused by *L. monocytogenes* are exceptionally rare. Patients with this condition usually have comorbidities that cause a state of chronic immunosuppression.

Different mechanisms for this infection have been proposed: the arrival of the bacteria to the hepatic circulation after a bacteremia, or a bacterial translocation to the venous portal system after enteric colonization.¹ Clinical manifestations of this infection can imitate a neoplastic condition, and the diagnosis is often delayed. In previously described cases and in the present case, without extrahepatic manifestations, the clinical scenario was a group of non-specific symptoms,

malaise, anorexia, weight loss, intermittent fever and night sweats, with over a week duration.²

There are three different patterns of liver infection: solitary abscess, multiple abscesses and hepatitis. In the literature, the case reports of solitary abscesses were all in patients with a prior history of diabetes mellitus. Patients reported with multiple abscesses have more severe clinical presentations, with systemic symptoms and extrahepatic manifestations. In patients with hepatitis, of the 3 case reports, 2 also presented meningeal manifestations.³⁻⁵ The cornerstone of treatment is prolonged antibiotic therapy (over 2 weeks), initially endovenous; however, the duration of treatment has not been clearly established. It is also not known if percutaneous drainage can reduce the time to resolution of the infection.^{1,2}

REFERENCES

1. Braun T, Travis D, Dee R, Nieman R. Liver abscess due to *Listeria monocytogenes*: case report and review. *Clin Infect Dis*. 1993;17:267.
2. Brönnimann S, Baer HU, Malinverni R, Büchler MW. *Listeria monocytogenes* causing solitary liver abscess. Case report and review of the literature. *Dig Surg*. 1998;15:364-8.
3. Jenkins D, Richards JE, Rees Y, Wicks AC. Multiple listerial liver abscesses. *Gut*. 1987;28:1661-2.

4. Marino P, Maggioni M, Preatoni A, Cantoni A, Invernizzi F. Liver abscesses due to *Listeria monocytogenes*. *Liver*. 1996;16:67-9.
5. Ribière O, Coutarel P, Jarlier V, Bousquet O, Balderacchi U, Lecouturier JP, et al. *Listeria monocytogenes* liver abscess. In a diabetic patient. *Presse Med*. 1990;19:1538-40.

Camila Onetto^{a*}, Horacio Ríos^a, Alfredo Domenech^b,
Giancarlo Schiappacasse^c, Camila Estay^d

^aDepartamento de Cirugía, Hospital Militar, Santiago, Chile

^bDepartamento de Urología, Hospital Militar, Santiago, Chile

^cDepartamento de Radiología, Hospital Militar, Santiago, Chile

^dDepartamento de Medicina, Universidad de los Andes, Santiago, Chile

*Corresponding author.

E-mail address: camilaonetto@gmail.com (C. Onetto).

2173-5077/\$ – see front matter

© 2011 AEC. Published by Elsevier España, S.L. All rights reserved.

Autologous Cephalic Duodenopancreatectomy With Superior Mesenteric Vein Dissection and Reconstruction Using the Renal Vein

Duodenopancreatectomía cefálica con resección de vena mesentérica superior y reconstrucción mediante interposición de vena renal autóloga

Case report: A 43-year-old woman, without any prior medical history, consulted for epigastric abdominal pain and nausea of 9-month duration. Blood tests revealed an amylase of 183 U/L. An abdominal ultrasound and abdominopelvic CT revealed a mass in the pancreatic head. The proximal segment of the superior mesenteric vein (of approximately 3 cm length) was infiltrated and thrombosed and enlarged peripancreatic lymph nodes were seen (Fig. 1). An echoendoscopy was used to perform a biopsy of the mass that was positive for malignancy but was unable to define the histology; the suspicion was neuroendocrine tumor. An MRI confirmed the pancreatic mass, observing that it surrounded the superior mesenteric vein. An octreoscan showed uptake in the epigastric area.

Surgery was scheduled and a tumor in the pancreatic head infiltrating the superior mesenteric vein was observed. A Whipple's cephalic duodenopancreatectomy was performed with an en bloc resection of the superior mesenteric vein and reconstruction by interposition of the previously resected left renal vein (Fig. 2).

The patient had an uneventful postoperative course. On the 6th postoperative day and control angio-CT and Doppler ultrasound were performed and permeability of the renal

arteries and superior mesenteric arteries were checked. She was discharged on postoperative day 11 asymptomatic and tolerating an oral diet.

The pathology study revealed an endocrine tumor of 3.5 cm×3.5 cm. The resection margins were free of neoplasia and six isolated lymph nodes were also free of neoplasia. A tumoral thrombus was found in the superior mesenteric vein with histology compatible with a well-differentiated trabecular tumor.

One month and a half after surgery the patient continues well, and a control CT scan shows permeability of the superior mesenteric vein and left kidney of a normal size and morphology. A follow-up blood test revealed chromogranine 115.1. All other parameters were normal.

A complete resection is the only potentially curative treatment for neuroendocrine tumors. Frequently these tumors are malignant, and local invasion at the time of diagnosis can prevent a radical removal of the tumor; in these cases a cytoreductive approach can be proposed. An aggressive surgical approach in cases of advanced disease can prolong survival, and it is therefore justified, including, if necessary, resection of adjacent organs (stomach, colon, kidneys, adrenal glands) and/or main vessels.⁵⁻⁷

The reconstruction of the resected vein can be performed by a primary anastomosis (8 in approximately 88% of cases) or by using grafts, both synthetic or autologous (splenic, jugular, gonadal, iliac, femoral, saphenous or umbilical veins). The reconstruction with an autologous venous graft should be considered only in selected cases: when the

* Please cite this article as: Markinez Gordobil I, Ruiz Montesinos I, Arteaga Martín X, Medrano Gómez MÁ, Beguiristain Gómez A. Duodenopancreatectomía cefálica con resección de vena mesentérica superior y reconstrucción mediante interposición de vena renal autóloga. *Cir Esp*. 2013;94:269-271.