

## Original Article

# Laparoscopic Gastric Plication: a New Surgery for the Treatment of Morbid Obesity

Jordi Pujol Gebelli,<sup>a</sup> Amador García Ruiz de Gordejuela,<sup>a,\*</sup> Anna Casajoana Badía,<sup>a</sup> Lluís Secanella Medayo,<sup>a</sup> Andrew Vicens Morton,<sup>b</sup> Carles Masdevall Noguera<sup>a</sup>

<sup>a</sup>Servei de Cirurgia General i de l'Aparell Digestiu, Hospital Universitari de Bellvitge, L'Hospitalet de Llobregat, Barcelona, Spain

<sup>b</sup>Servei d'Urologia, Hospital Universitari de Bellvitge, L'Hospitalet de Llobregat, Barcelona, Spain

## ARTICLE INFORMATION

## Article history:

Received August 25, 2010

Accepted February 13, 2011

## Keywords:

Morbid obesity

Laparoscopic Gastric Plication

Bariatric surgery

## A B S T R A C T

**Introduction:** Laparoscopic Gastric Plication is a new technique derived from sleeve gastrectomy. Plication of the greater curvature produces a restrictive mechanism that causes weight loss. The results of the first cases where this technique has been applied in this hospital are presented.

**Methods:** A review was made of patients operated on in our hospital between November 2009 and December 2010. Plication of the gastric greater curvature was performed under general anaesthetic and by laparoscopy using 3 lines of sutures and with an orogastric probe as a guide. The results of the morbidity, mortality and weight loss are presented.

**Results:** A total of 13 patients were operated on (7 women). The maximum body mass index (BMI) varied between 37.11 kg/m<sup>2</sup> and 51.22 kg/m<sup>2</sup> at the time of the operation. The most frequently found morbidity was nausea and vomiting. Two patients required further surgery due to intractable vomiting and total dysphagia; in one the plication unfolded, and in the second it was converted into vertical gastrectomy.

**Conclusions:** Laparoscopic Gastric Plication is a new surgical technique which gives equivalent short-term results as vertical gastrectomy. It is a reproducible and reversible technique with results and indications still to be validated.

© 2010 AEC. Published by Elsevier España, S.L. All rights reserved.

## Gastroplastia tubular plicada, una nueva técnica para el tratamiento de la obesidad mórbida

## R E S U M E N

**Introducción:** La gastroplastia tubular plicada es una nueva técnica que deriva de la gastrectomía vertical. La plicatura de la curvatura mayor genera un mecanismo restrictivo que ocasiona la pérdida ponderal. En este trabajo se presentan los resultados de los primeros casos en los que se ha aplicado esta técnica en nuestro centro.

**Métodos:** Revisión de pacientes intervenidos en nuestro centro entre noviembre de 2009 y diciembre de 2010. Bajo anestesia general y por laparoscopia se realiza la plicatura

## Palabras clave:

Obesidad mórbida

Gastroplastia tubular plicada

Cirugía bariátrica

\*Corresponding author.

E-mail address: gordeju@me.com (A. García Ruiz de Gordejuela).

de la curvatura mayor gástrica sobre sí misma con 3 líneas de sutura y con una sonda orogástrica como guía. Se presentan los resultados relativos a morbilidad, mortalidad y pérdida ponderal.

**Resultados:** Se han intervenido 13 pacientes (7 mujeres). El IMC máximo oscila entre 37,11 kg/m<sup>2</sup> y 51,22 kg/m<sup>2</sup> en el momento de la intervención. La morbilidad más frecuentemente encontrada son náuseas y vómitos. Dos pacientes requirieron reintervención por vómitos incoercibles y disfagia absoluta, en uno se deshizo la plicación y en el segundo se convirtió a gastrectomía vertical. La pérdida ponderal a los 3 y 6 meses es equivalente a la de la gastrectomía vertical.

**Conclusiones:** La gastroplastia tubular plicada es una nueva técnica quirúrgica que presenta resultados a corto plazo equivalentes a los de la gastrectomía vertical. Se trata de una técnica reproducible y reversible con resultados e indicaciones aún por validar.

© 2010 AEC. Publicado por Elsevier España, S.L. Todos los derechos reservados.

## Introduction

Among the different branches of general and digestive surgery, bariatric surgery is probably one of those that have evolved most over the past 30 years. A limited surgery with few resources in the early 80's, it has become a set of techniques with well-defined indications, proven results and continuous technical and tactical advances.<sup>1</sup>

In the history of bariatric surgery, vertical gastroplasty and gastric banding were the first purely restrictive surgeries. Since then restrictive procedures have evolved and become more refined. Consequences of this evolution are the fact that vertical gastroplasty is no longer used, adjustable gastric banding has improved and vertical gastrectomy has appeared on the scene. The latter has become a well-known technique over the last years, and, together with the band, has become the gold standard restrictive surgical technique.<sup>2</sup>

Vertical gastrectomy is a simple technique with few complications and good results as far as weight loss; ideal in the hands of those surgeons with little experience in advanced laparoscopic bariatric surgery and who want to start in this field. Statistics have shown that it is not a simple morbidity and/or mortality-free technique, and that it can also give rise to much feared and specific complications such as fistula of the gastroesophageal junction.<sup>3,4</sup>

As mentioned above, bariatric surgery is constantly evolving, and in this sense, with the aim of preventing fistulas in vertical gastrectomy different techniques have been applied, from minor technical modifications such as oversutures or the use of material to act as reinforcement,<sup>5,6</sup> to the application of novel techniques as presented in this study. Laparoscopic gastric plication applies the same mechanism of restriction at gastric level, but without any gastric section. It is simply the plication of the gastric wall to reduce gastric lumen.

We present a description of the technique and initial results in the first patients in which we applied it.

## Material and Method

Patients operated between November 2009 and May 2010. We began performing laparoscopic gastric plication as part

of a preliminary study to evaluate this new procedure. All patients were studied according to the multidisciplinary protocol of our centre and signed an informed consent for this technique. They had indications for vertical gastrectomy as a single surgery or a duodenal switch in 1 or 2 procedures.

After general anaesthesia and patient monitoring, patients are placed in the French position with the surgeon between the legs and assistants on both sides. A pneumoperitoneum is performed and 5 trocars are placed, located according to the attached image. First, dissection of the greater omentum at its insertion on the greater curvature is performed with diathermy instruments. The dissection begins at 3 cm from the pylorus and reaches the gastroesophageal junction. All adhesions on the posterior side of the stomach are dissected. Subsequently, a Foucher or Savary orogastric probe is placed to serve as a guide and plication is begun from the cardia to the pylorus. Plication consists in invagination of the greater gastric curve into the intragastric probe, fixated with a line of separate nonabsorbable braided sutures. Plication starts 1-2 cm from the gastroesophageal junction and up to 4-5 cm from the pylorus. After completing the full line of stitches, one or two reinforcing sutures with nonabsorbable monofilament are put in place with the purpose of strengthening the plication and preventing herniation between the stitches. Surgery ends with transoral probe removal and placement of a low pressure suction drain next to the plication.

The same perioperative protocol used for patients undergoing vertical gastrectomy was used with these patients. According to protocol, large hiatal hernias or hernias with marked symptoms are criteria for exclusion for vertical gastrectomy and duodenal switch; and, in consequence, for this surgery. In cases with small hernias, these are reduced before plasty. Postoperative diet and outpatient controls are the same as those performed on all other patients in the Unit.

This paper describes the preoperative characteristics of the patients operated, postoperative outcomes and follow-up in outpatient visits.

## Results

The first patient was operated on in November 2009 and up to this December we have operated a total of 13 patients. In 1 case

a laparoscopic gastric plication was performed in the context of a restrictive duodenal switch. The preoperative characteristics of patients operated on are described in Table 1.

During the immediate postoperative period all patients had symptoms of nausea, vomiting and sialorrhoea in varying degrees, as specified in Table 2. In more severe cases it was necessary to perform an upper gastrointestinal endoscopy to relocate the invaginated gastric folds and facilitate passage. In 2 cases re-operation was necessary, one for intractable vomiting due to herniation of the edges (Figure 1) and another for total dysphagia (Figure 2). Table 2 shows postoperative morbidity and clinical outcome. There has been no mortality. Hospital stay was longer than with the other techniques usually applied in the Bariatric Surgery Unit. The median admittance for gastric bypass and vertical gastrectomy was 4 days, whereas for duodenal switch it was 5 days. Laparoscopic gastric plication patients had a median hospital stay of 5 days.

Body-weight evolution of these patients is almost equal to that observed in patients that have undergone vertical

gastrectomy (Figure 3). In the follow-up visits we observed that persistent vomiting, nausea and food intolerance improved gradually, and resolved after one month of follow-up.

## Discussion

Laparoscopic gastric plication, although only a technical variation of vertical gastrectomy, is still a novel surgery, a new surgical procedure.<sup>7</sup> As such, it is necessary to define its indications, perioperative management and technical aspects. Moreover, with other series it will be necessary to validate the technique and evaluate whether it meets IFSO criteria.<sup>8,9</sup> This is the main objective of this study, to carry out a preliminary description of the technique and the first cases in which it was applied, to be able to design controlled prospective studies that may better establish the indications for this procedure within the armamentarium of bariatric surgery.

When evaluating its place within the bariatric surgery arsenal, its indications are expected to be equivalent to

**Table 1 – Demographics of Patients.**

Patient	Date SI	Sex	Age, Years	Maximum BMI, kg/m <sup>2</sup>	Comorbidities
1	Nov 09	Female	35	42.71	H. hiatus, hypothyroidism
2	Nov 09	Male	34	44.21	H. hiatus, OSAHS
3	Nov 09	Female	47	46.33	Hypothyroidism
4	Feb 10	Female	35	50.21	H. hiatus, Wegener's granulomatosis
5	Feb 10	Female	59	51.22	AHT, DLP, H. hiatus
6	Mar 10	Male	35	43.15	
7	Mar 10	Male	53	41.11	H. hiatus, OSAHS
8	May 10	Female	36	42.29	Pacemaker
9	Jun 10	Male	31	48.33	
10	Sep 10	Female	33	42.68	DLP
11	Oct 10	Female	38	37.11	OSAHS
12	Nov 10	Male	44	43.22	
13	Nov 10	Male	40	45.55	DLP, OSAHS

BMI indicates body mass index; OSAHS, obstructive sleep apnoea-hypopnea syndrome.

**Table 2 – Surgery and morbidity.**

Patient	Surgery	Guide Probe	Postoperat. Vomiting	No. of Endosc.	Re-Operatio: Cause and Surgery	Readmission	Hospital Stay, Days
1	LGP	36F	++	1	No	No	7
2	LGP	36F	++++	0	Yes. Total dysphagia, technical reversion	No	6
3	LGP	36F	++	1	No	No	7
4	LGP	36F	+	0	No	No	3
5	LGP+DS	48F	+	0	No	No	5
6	LGP	48F	++	1	Yes. Herniation between sutures, sleeve	Yes	21
7	LGP	48F	+	0	No	No	3
8	LGP	36F	++	0	No	No	5
9	LGP	48F	++	0	No	No	5
10	LGP	48F	+++	1	No	No	4
11	LGP	48F	+	0	No	No	4
12	LGP	48F	+	0	No	No	4
13	LGP	48F	+	0	No	No	4

Rating Scale of postoperative vomiting every 24 hours: + indicates low / null; ++, present at least every 12 hours; +++, present every 6 hours; +++++, present at all times.

DS indicates duodenal switch; LGP, Laparoscopic gastric plication.

**Figure 1 – Abdominal CT scan showing herniation between sutures. White arrows show the segment of herniated stomach and the black arrows the plicated section.**

those of vertical gastrectomy, although the indications for vertical gastrectomy are still not wholly agreed upon nor clearly defined. This intervention can also be used as part of a duodenal switch, either in one or two procedures.

In our series the weight loss results were equivalent to those observed in other centres<sup>3,10</sup> and those we ourselves have seen previously. The series published by Talebpour,<sup>11</sup> Sales<sup>12</sup> and Ramos<sup>7</sup> and the papers presented by Schauer confirm that it is an intervention that may be equivalent to a sleeve gastrectomy, with equivalent results at 2 years for weight loss and better than those seen with adjustable gastric banding. Therefore the indications for this surgery could be the same.

Compared with this technique, laparoscopic gastric plication has some advantages such as no need for gastric section

and complete reversibility. Avoiding gastric section not only saves money on mechanical sutures, but also reduces the risk of the dreaded fistulas of the gastroesophageal junction. Comparing this procedure with vertical gastrectomy it is necessary to note that it is not yet possible to predict the behaviour of ghrelin changes, metabolic effects, or gastric emptying, reported in this type of surgery. So far, it has only been possible to demonstrate that it is an equivalent technique in terms of weight loss.

The reversibility of the technique is another aspect to consider in case of surgery related morbidity. One of the IFSO criteria to define an ideal surgery IFSO is reversibility.<sup>8</sup> This has been demonstrated in one case in our series as described above.

An essential characteristic of any new surgical technique must be reproducibility. A priori, the greatest technical requirement of this intervention is the ability to perform manual laparoscopic suturing. The supposed simplicity of laparoscopic vertical gastrectomy is also expected of this surgery. On the other hand, as it is a technique in which gastric section is not performed, it is less invasive than vertical gastrectomy, either through mini-ports, a single port or by means of fully robotic surgery.

There have been several experimental studies on how to perform this operation.<sup>13</sup> The point of disagreement seems to be the anatomical site for plication. Animal studies demonstrate the superiority of greater curvature plication compared to anterior gastric wall plication.<sup>14</sup> This has also been proven in controlled studies in humans as that performed at the Cleveland Clinic in Ohio (USA) by Dr. Schauer et al, whose results were presented at the last congress of the *American Society of Metabolic and Bariatric Surgery*.

Regarding the surgical technique, there are still several outstanding issues to define. One of the most important is the size of the probe used as a guide for the plication. Following our series, no correlation can be established to explain that the larger the probe, the less weight loss or less vomiting. The

**Figure 2 – Gastroesophageal tract in which transesophageal herniation causing total dysphagia can be seen.**

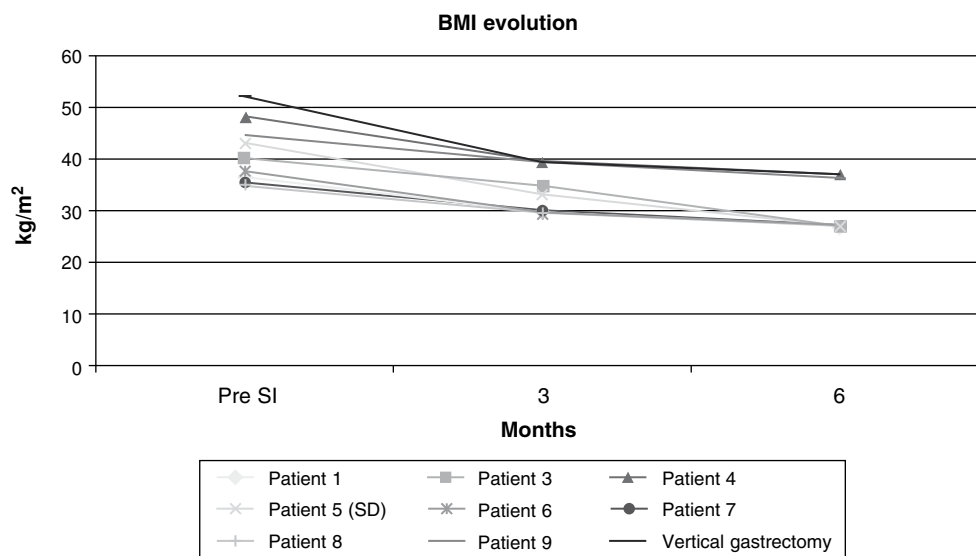


Figure 3 – Evolution of BMI of patients operated on and those in our vertical gastrectomy series.

other published or presented series do not agree either. One of the measures that we believe may be more appropriate is to use an endoscope for calibration, so that before the end of the intervention a fibrogastroscopy can be performed *in situ* to check the status of the plication.

Other issues to discuss, perhaps really side issues, are the starting points of the plication, the number of suture lines to perform, or the need for drainage. In this sense, this technique can be altered or even enhanced by using new semi-mechanical suture instruments.

The morbidity of our series has been considerable, mainly because of the learning curve. In addition to two re-operations, the most important morbidities are nausea and vomiting in the first weeks. The longer series stress that this is the most frequent complication.<sup>7,11,12</sup> Despite this, it is not an impediment to early discharge and it is usually well tolerated.

The most serious morbidity we experienced was herniation of the suture line, and also total dysphagia that required re-operation. In both cases, the main symptom was intractable vomiting. These complications were not described in any previous series. As in other serious complications after bariatric surgery, intensive and early treatment is essential.

In summary, laparoscopic gastric plication is a new surgical procedure with weight-loss results similar to those obtained with vertical gastrectomy, according to our results and the published series. It has the great advantage over vertical gastrectomy as there is no gastric section. Is still necessary to define technical aspects such as the guide probe or whether or not to reinforce the suture line. Morbidity results should improve in our series as the learning curve progresses. The results in terms of weight-loss follow the patterns described in other series in the literature.

## Conflict of Interest

The authors affirm that they have no conflict of interest.

## REFERENCES

1. Buchwald H. The future of bariatric surgery. *Obes Surg.* 2005;15:598-605.
2. Buchwald H, Oien DM. Metabolic/bariatric surgery worldwide 2008. *Obes Surg.* 2009;19:1605-11.
3. Updated position statement on sleeve gastrectomy as a bariatric procedure. *Surg Obes Relat Dis.* 2010;6(1):1-5.
4. Buchwald H. Introduction and current status of bariatric procedures. *Surg Obes Relat Dis.* 2008;4(3 Suppl):S1-6.
5. Kasalicky M, Michalsky D, Housova J, Haluzik M, Housa D, Haluzikova D, et al. Laparoscopic sleeve gastrectomy without an over-sewing of the staple line. *Obes Surg.* 2008;18:1257-62.
6. Dapri G, Cadiere GB, Himpens J. Reinforcing the staple line during laparoscopic sleeve gastrectomy: prospective randomized clinical study comparing three different techniques. *Obes Surg.* 2010;20:462-7.
7. Ramos A, Galvao Neto M, Galvao M, Evangelista LF, Campos JM, Ferraz A. Laparoscopic greater curvature plication: initial results of an alternative restrictive bariatric procedure. *Obes Surg.* 2010;20:913-8.
8. Fried M, Hainer V, Basdevant A, Buchwald H, Deitel M, Finer N, et al. Interdisciplinary European guidelines on surgery of severe obesity. *Obes Facts.* 2008;1:52-9.
9. Melissas J. IFSO guidelines for safety, quality, and excellence in bariatric surgery. *Obes Surg.* 2008;18:497-500.
10. Sánchez-Santos R, Masdevall C, Baltasar A, Martínez-Blázquez C, García Ruiz de Gordejuela A, Ponsi E, et al. Short-

- 
- and mid-term outcomes of sleeve gastrectomy for morbid obesity: the experience of the Spanish National Registry. *Obes Surg.* 2009;19:1203-10.
11. Talebpour M, Amoli BS. Laparoscopic total gastric vertical plication in morbid obesity. *J Laparoendosc Adv Surg Tech A.* 2007;17:793-8.
  12. Sales C. Surset gástrico de Sales: una alternativa para cirugía bariátrica restrictiva. *Rev Colomb Cir.* 2008;23:4.
  13. Fusco PE, Poggetti RS, Younes RN, Fontes B, Birolini D. Evaluation of gastric greater curvature invagination for weight loss in rats. *Obes Surg.* 2006;16:172-7.
  14. Fusco PE, Poggetti RS, Younes RN, Fontes B, Birolini D. Comparison of anterior gastric wall and greater gastric curvature invaginations for weight loss in rats. *Obes Surg.* 2007;17:1340-5.